

DOI: 10.21767/2471-8157.100024

Very Late Stent Thrombosis Associated With Stent Fracture and Antiplatelet Treatment Discontinuation

Alfonso Jurado-Román*, Ignacio Sánchez-Pérez, María T López-Lluva, Jesús Piqueras-Flores and Fernando Lozano-Ruiz-Poveda

Interventional Cardiology Department, University General Hospital of Ciudad Real, Ciudad Real, Spain

Rec Date: July 04, 2016, **Acc Date:** July 18, 2016, **Pub Date:** July 20, 2016

***Corresponding author:** Alfonso Jurado-Román, University General Hospital of Ciudad Real, Avenida Obispo Rafael Torija 13005, Ciudad Real, Spain, Tel:0034629871863; E-mail: alfonsojuradoroman@gmail.com

Citation: Jurado-Román A, Sánchez-Pérez I, López-Lluva MT, et al. Very Late Stent Thrombosis Associated With Stent Fracture and Antiplatelet Treatment Discontinuation. *Interv Cardiol.* 2016, 2:2.

Abstract

Stent fractures are a rare finding that have been associated with stent thrombosis and restenosis. The majority of descriptions affect to first generation drug eluting stents. Angiographic diagnosis is difficult and should be suspected in patients with risk factors when an angiographic separation of struts is visualized. Intracoronary imaging techniques are very useful and can confirm the diagnosis. We present a case of very late zotarolimus eluting stent thrombosis probably favoured by stent fracture and discontinuation of prasugrel.

Keywords: Stent fractures; Angiographic diagnosis; Zotarolimus; Thrombosis; Intracoronary imaging techniques

Introduction

74 years-old patient with diabetes suffered an acute coronary syndrome (ACS) on 2011. Coronary angiography (CA) showed a diffusely diseased right coronary artery (RCA) (**Figure 1**) (**Figure 1A**) that was treated with four overlapped zotarolimus eluting stents (DES) (**Figure 1B**) with good final

result (video 1). On July 2014, he presented a severe in-stent restenosis at mid RCA (**Figure 1C**) that was treated successfully with a drug-eluting balloon (**Figure 1D**). Aspirin and prasugrel were prescribed for one year. On April 2015, he suffered a new ACS after stopping prasugrel 48 hours before. CA showed a thrombotic in-stent occlusion at mid RCA (**Figure 1E** and **1F**) and a discontinuation of the stent struts at proximal segment (**Figure 1G**; arrow). As no GAP without stent was left at this point during previous interventions, stent fracture was suspected. Optical coherence tomography confirmed the diagnosis showing absence of struts in a great arch of the circumference at this point (**Figure 1H**) that were visible in almost all the circumference at contiguous frames (**Figure 1I**; asterisks). Another drug eluting stent (DES) was implanted at this segment, aspirin and prasugrel were reintroduced for 1 year and the patient remains asymptomatic 15 months later.

Stent fractures are a rare finding, usually described in first generation DES1, that have been associated with stent thrombosis and restenosis. Angiographic diagnosis is difficult and it should be suspected in patients with risk factors 1 (RCA, long or overlapped stents, hinge movement segments and vessel angulation and calcification) when an angiographic separation of struts is visualized. Intracoronary imaging techniques can confirm the diagnosis observing an absence of struts in one or more coronary segments.

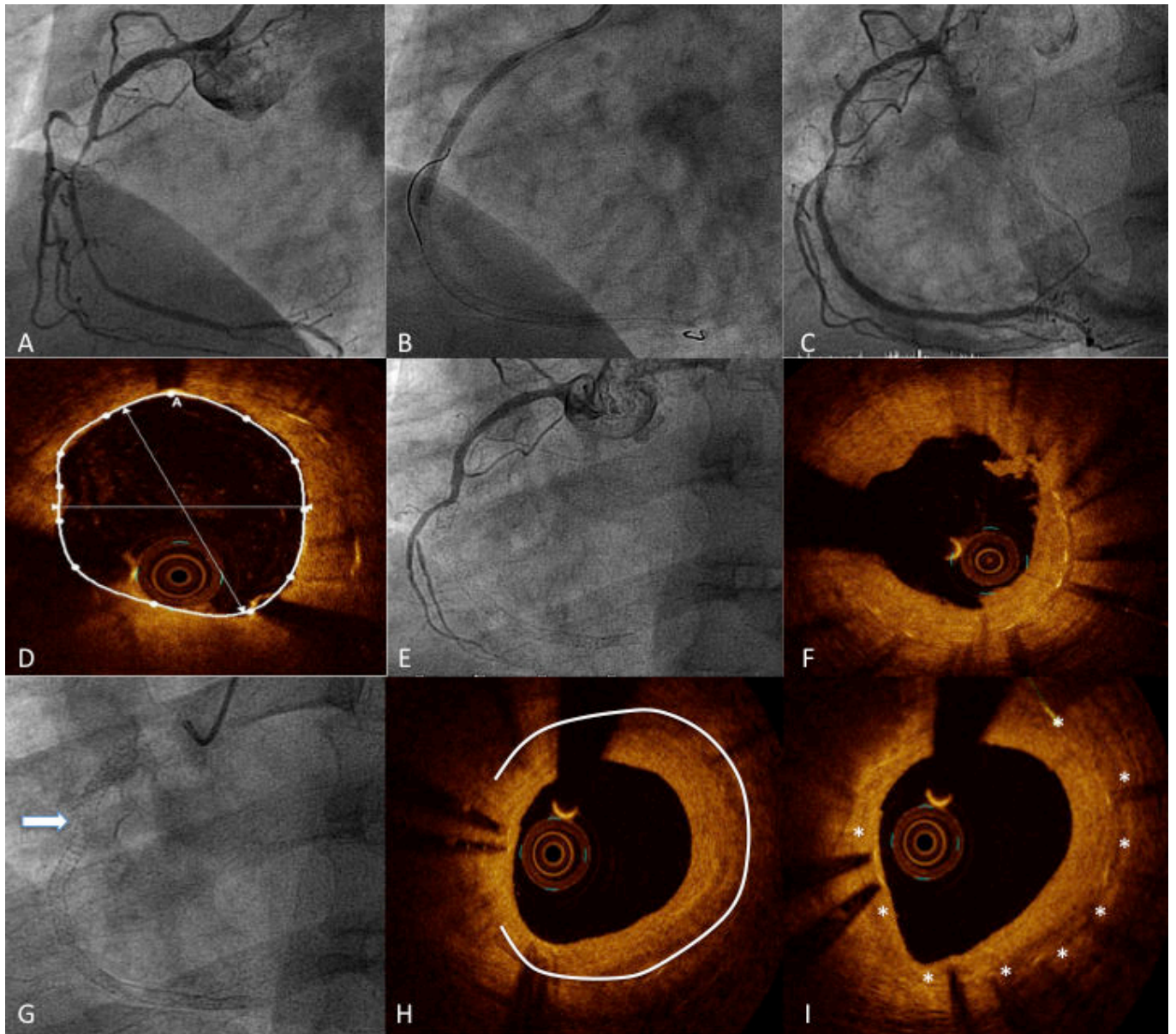


Figure 1 Coronary angiography (CA).

References

1. Hernández FH, Román AJ, Tejada JG, Martín MV, González-Trevilla AA, et al. (2013) Intravascular Diagnosis of Stent Fractures: Beyond X-ray Imaging. *Rev Esp Cardiol* 66: 744-754.