

Urachal Cancer in Pregnancy: A Case Report and Review of Literature

Genel H¹, Hubinont C², Baldin P³, Amant F⁴⁻⁶ and Mhallem M^{1*}

Abstract

We report a case of an urachal cancer during pregnancy. The patient was referred at 38 weeks pregnancy for suspicion of placenta accreta spectrum (PAS). The only symptom was a macroscopic hematuria during the third trimester. Obstetrical ultrasound in tertiary center suggested a bladder tumor. A polyp was observed at the vesical dome during the cystoscopy. After the delivery and computed tomography, the patient underwent a tumor resection with high suspicion of urachal cancer. A radical cystectomy and enteroplasty were performed. The pathological findings confirmed the urachal origin of the lesion.

Keywords: Urachal cancer; Ultrasound; Pregnancy

Received: April 16, 2020; **Accepted:** June 01, 2020; **Published:** June 05, 2020

Introduction

Urachal cancer is a form of cancer that arises in a structure called the urachus. The urachus is a canal that exists when the fetus is developing before birth. This canal runs from the bladder of the fetus to the belly button (umbilicus). It drains the urinary bladder of the fetus. Between the fourth and fifth month of pregnancy, this canal breaks down (degenerates) into a fibrous band of tissue called a ligament. A urachal cyst is a collection of tissue and fluid between the bladder and the belly button (umbilicus). The cyst forms in the remnants of the urachus, a structure normally present in a fetus that usually closes up before birth. In some infants, the closure doesn't occur. If this happens, a urachal abnormality (such as a cyst or sinus) remains. Urachal cancer will often extend into surrounding structures like the bladder, and can potentially spread (metastasize) to other areas of the body. The exact, underlying cause of urachal cancer is not fully understood. Surgery is the most common treatment option.

Case Report

A 42-year-old, gravida 3 para 2, pregnant patient was referred at 38 weeks' gestational age to our tertiary center for suspicion of abnormal insertion of the placenta (PAS).

The previous medical history is marked by a vesico-ureteral reflux surgery at age of 9 years. The patient is an active smoker and episodic cannabis user. The family history is marked by several cancers. Her mother recently died of pancreatic cancer, her father had a bladder cancer and her brother had a lung cancer. In 2006, the patient delivered vaginally at 38 weeks. In 2011, a

caesarean was performed for a breech position baby. As it was an unplanned pregnancy, she had no medical follow-up until the last trimester.

The patient was referred at 38 weeks for suspicion of placenta accreta spectrum (PAS). She presented a macroscopic haematuria associated with a urinary tract infection treated by antibiotics. The obstetrical ultrasound showed at the level of the cesarean scar a mass bulging inside the bladder.

We carried out a fetal monitoring showing a normal rhythm. There was no significant uterine activity. The urinary test t

- 1 Department of Obstetrics, Cliniques Universitaires, Saint-Luc, Belgium
- 2 Department of Urology, Cliniques Universitaires, Saint-Luc, Belgium
- 3 Departement of Pathology, Cliniques Universitaires, Saint-Luc, Belgium
- 4 Department of Oncology, Kuleuven, Belgium
- 5 Center for Gynecological Oncology Amsterdam (CGOA), Anton Van Leeuwenhoek Cancer Institute, The Netherlands
- 6 Center for Gynecological Oncology Amsterdam (CGOA), Amsterdam University, Medical Centers, The Netherlands

*Corresponding author: Mhallem M

✉ mina.mhallem@uclouvain.be

Department of Obstetrics, Cliniques Universitaires Saint-Luc, Belgium.

Tel: 0032472394326

Citation: Genel H, Hubinont C, Baldin P, Amant F, Mhallem M (2020) Urachal Cancer in Pregnancy: A Case Report and Review of Literature. *Gynecol Obstet Case Rep* Vol.6 No.2:17

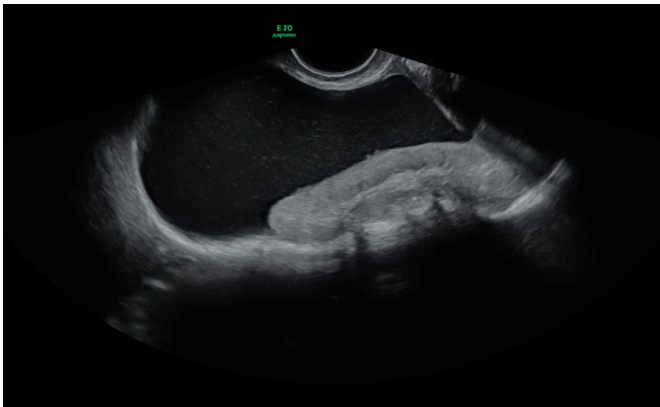


Figure 1 Gray-scale ultrasound, suspicion bladder tumor.

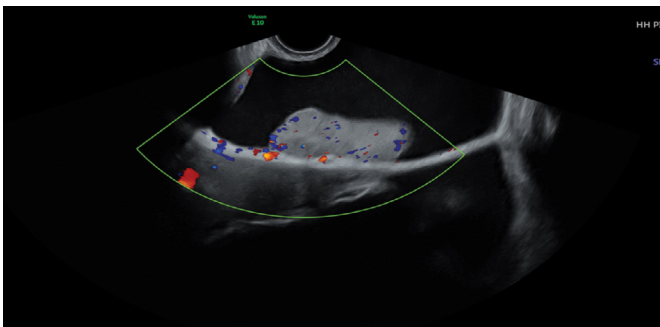


Figure 2 Color Doppler Ultrasound reveals minimal blood flow.

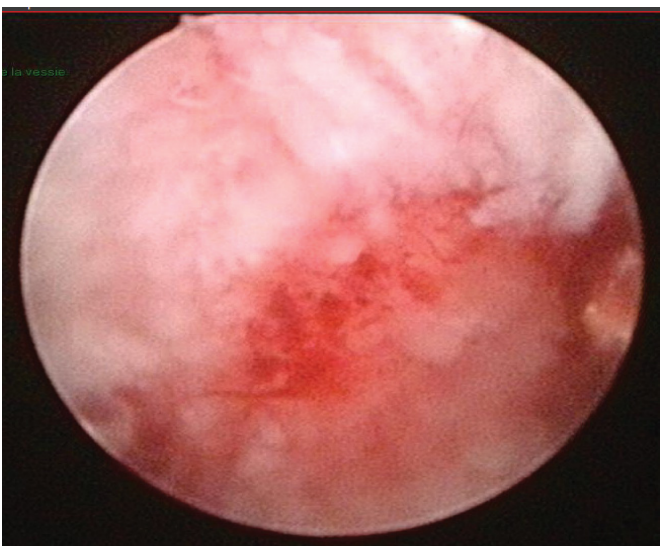


Figure 3 Cystoscopy reveals irregular papillar lesion.

marginal type II. The placenta-bladder interface was well visualized. We did not find bridging vessels in the myometrium. No other signs of PAS such as placenta lacuna were observed [1]. Ultrasonographically, a 9 cm mass in the bladder not connected with the placenta was observed (**Figures 1 and 2**). A cystoscopy revealed a suspicious mass developed on the anterior wall and the dome of the bladder (**Figure 3**). No malignant cells were found in the urine cytology. A magnetic resonance imaging (MRI) was impossible due to claustrophobia.

Vaginal examination showed a closed cervix with a mass palpable in the retropubic wall. Because an underdetermined large mass behind the anterior wall of the vagina we choose to perform a caesarean section. The patient delivered of a baby girl 2970 grams with an Apgar score of 8 at 5 minutes and 9 at 10 minutes. The cesarean section was uncomplicated. The placenta delivery was uneventful and no sign of placenta accreta spectrum was noted. The bladder digital exam confirmed the presence of a hard intra-vesical mass. The posterior wall of the bladder was normal. The pathological analysis of the placenta confirmed the absence of PAS (**Figure 4**).

The postpartum computed tomography showed a neoplastic thickening on the antero-superior side of the bladder in continuity with the urachus (**Figure 5**). The first hypothesis was an urachal tumor without expansion.

A transurethral resection of bladder tumor (TURBT) was performed 3 weeks after the cesarean. The operation was

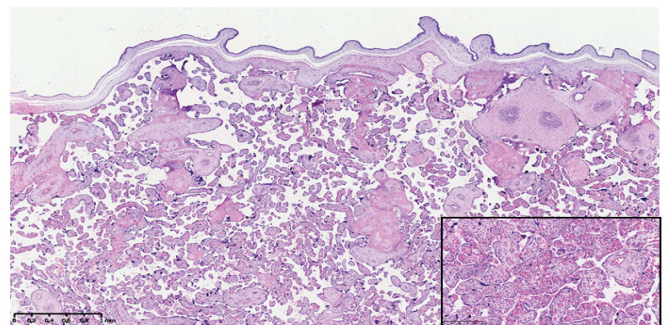


Figure 4 Placental specimens showed a normal villous maturation without pathological features. Focally chorangiosis was present (insert).

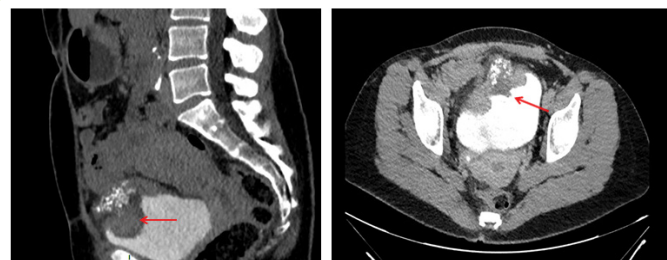


Figure 5 Postpartum computed tomography reveals a 8-9 cm tumor located between the urachal ligament and the bladder dome.

returned positive and the culture showed an E. coli infection resistant to ampicillin for which cefuroxime was prescribed.

Obstetrical level III ultrasound showed a cephalic foetus with normal growth around the 50 percentile. The amniotic fluid index was normal with an index of 15. The placenta was anterior,

incomplete. The samples from trans-urethral resection were submitted for pathological evaluation. The fragments were infiltrated by a neoplastic malignant proliferation composed of glandular structures and signet-ring cells surrounded by mucin. These cells infiltrated the detrusor muscle. Neoplastic cells were diffusely positively stained for CK20, focally for STATB2 and negatives for the following stainings: GATA3, PAX8, beta-catenine, Cytokeratin 7, estrogen receptors and progesteron receptors. The diagnosis of mucinous carcinoma with signet ring differentiation (most) likely of urachal origin was made.

Considering the young age of the patient, the partial and the radical cystectomy were discussed. The patient preferred a radical treatment. A radical cystectomy followed by enteroplasty and lymphadenectomy was performed to complete the surgery. The pathological findings confirmed the urachal origin of lesion (Figure 6). Lymph node analysis was negative.

Discussion

Cancer diagnosis during pregnancy is very rare condition but is increasing over the years [2,3]. The most frequently encountered cancers are breast and haematological cancers [4-6]. The incidence for bladder cancer during pregnancy is estimated to 1.4 to 2.5% of all cancers during pregnancy [7]. The urachal cancer represents 0.5% of all vesical cancers. The physiopathology of this cancer is poorly understood but is developed from a remnant structure, the urachus, connecting the embryological allantois and the dome of the bladder existing during the fetal life. It is mostly aggressive and discovered at advanced stages [8].

Only some cases reports of urachal cancers during pregnancy are described in the literature. Investigations are recommended in order to distinguish this tumor from a leiomyoma, endometriosis or urachal diverticulum and from other types of bladder cancers [9-15]. Frequent clinical signs are microscopic or macroscopic

hematuria, recurrent urinary tract infections, dysuria, post-coital bleeding and abdominal or back pain. These complaints are frequent in normal pregnant patients and then can delay the cancer diagnosis.

Abdominal ultrasound, cystoscopy and magnetic resonance imaging are indicated for suspicious masses. These investigations could be performed during the pregnancy in order to avoid diagnostic delay and improve the prognosis.

The main predictor factor is the TNM classification initially described by Sheldon and adapted by Molina in 2007-8 [16]. Multidisciplinary management is necessary to optimize the maternal prognosis. For not pregnant patients, surgery, chemotherapy and radiotherapy are proposed depending on the tumor stage. Partial and/or radical cystectomy, umbilicotomy and urachal resection are indicated for stage I and II stage with good survival. Systemic therapy and irradiation are proposed for advanced stages with bad prognosis [8]. Chemotherapies as fluoropyrimidine, taxane, cisplatin and gemcitabine are mostly proposed to treat metastatic cancers [17]. Hyperthermic intraperitoneal chemotherapy associated to cytoreductive surgery is also described for metastatic lesion of urachal cancers [18]. Systemic therapy with monoclonal antibodies directed to epidermal growth factor receptors may be used to treat urachal cancers [19].

Urachal treatments during pregnancy are already described as surgery and chemotherapy. During the first trimester of pregnancy, termination of pregnancy is discussed with the parents and can be indicated when the prognosis is poor. Surgery can be performed during the three trimesters. The urachal cancer has a high recurrence rate and particularly in case of positive lymph nodes and surgical margins. Chemotherapy may be proposed during the second and third trimester of pregnancy. Intraperitoneal therapy and systemic treatment are not authorized during pregnancy.

Conclusion

In conclusion, multidisciplinary management is highly recommended in case of suspicious bladder cancer during pregnancy. Cystoscopy, abdominal ultrasound and magnetic resonance imaging are useful tools for evaluation of the tumor during pregnancy. The treatment is adapted to each case given the paucity of case reports published in the literature. Participation in international registration as International Network of Cancer, Infertility and Pregnancy (INICIP) is needed to collect more data to draw conclusions and to standardize the pregnant patient management.

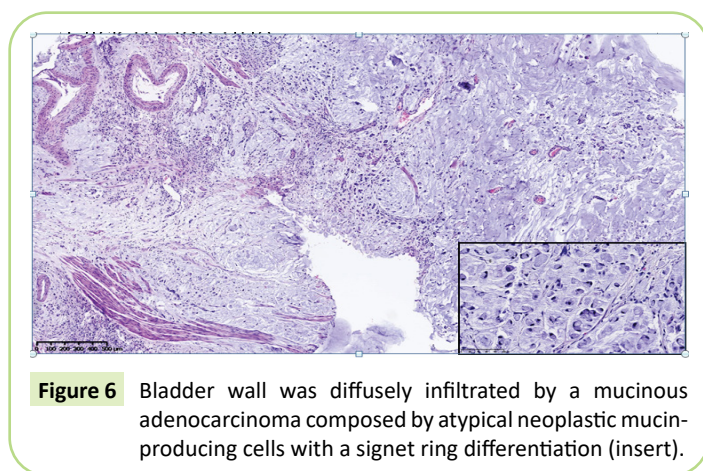


Figure 6 Bladder wall was diffusely infiltrated by a mucinous adenocarcinoma composed by atypical neoplastic mucin-producing cells with a signet ring differentiation (insert).

References

- 1 Jauniaux E, Collins SL, Jurkovic D, Burton GJ (2016) Accreta placentation: A systematic review of prenatal ultrasound imaging and grading of villous invasiveness. *Am J Obstet Gynecol* 215 (6): 712-721.
- 2 Gziri MM, Goffin F, Debieve F, Amant F (2013) Cancer diagnosis during pregnancy: importance of a national and European registration. *Rev Med Liege* 68 (10): 527-530.
- 3 Maggen C, Van GM, Van CK, Vandenbroucke T, Amant F (2019) Management of cancer during pregnancy and current evidence of

- obstetric, neonatal and pediatric outcome: A review article. *Int J Gynecol Cancer*.
- 4 Amant F, Deckers S, Van CK, Loibl S, Halaska M, et al. (2010) Breast cancer in pregnancy: recommendations of an international consensus meeting. *Eur J Cancer* 46 (18): 3158-3168.
 - 5 Amant F, Han SN, Gziri MM, Vandenbroucke T, Verheecke M, et al. (2015) Management of cancer in pregnancy. *Best Pract Res Clin Obstet Gynaecol*.
 - 6 Aviles A and Neri N (2001) Hematological malignancies and pregnancy: A final report of 84 children who received chemotherapy *in utero*. *Clin Lymphoma* 2 (3): 173-177.
 - 7 Lambrechts S, Van CK, Capoen A, Op de BK, Joniau S, et al. (2011) Polypoid endometriosis of the bladder during pregnancy mimicking urachal carcinoma. *Ultrasound Obstet Gynecol* 38 (4): 475-478.
 - 8 Molina JR, Quevedo JF, Furth AF, Richardson RL, Zincke H, et al. (2007) Predictors of survival from urachal cancer: a Mayo Clinic study of 49 cases. *Cancer* 110 (11): 2434-2440.
 - 9 Goldman H, Sowter S (2016) Urachal adenocarcinoma incidentally discovered in a young woman at elective caesarean section. *BMJ Case Rep* 2016.
 - 10 Church E, Dieh A (2013) A rare case of aggressive squamous cell carcinoma of the bladder in pregnancy. *Obstet Med* 6 (4): 182-183.
 - 11 McNally L, Osmundson S, Barth R, Chueh J (2013) Urachal duct carcinoma complicating pregnancy. *Obstet Gynecol* 122 (2 Pt 2): 469-472.
 - 12 Yeaton-Massey A, Brookfield KF, Aziz N, Mrazek-Pugh B, Chueh J (2013) Maternal bladder cancer diagnosed at routine first-trimester obstetric ultrasound examination. *Obstet Gynecol* 122 (2): 464-467.
 - 13 Lakmichi MA, Zehraoui R, Dahami Z, Moudouni SM, Bassir A, et al. (2012) Bladder cancer in the second trimester of pregnancy: tough decisions. A case report with review of the literature. *Ther Adv Urol* 4 (3): 139-142.
 - 14 Khochikar MV (2010) Management of urological cancers during pregnancy. *Nat Rev Urol* 7 (4): 195-205.
 - 15 Van CK, Van MK, Joniau S, Oyen R, Hanssens M, et al. (2006) Urachal carcinoma during pregnancy. *Urology* 67 (6): 1290-21.
 - 16 Sheldon CA, Clayman RV, Gonzalez R, Williams RD, Fraley EE (1984) Malignant urachal lesions. *J Urol* 131 (1): 1-8.
 - 17 Jung HA, Sun JM, Park SH, Kwon GY, Lim HY (2014) Treatment Outcome and Relevance of Palliative Chemotherapy in Urachal Cancer. *Chemotherapy* 60 (2): 73-80.
 - 18 Mertens LS, Behrendt MA, Mehta AM, Stokkel L, De JJ, et al. (2019) Long-term survival after cytoreductive surgery and hyperthermic intraperitoneal chemotherapy (HIPEC) for patients with peritoneal metastases of urachal cancer. *Eur J Surg Oncol* 45 (9): 1740-1744.
 - 19 Collazo-Lorduy A, Castillo-Martin M, Wang L, Patel V, Iyer G, et al. (2016) Urachal carcinoma shares genomic alterations with colorectal carcinoma and may respond to epidermal growth factor inhibition. *Eur Urol* 70 (5): 771-775.