

DOI: 10.21767/2471-8157.100020

Trans-Catheter Pulmonary Valve Implantation: Procedure, Limitations and Future Directions

Reinthal M^{1,2,3,4,*}, Braune S^{1,2,4}, Curio J³, Fröhlich G^{3,4}, Jung F^{1,2,4} and Landmesser U^{1,3,4}¹Institute of Biomaterial Science, Berlin-Brandenburg Centre for Regenerative Therapies (BCRT), Germany²Helmholtz Institution, Kantstrasse 55, Teltow, Germany³Department for Cardiology, Charité Universitätsmedizin Berlin, Campus Benjamin Franklin; Berlin Institute of Health, Deutsches Zentrum für Herz-Kreislaufforschung, Berlin, Germany⁴Joint Laboratory, Kantstrasse 55, Teltow, Germany***Corresponding author:** Markus Reinthal, Charité Universitätsmedizin Berlin, Campus Benjamin Franklin, Department for Cardiology, Hindenburgdamm 30, 12200 Berlin, Tel: +49 30 450539418, E-mail: markus.reinthal@gmx.at**Rec Date:** Apr 21, 2015, **Acc Date:** May 24, 2016, **Pub Date:** May 26, 2016**Citation:** Reinthal M, Braune S, Curio J, Fröhlich G, Jung F, et al. Trans-Catheter Pulmonary Valve Implantation: Procedure, Limitations and Future Directions. *Interv Cardiol J* 2016, 2:2.

Abstract

Trans-catheter pulmonary valve implantation (TPVI) has become the treatment of choice in most congenital heart disease patients with degeneration of a previous right ventricular outflow tract (RVOT) repair. Since the life expectancy of this patient cohort is improving, there is an increased demand of these procedures. Efficacy and safety have been demonstrated for the Medtronic Melody and the Edwards Sapien valves, although there is still a paucity of data and no consistent procedural recommendations are available.

Keywords: Trans-catheter pulmonary valve; Patch repaired RVOT; Joint laboratory

many authors [1,2]. In terms of feasibility for TPVI there has been a change during the past years. Initially, TPVI was advocated only for previously operated patients with surgical conduits.

The larger diameter of the SAPIEN valves and the use of pre-stenting, nowadays allow treating many more types of outflow tracts, whether there has been a conduit, a trans-annular patch, a surgical valve or a native pulmonary valve [3].

Medtronic Melody Valve

The Medtronic Melody valve is a balloon-expandable valve, which is available in two sizes; 16 mm and 18 mm. The Device is made of a bovine jugular vein valve (Contegra pulmonary valved Conduit, Medtronic Inc., Minneapolis, MN, USA), sutured within a Cheatham Platinum stent (CP stent, NuMED Inc., Hopkinton, NY). The CP stent has a closed cell design.

Three different dedicated balloon in balloon delivery catheters (Ensemble Trans-catheter Delivery System, 22F)-available in 18, 20 and 22 mm outer balloon size-allow precise deployment according to RVOT diameters (**Figure 1**).

Introduction

The indications for treatment of pulmonary valve stenosis and incompetence are based on published guidelines (**Tables 1 and 2**) and reflected in the treatment indications used by

Table 1: Treatment indications for pulmonary valve stenosis

Treatment indication in asymptomatic patients with normal RV function when:
- Systolic gradient > 50 mmHg (infants < 5 years)
- Systolic gradient > 40 mmHg (infants > 6 years)
Special care needs to be taken to the pathology of the pulmonary valve as this may have implications on the type of procedure performed (commissurotomy, separation of fused valve leaflets, "shaving" of thickened leaflets, moderate annuloplasty, resection of infundibular/muscular/subvalvular parts of the stenosis)
Primary treatment is balloon valvuloplasty
Secondary treatment is surgical approach after failure of valvuloplasty or
Trans-catheter pulmonary valve implantation (TPVI)

Recommendations according to the German guidelines of pediatric cardiology [1]

Table 2: Treatment indications for pulmonary valve regurgitation

Regurgitation fraction >30% (measured by MRI), in addition to:
- Clinical symptoms: apparent right heart failure, impaired exercise performance (VO2 max <70%)
- New onset/persistent and symptomatic atrial or ventricular arrhythmia
- Significant or progressive right ventricular dilatation (EDV160, ESV 80 ml/m ²)
- Significant or progressive right ventricular dysfunction (EF <45%)
- New onset significant tricuspid regurgitation with RV dilatation
- QRS >180 ms or increase of QRS >3.5 msec/year
<i>Pulmonary regurgitation is NOT a benign structural cardiac problem. It has major impact on survival and quality of life. Reconstruction or valve replacement is the treatment of choice. Recommendations according to the German guidelines of pediatric cardiology [1]</i>

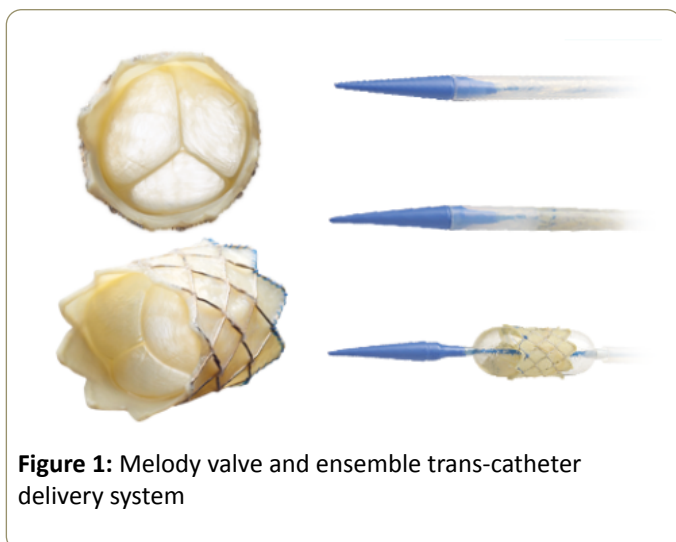


Figure 1: Melody valve and ensemble trans-catheter delivery system

Trans-catheter pulmonary valve replacement with the Melody valve is a safe and effective treatment for patients with post-operative RVOT conduit dysfunction [4]. It has been proven to relieve conduit obstruction, to restore valve function, to delay the next surgical intervention and to significantly improve functional status as well as quality of life [2,4-6]. Most recently, data from the French registry demonstrated a sustained improvement of right ventricular (RV) function [7,8].

Edwards Pulmonic Valve

The Edwards Sapien valve is also a balloon-expandable valve, which is available in a 23 mm and a 26 mm size (covering RVOT dimensions from 21-23 and 23-26 mm). There is also a 29 mm valve available, which is currently not cleared for use in pulmonic position. However, some experience is available with the larger valve, which demonstrated that it may be feasible for RVOT diameters up to 29 mm [8]. The Edwards valve is implanted through the Retroflex delivery system, which consists of a balloon catheter and a deflectable guiding catheter (**Figure 2**).

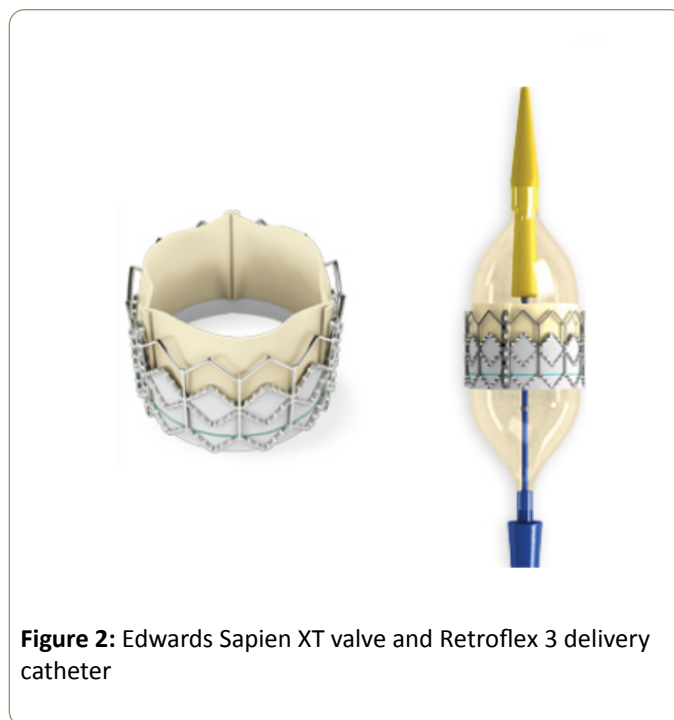


Figure 2: Edwards Sapien XT valve and Retroflex 3 delivery catheter

It requires a 22 Fr introducer sheath for the 23 mm and a 24 F sheath for the 26 mm valve, presuming the valve is crimped on the catheter and loaded on the balloon after passing the introducer sheath. Access from the jugular vein may even require larger sheath sizes, as mounting the valve directly on the balloon may be necessary. However, there is also some experience with the latest Edwards trans-catheter aortic valve implantation (TAVI) technology in pulmonary position, the Sapien III valve, which is implantable through a 14 F e-sheath [9].

Two recent large studies investigated the feasibility and safety of the Sapien valves in pulmonic position. The compassion trial, which is still ongoing, included data from 36 patients with follow up of up to 4 years, showed a procedural success rate of 85% with no mortality after 6 months [10]. These results are confirmed by the most recent Data of the PREMIER Registry, which included 131 patients in 16 centers

and also showed no mortality and a 91% procedural success rate after one year [11]. Both studies confirm good hemodynamic and functional results throughout the follow-up period.

Procedural Considerations

Congenital heart disease patients usually have a history of complex surgical interventions. However, trans-catheter technologies have expanded over the past few years, and nowadays serve as important complementary treatment modalities. Therefore, every type of surgery performed in childhood, should take into consideration possible percutaneous procedures a patient may need to undergo in the future. For example, RVOT morphology is different in patch and conduit repair and may therefore influence the choice of equipment and technique in case of TPVI. Great care needs to be paid to the coronary anatomy, due to the risk of external compression after RVOT stenting. According to previous published data, 5% of patients requiring a percutaneous pulmonary valve were not suitable for this procedure due to an increased risk of coronary artery compression [12].

In general, coronary vessels at risk are detected by simultaneous coronary angiography and inflation of a large non-compliant balloon in the RVOT. The balloon size should be large enough to cause complete abolition of systemic pressure after inflation. This will ensure adequate simulation of the external RVOT and pulmonary artery dimensions after percutaneous repair. Pre-stenting the RVOT with covered or open cell stents is recommended in all patients to improve the landing zone of the trans-catheter valve and to minimize residual gradients [13]. The stent formed "conduit" needs to be circular to enable optimal acute and longterm function of the implanted valve as leaflet coaptation could be impaired by non-circular deployment. A 'down the barrel' view is ideal to visualize the anatomy (**Figure 3**).

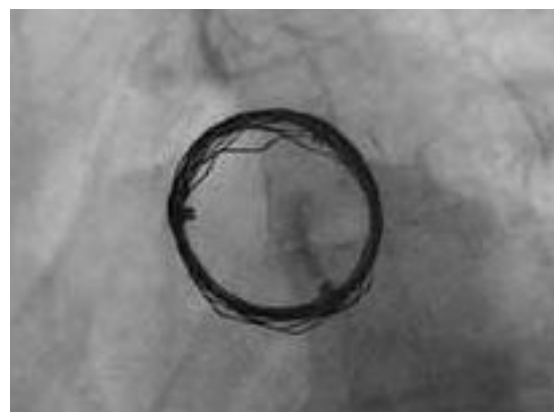

Figure 3: Barrel view showing optimal landing zone

Balloon sizing with low pressure balloons may help to determine the RVOT diameter and subsequent size of stents selected for preparation of the landing zone of the valve. In outflow tracts with severe calcification, high pressure and shear resistant balloons (i.e. Atlas balloons) may be used. Keeping in mind that a normal RVOT in adults usually measures about 25 mm in diameter, the valve size should be chosen accordingly for the first implant in a patient if possible [14,15]. A sub-investigation of the Framingham heart study revealed mean pulmonary artery diameters of 26 ± 2.7 mm in men and 24 ± 2.7 mm in women [15]. Once these steps are completed, the trans-catheter valve can be delivered and deployed, preferably at the position of the native valve. Important attention needs to be paid to the orientation of the valve when mounted on the delivery catheter. An overview of procedural steps, along with the generally used technical equipment is provided in **Table 3**.

Table 3: Procedural steps and equipment.

Procedural steps	Equipment
Accessing pulmonary artery	Standard catheters
Acquiring hemodynamics and angiograms	Standard pigtail or Multitrack catheter (NuMED, Inc.) for good visualization.
Balloon sizing, Pulmonary valve valvuloplasty, exclusion of coronary obstruction	In the presence of pulmonary valve stenosis, stiffer wires (e.g. COOK ultrastiff wire) and medium pressure balloons (e.g. Mullins-X, Z-med, Zmed II - NuMED Inc., VACS III - Osypka GmbH) may be used for dilatation If severe calcification is visible, a predilatation with robust balloons, i.e. Atlas Balloons (BARD) is often necessary In large outflow tracts, moderate pressure balloons are recommended (e.g. PTS, PTS-X sizing balloon - NuMED Inc., Cristal balloon - Abmedica). For balloon interrogation a VACS II (Osypka GmbH) can be used.
RVOT Stenting	Usually straight 14-16 F Check-Flo Performer Introducers and medium pressure balloons for stent deployment are used (e.g. Mullins-X, Z-med, Z-med II-NuMED, Inc., VACS III-Osypka GmbH or BiB balloon) Covered CP-stents (NuMED, Inc.) may reduce blood extravasation; non-covered stents (i.e. CP Stents, Andra stents) are suitable in selected cases. In wide, non-calcified RVOTs, Andra stents (Andramed, Inc.) are preferred by many operators since they may improve the "grip" on the vessel wall. Preparation of a round landing zone for the TPV is important and can be checked in a barrel view (Figure 3)
Valve implantation	23, 26 mm SAPIEN valve (Edwards Lifesciences, LLC) RVOT dimension: 21-26 mm Melody valve (Medtronic, Inc.) RVOT dimension: 16-22 mm.

Complex Anatomies

TPVI implanters often face technically challenging anatomies and limited availability of dedicated technical equipment. These tricky situations include dilated RVOTs and the presence of surgical pulmonic valves.

Annulus diameters of more than 26 mm are most likely discovered in patients with previous trans-annular patch (TAP) repair or in dilated native RVOTs. Patch-repaired pulmonary arteries may be less expandable (dependent on the implanted patch size) and the stent apposition area may be narrow. This is why anatomy after RVOT patch repair is often considered unfavorable for TPVI and is therefore not recommended by current guidelines. However, a recent study showed that this procedure may be feasible with the SAPIEN valves [16]. Furthermore, earlier rather than later TPVI, to prevent severe RVOT dilatation, may be considered in these patients. Dilated RVOT anatomies may result in an increased risk of valve migration in case of immediate valve implantation. Therefore, a staged 'two sessions' procedure (meaning that the valve delivery is postponed for one to two months, until fixation of the implanted stents has taken place) may be an additional option to achieve the best possible results. However, this approach may be inadequate in patients with poor right ventricular function, as free PR is likely to cause rapid hemodynamic deterioration in this cohort. Having the valve prepared for immediate implantation may be the most effective rescue strategy in case of rapid hemodynamic deterioration after RVOT-stenting in these patients.

Most importantly, stent/valve sizing plays a major role in avoiding stent/valve migration. Some operators favor balloon interrogation, using a low pressure compliant balloon. Applying a gentle tug to the inflated balloon may also help to predict stent malapposition. If the stenosis disappears after inflation or in case of balloon dislodgement after the tug, the procedure should be aborted. Procedural data from 10 TPVIs in trans-annular patches showed that good results were achieved by slight oversizing of the balloon used for stent deployment (Outer BiB balloon diameter to RVOT ratio=1.1) [17]. Similar recommendations can be given in terms of valve sizing. The RVOT diameter just above or below the balloon waist should be chosen for valve sizing. For large anatomies (>26 mm RVOT diameter) there is currently only the 29 mm SAPIEN XT (or Sapien III) valve available (not CE marked for this indication). Self-expandable stents may be used for pre-stenting, if the RVOT is larger than the available balloons for stent deployment. As mentioned earlier, a circular RVOT should be prepared to allow full expansion of the implanted heart valve. Post-dilatation of the implanted stents with noncompliant balloons or implantation of a second or even several stents may help to improve the results. Multiple stent implantations may also be considered to downsize the RVOT diameter and allow implantation of the largest available valve. In general, the longest available stents (crimped on a BiB balloon) should be used and placed as proximally as possible to cover the RVOT. However, the use of multiple stents also has serious risks including distortion of the previous stent, damage to the pulmonic artery wall, and compromise of the main

pulmonary branches, which has to be excluded after stent-implantation. A large low pressure balloon may help to define the correct implantation site. Compared to conventional pulmonary angiography, this approach may improve flare and will reduce the amount of contrast used.

Patients with previous bio-prosthetic surgical pulmonary valve replacements also require a different approach. Although the risk of coronary obstruction and annular rupture is lower in some valve types, correct positioning of the transcatheter valve, trans-valvular gradients and pulmonary regurgitation may be a problem in these procedures. Pre-stenting despite the presence of a surgical bio-prosthesis may be considered to improve the landing zone especially when the Melody valve is used, due to its longer Stent frame compared to the Edwards devices. However, this approach may increase the trans-valvular gradient, especially in small stenotic valves. On the other hand, direct valve implantation without pre-stenting may result in significant regurgitation due to lack of leaflet-coaptation, caused by extreme overexpansion of the distal part of the trans-catheter valve, which is not caged in the surgical bio-prosthesis. Extensive oversizing should therefore be avoided, especially in valve-in-valve procedures. In conclusion, the design, size, early post-operative gradients and degree of calcification of the surgical valve, as well as careful valve sizing and positioning are major components to achieve the best possible results.

Future Directions

Requirements for valve substitutes include features such as a lower introducer profile <20 F, low inflammatory response, long durability, low opening resistance with maximal valve area, as well as fast and reliable closure and as for all cardiovascular implants non-thrombogenicity. In addition, the transcatheter valve should be able to compensate for suboptimal geometrical expansion in potentially oval-shaped landing zones. Extensive oversizing is associated with pulmonary regurgitation due to lack of leaflet coaptation, implying that the availability of several valve sizes or even patient specific valves is key to achieve good results. The latest Edwards Sapien technology provides a broader range of sizes (23-26-29 mm), lower profile (16-20 F e-Sheath), a more flexible system and semi-closed resting position leaflet configuration. A disadvantage compared to the Medtronic Melody device is that once the Sapien valve has been introduced into the vessel, it cannot be retrieved, except removing the introducer sheath, until the valve is deployed. Importantly, Stent-fractures, which impacts the durability of the valve, is more likely with the Melody valve. Stent design and the used materials will therefore play a key role in future technologies. Furthermore, structural valve failure is also caused by calcification which is histologically evident within 3 years of valve implantation [18]. Mechanical stresses including mounting the valve on various catheters and distortion of the valve or incomplete valve expansion have been identified as risk factors for early valve failure. The trend to reduce sheath sizes and consequently the reduction of leaflet thickness is also known to impair the durability of percutaneous valves

[18]. Self-healing materials may offer a solution to overcome these limitations in the future [19].

Taken together, current trans-catheter valve technology is moving in the right direction to achieve the best possible outcomes. However, it is only a transient solution so far. Upcoming technologies will offer new features which may further improve the outcome of congenital heart disease patients.

References

1. <http://www.kinderkardiologie.org/leitlinien/>
2. Eicken A, Ewert P, Hager A, Peters B, Fratz S, et al. (2011) Percutaneous pulmonary valve implantation: two-centre experience with more than 100 patients. *Eur Heart J* 32: 1260-1265.
3. Haas NA, Moysich A, Neudorf U, Mortezaeian H, Abdel-Wahab M, et al. (2013) Percutaneous implantation of the Edwards SAPIEN pulmonic valve: initial results in the first 22 patients. *Clin Res Cardiol* 102: 119-128.
4. Zahn EM, Hellenbrand WE, Lock JE, McElhinney DB (2009) Implantation of the melody transcatheter pulmonary valve in patients with a dysfunctional right ventricular outflow tract conduit early results from the U.S. Clinical trial. *J Am Coll Cardiol* 54: 1722-1729.
5. McElhinney DB, Hellenbrand WE, Zahn EM, Jones TK, Cheatham JP, et al. (2010) Short- and medium-term outcomes after transcatheter pulmonary valve placement in the expanded multicenter US melody valve trial. *Circulation* 122: 507-516.
6. Vezmar M, Chaturvedi R, Lee KJ, Almeida C, Manlihot C, et al. (2010) Percutaneous pulmonary valve implantation in the young 2-year follow-up. *JACC Cardiovasc Interv* 3: 439-448.
7. Fraisse A, Aldebert P, Malekzadeh-Milani S, Thambo JB, Piéchaud JF, et al. (2014) Melody® transcatheter pulmonary valve implantation: results from a French registry. *Arch Cardiovasc Dis* 107: 607-614.
8. Wilson WM, Benson LN, Osten MD, Shah A, Horlick EM (2015) Transcatheter Pulmonary Valve Replacement with the Edwards Sapien System: The Toronto Experience. *JACC Cardiovasc Interv* 8: 1819-1827.
9. Rockefeller T, Shahanavaz S, Zajarias A, Balzer D (2016) Transcatheter implantation of SAPIEN 3 valve in native right ventricular outflow tract for severe pulmonary regurgitation following tetralogy of fallot repair. *Catheter Cardiovasc Interv* 10: 1002.
10. Kenny D, Hijazi ZM, Kar S, Rhodes J, Mullen M, et al. (2011) Percutaneous implantation of the Edwards SAPIEN transcatheter heart valve for conduit failure in the pulmonary position: early phase 1 results from an international multicenter clinical trial. *J Am Coll Cardiol* 58: 2248-2256.
11. Ewert P, Al-Halees Z, Biernacka EK, Pongiglione G, Haas N (2014) One Year Follow-Up of the PREMIER Multicenter Registry for the Edwards SAPIEN Pulmonic Transcatheter Heart Valve: An Interim Report. 49th annual meeting of the association for European paediatric and congenital cardiology, Prague, Czech Republic.
12. Morray BH, McElhinney DB, Cheatham JP, Zahn EM, Berman DP, et al. (2013) Risk of coronary artery compression among patients referred for transcatheter pulmonary valve implantation: a multicenter experience. *Circ Cardiovasc Interv* 6: 535-542.
13. Peng LF, McElhinney DB, Nugent AW, Powell AJ, Marshall AC (2006) Endovascular stenting of obstructed right ventricle to pulmonary artery conduits: a 15 year experience. *Circulation* 113: 2598-2605.
14. Koestenberger M, Avian A, Ravekes W (2013) Reference values of the right ventricular outflow tract (RVOT) proximal diameter in 665 healthy children and calculation of Z-score values. *Int J Cardiol* 169: 99-101.
15. Truong QA, Massaro JM, Rogers IS, Mahabadi AA, Kriegel MF, et al. (2012) Reference values for normal pulmonary artery dimensions by noncontrast cardiac computed tomography: the Framingham Heart Study. *Circ Cardiovasc Imaging* 5: 147-154.
16. Haas NA, Moysich A, Neudorf U, Mortezaeian H, Abdel-Wahab M, et al. (2013) Percutaneous implantation of the Edwards SAPIEN pulmonic valve: initial results in the first 22 patients. *Clin Res Cardiol* 102:119-128.
17. Demkow M, Rużyłło W, Biernacka EK, Kalińczuk Ł, Spiewak M, et al. (2014) Percutaneous Edwards SAPIEN™ valve implantation for significant pulmonary regurgitation after previous surgical repair with a right ventricular outflow patch. *Catheter Cardiovasc Interv* 83: 474-481.
18. Arsalan M, Mack MJ (2015) Durability of devices: long-term results and clinical outcomes. *EuroIntervention* 11: 119-122.
19. Blaiszik BJ, Kramer SLB, Olugebefola SC, Moore JS, Sottos NR, et al. (2010) Self-Healing Polymers and Composites. *Annual Review of Materials Research* 40: 179-211.