

Surgical Management of Internal Pancreatic Fistula in Chronic Pancreatitis: A Single-Center Experience

Siarhei M Rashchynski^{1,2}, Stanislau I Tretsyak¹, Yahor A Baravik^{1,2}

¹Belarusian State Medical University, Dzerzhinski Ave. 83, 220116 Minsk, Belarus

²Hospital of Emergency Medical Care, Kizhevatova srt. 58, 220024 Minsk, Belarus

ABSTRACT

Objective Management of internal pancreatic fistula is challenging because it is a rare and uncommon complication of chronic pancreatitis. The aim of this study was to evaluate the efficiency of the different ways of diagnostics and treatment for internal pancreatic fistula. **Material and methods** The prospective analysis of surgical treatment of the internal pancreatic fistula among 39 patients was carried out. Patients' data, diagnostic findings and surgical procedure were analyzed. The comparative estimation of surgical interventions was executed using questionnaire SF-36 v2™. **Results** The results of the current study demonstrate good facilities of computed tomography, magnetic resonance cholangiopancreatography (92.3%) for determination of internal pancreatic fistula. 28 patients underwent Frey's procedure, 8 - cystopancreatojejunal anastomosis using Roux-en-Y loop, 3 - combination of Frey's procedure and cystopancreatojejunal. Total morbidity and mortality was 12.8% and 2.6% respectively. We admitted significant improvement in comparison of life quality before and after operation ($p < 0.01$). **Conclusion** Surgery remains an excellent and safe option for patients suffering from internal pancreatic fistula in chronic pancreatitis with significant improvement in their quality of life.

INTRODUCTION

Internal pancreatic fistula (IPF) is a rare clinical entity, but it is a well-known serious complication of acute / chronic pancreatitis (CP) and pancreatic trauma which is associated with significant morbidity and mortality [1, 2, 3, 4, 5, 6, 7, 8, 9, 10, 11, 12, 13, 14, 15, 16, 17, 18, 19, 20, 21, 22, 23, 24, 25, 26, 27, 28, 29, 30, 31, 32]. The inflammation of the pancreas can lead to pancreatic ductal disruption and to leakage of pancreatic secretions. In the acute attack or persistent inflammation, partial pancreatic duct necrosis is usually walled off by a local inflammatory reaction. Which results in the formation of a pancreatic pseudocyst. However, in other patients the ductal disruption is not walled off or only incompletely walled off, and an IPF develops. Pancreatic ascites (PA) occurs when a disrupted pancreatic duct leads to pancreatic fluid extravasation that does not become sequestered as a pseudocyst, but drains freely into the peritoneal cavity. Occasionally, the pancreatic fluid tracks superiorly into the thorax, and a pancreatic pleural effusion (PPE) occurs [10, 19, 22]. PA and PPE occur together in 14% of cases, and 18% have a PPE alone [10, 19, 21, 22].

Prevalence of PA and PPE in patients with CP ranges from 3.5% to 18.2% [2, 3, 4, 7, 8]. PA is caused by leakage of pancreatic juice through rupture of main pancreatic duct (MPD) or tributary ducts, which is located proximal to stricture of MPD. Ductal disruption can communicate with abdominal cavity through pore of pseudocyst or directly [8, 9, 11, 21]. IPF through pseudocyst is seen in up to 80% of cases [2, 11, 24, 25, 26].

Pancreatic juice extravasation into the peritoneal cavity was described by Smith in 1953 [23]. Pancreatic ascites was first named by Cameron in 1969 [24]. Since then, no randomized controlled trials have been performed because of the low incidence of IPF. Diagnosis and treatment strategy for this complication of CP are still challenging and controversial [4, 5, 19, 21].

This study demonstrates a 14- yr. experience of IPF management. The aim of this study was to evaluate the usefulness of spiral triple-phase computed tomography (CT), magnetic resonance imaging of the pancreas (pancreatic-MR) with magnetic resonance cholangiopancreatography (MRCP) in definition of the IPF and to analyze the efficiency of different methods of surgical treatment for CP with PA and/or PPE.

PATIENTS AND METHODS

From January, 1 2002 to December, 31 2015 in the Department of Hepatobiliary Surgery in the City Clinical Hospital of Emergency Care (Minsk, Republic of Belarus), 1026 patients with various complications of CP underwent surgery. The PA and/ or PPE were identified among 39 (3.8%) patients with CP (last patient with such complication

Received April 01st, 2016 - Accepted May 30th, 2016

Keywords Pancreatitis, Chronic; Pancreatic Fistula; Surgical Procedures, Operative

Abbreviations CP chronic pancreatitis; CT computed tomography; IPF internal pancreatic fistula; MRCP magnetic resonance cholangiopancreatography

Correspondence Yahor Baravik
Tikockogo str. 34-1-52, 220119
Minsk, Belarus

Phone +375 29 6604628

E-mail goshaborovik@gmail.com

underwent surgery in February 2015). All patients were preoperatively seen by a panel of gastroenterologists and surgeons who decided on the indication for surgery.

The diagnostic algorithm before surgery included diagnostic paracentesis (with cytological, biochemically and bacteriological investigation), abdominal ultrasound, **endoscopic ultrasound (EUS)**, fiberoptic gastroduodenoscopy, triple-phase CT among all patients, and pancreatic-MR together with MRCP, when CT was unhelpful in IPF or main pancreatic duct (MPD) rupture identification.

Pre- and intraoperative outcome data was prospectively recorded in a standard form. Before the day of a surgery all patients received antibiotic prophylaxis, a weight-adapted thrombosis prophylaxis with low molecular weight heparin, and a pancreatic secretion inhibitor (octreotide, 300–600 µg/day subcutaneously for 7 days). Preoperative nutritional risk assessment was performed within the first 24 h of admission using the Subjective global assessment (SGA) [33], Nutritional Risk Screening (NRS 2002) [36]. Delay of surgery was made for patients at severe nutritional risk. Surgical intervention had been postponed until nutritional status was corrected (total protein >70 g/L; serum albumin >35 g/L; hemoglobin >133 g/L in men, >117 g/L in women; BMI >18.5).

The choice of surgical procedure depended upon the characteristics of disease for an individual patient. The surgery was not focused only on PA and PPE symptoms relief but on management of the primary disease - CP. The surgical intervention was planned according to the ductal anatomy and site of the rupture, pancreatic stones, fibrotic mass with ductal strictures particularly in the head of the pancreas and extraglandular abnormalities including pseudocysts. At the same time, we maximally preserved the functional pancreatic tissue to reduce probability of postoperative endocrine and exocrine insufficiency.

Outcome measures were postoperative complications both in-hospital regardless of total hospital stay and within 30 days following discharge to home readmission rates within 30 days from initial discharge, and 30-day mortality. Evaluated complications were pancreatic fistula, relaparotomy, postoperative hemorrhage, acute pancreatitis, wound infection and medical complications (pneumonia, renal failure, etc.).

The evaluation of the surgical interventions was carried out using a version of the questionnaire of the life quality in MOS SF-36 v.2™ [34]. The Russian version MOS SF-36 was validated by the International Centre of life quality evaluation in Saint-Petersburg [35]. The questionnaire created in the patient's native language gives more objective information. We analyzed indices of psychological and physical health before operation and in 12 - 24 month after it and relapse of PA or PPE during this period. The follow-up protocol included questioning by MOS SF-36, laboratory examination, abdominal ultrasound and ultrasound investigation of pleural cavities, chest X-ray.

The study was approved by the Government's Regional Ethics Committee, which has a broad official representation from the areas of ethics, genetics, law, medicine, psychology and nursing and also includes lay people and unrelated patients.

The data of survival patients were analyzed. Statistical analysis was performed using SPSS® for Windows release 11.0.0 (SPSS, Chicago, IL, USA) based on Wilcoxon's rank test (comparison of treatment results in groups before and after the operation). $p < 0.05$ was considered statistically significant.

RESULTS

Patients

Average age was 41 years (range 29 - 63), with 34 (87.2%) patients of being male. Twenty eight patients (71.8%) had clinical implications of PA. Among 5 patients (12.8%), the fistulas tracked up into the mediastinum and then into a pleural cavity and the presentation was with a massive PPE. Both ascites and pleural effusions were identified in six cases (15.4%). 37 patients (94.9%) were heavy drinkers and 2 patients (5.1%) had biliary etiology of pancreatitis.

All patients had been suffering attacks of severe recurrent abdominal pain (at least 1 per month requiring opiates). 38.5% of them coexisted with abdominal swelling. Large amounts of pancreatic fluid led to appearance of hernias in 3 cases. 11 patients (28.2%) had chest symptoms. On the admission physical examination, many patients were cachectic with profound temporal wasting and a grossly distended abdomen. The prevalence of patients at risk for malnutrition according to the Subjective global assessment (SGA), Nutritional Risk Screening (NRS 2002) was 43.6%. All patients with malnutrition got nutritional support, enteral and/or parenteral - for who were not able to be fed orally for various reasons for 10 - 14 days.

Diagnostics

Diagnostic paracentesis was performed among all patients with PPE and/or with volume of the PA above 1 liter (51.3%). Laparocentesis and/or thoracentesis revealed non-infected fluid with a protein level >25 g/L (inclusion criteria) and a markedly elevated amylase level (>1000 IU/L) (inclusion criteria) (100%). 32 patients with CP but with a protein level <25 g/L, amylase level <1000 IU/L (alcoholic liver disease (n=26), portal vein thrombosis (n=1), cardiac failure (n=3), malignant disease (n=2)) were excluded.

CT-scanning was performed among all patients. MPD rupture was identified in the head (51.3%) / isthmus (20.5%) (**Figure 1**) of the pancreas among 28 patients (71.8%) who had bulky head of pancreas (>35 mm), dilated MPD (>7 mm) distally to the stricture, stones in parenchyma and/or in ductal system in these cases. Those patients underwent duodenum-preserving pancreatic head resection with longitudinal pancreaticojejunostomy (Frey's procedure) [36] (**Figure 2**).

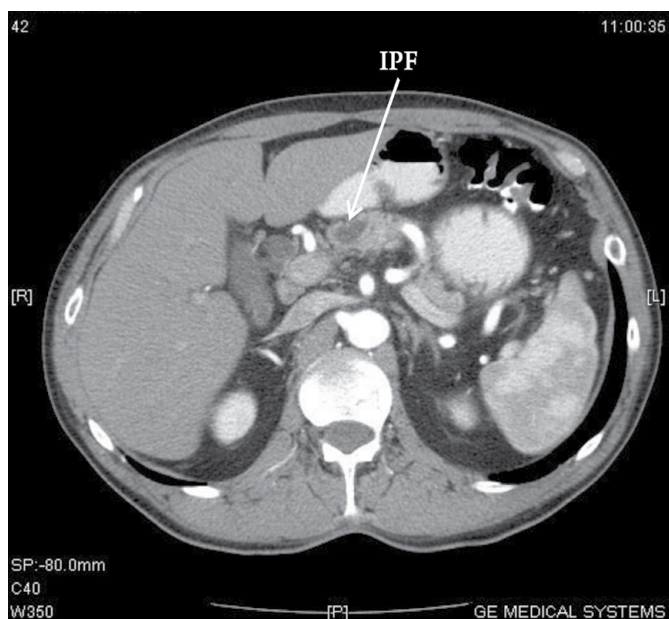


Figure 1. Example of a patient with an internal pancreatic fistula (IPF) in the place of the caput-body junction which is clearly identified at thin-slice helical CT-scan as a regular hypodense zone (arrow) with adjacent parenchymal atrophy.

Combination of CT, pancreatic-MR with MRCP made possible to reveal IPF among 8 (20.5%) patients. They had pseudocysts connected with MPD in the body or in the tail of the gland. The rest of the pancreas was revealed with signs of CP (fibrosis, stones in parenchyma) but without ductal hypertension (MPD <3 mm). We performed cystopancreatojejunal anastomosis using Roux-en-Y loop.

Among 3 (7.7%) patients we could confidently find neither MPD rupture nor fistula. According to CT- and MR-scanning, they had fibrotic pancreatic head (>40 mm), dilated Wirsung duct (>7 mm) with large (>80 mm) pseudocyst in the tail. We made the effort to visualize IPF with help of endoscopic retrograde pancreatography (ERP). Due to the presence of fibrous stenosis cannulation wasn't possible in two cases. In 1 case we found the connection between MPD and pseudocyst but nor rupture site. Extent of operation for this cohort was Frey's procedure combined with pseudocyst resection and drainage using the same jejunal Roux limb [36].

Postoperative Course

Postoperative complications, depending on the type of a surgery, are shown in **Table 1**. The overall surgical morbidity was 12.8% caused by postoperative haemorrhage once (2.6%), wound infection twice (5.1%), one patient (2.6%) with pleural effusion had pneumonia. Overall, two (5.1%) patients received a re-laparotomy. A 30-day mortality rate of 2.6% was caused by pancreaticojejunostomy leak (n=1). The length of hospital stay was 16.4 days [Me [25-75%] = 16.4 (14-19.5)]. There wasn't readmission within 30 days.

The efficiency of the surgical treatment and its influence upon life quality of patients were appraised using survey design MOS SF-36. The questioning was performed before the surgery and after 12 - 24 months. The findings of the investigation are represented in **Table 2**.

We admitted significant improvement of all score criteria after operation (p<0.01) in comparison of life quality before it. It demonstrates high results and suitability of the surgical treatment PA and PPE.

Mortality and relapse of PA / PPE weren't observed during 2 year follow - up and lab tests were normal. Neither ascites in abdominal cavity nor fluid in pleural cavities were revealed during ultrasound investigation. Chest X-ray did not show any pathology.

DISCUSSION

Chronic pancreatitis is a continuing inflammatory disease of the pancreas characterized by irreversible morphologic changes that typically cause pain and / or permanent loss of endocrine, exocrine functions [33, 37, 38]. The overall incidence of chronic pancreatitis in Europe is thought to be about 6-7 per 100 000, and data suggests increasing incidence [39, 40]. We can suggest that rare complications, such as IPF, shall encounter more often in physician's practice.

All publications show similar etiology and symptoms of IPF with PA/PPE. PA/PPE occurs in cachectic patients with abdominal pain (from mild to severe) and history of CP due to alcohol consumption (72 - 94%) [1, 2, 3, 4, 5, 6, 20]. Same patients may have increased abdominal girth with appearance of hernias (particularly umbilical hernias), dyspnea with cough which can make the doctor think about the possible presence of IPF. But this clinical progression can mimic liver diseases [41]. Confirmation can be easily made by paracentesis with subsequent fluid testing. In the majority of cases it contains high concentration of amylase (>1000 IU/L) and protein (>3 g/L) [1, 2, 3, 4, 5, 6, 9, 10, 20, 21, 22, 23, 24, 25, 26, 27, 28].

Choice of imaging method still remains unresolved in IPF visualization. The results of the current study demonstrate good facilities of CT, pancreatic-MR together with MRCP (92.3%) for determination of PA'/PPE' cause and precise localization of MPD rupture. These up-to-date, risk-free diagnostic techniques showed good results in many cases [3, 4, 5, 10, 16]. In 3 cases we couldn't confidently identify IPF so we had to use ERP. The diagnostic power of ERP is between 53 and 87% [2, 6, 16, 17, 18] but it could not be considered successful because of technical difficulties in our 2 cases. We also didn't find IPF among these patients during the surgery. We think that it was undetectably small. About 10% of IPF are impossible to monitor with any visualizing technique [39].

Treatment strategy for CP with IPF is still challenging and controversial [4, 5, 19, 25]. The conservative management landscapes of the IPF are a). Rest to the pancreas and to limit pancreatic exocrine stimulation by keeping the patients nil per os, b). Nutritional support by means of nasojejunal feeds or by total parenteral nutrition, c). Use of drugs that decrease pancreatic secretion d). Drainage of fluid by aspiration, drainage of ascites or by tube thoracocentesis [25]. The efficiency of conservative therapy of IPF ranges from 17% to 50 % [1, 2, 3, 4, 5, 10,

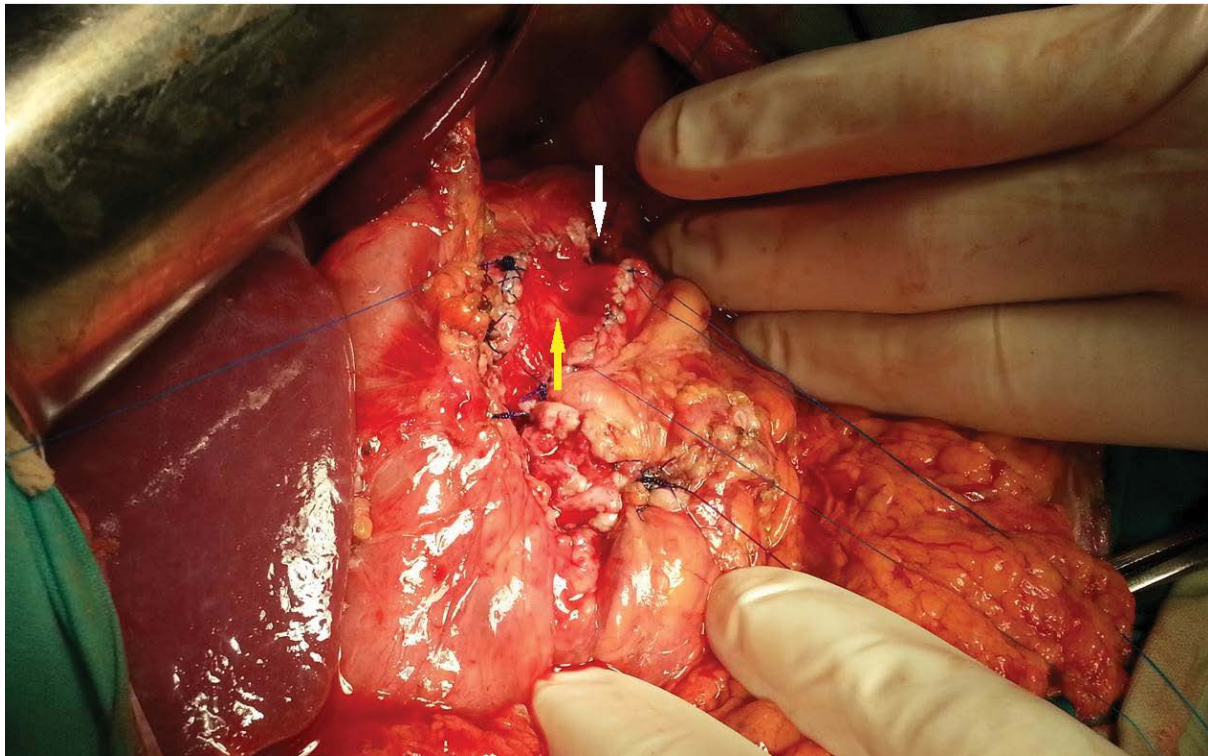


Figure 2. Example of Frey's procedure. The site of the main pancreatic duct (MPD) rupture (white arrow). Yellow arrow shows opened dilated MPD.

Table 1. Postoperative parameters.

	Frey's procedure n=31 (%)	CPJ anastomosis n= 8 (%)
Postoperative Complications		
Overall rate	4 (12.9)	1 (12.5)
Wound infection	2 (6.5)	0 (0)
Pneumonia	0 (0)	1 (12.5)
Hemorrhage	1 (3.2)	0 (0)
Pancreaticojejunal leakage	1 (3.2)	0 (0)
Reoperations	2 (6.5)	0 (0)
Mortality	1 (3.2)	0 (0)
Readmission within 30 days	0 (0)	0 (0)

CPJ cysto pancreato jejunal anastomosis using Roux-en-Y loop

Table 2. Quality of life evaluation according to SF-36 v.2™ before operation and follow-up.

Indicator	N = 39 (Me [25%-75%])		
	Before operation	After operation	rates p
Physical Functiong (PF)	12.5 [10-27.5]	42 [20-55]	p<0.01
Role-Physical (RP)	0 [0-0]	25 [25-50]	p<0.01
Bodily Pain (BP)	20 [12-22]	57 [51-64]	p<0.01
General Health (GH)	22.5 [15-30]	44.5 [30-47]	p<0.01
Vitality (VT)	20 [12.5-20]	50 [40-50]	p<0.05
Social Functioning (SF)	18.8 [0-25]	50 [37.5-75]	p<0.01
Role-Emotional (RE)	0 [0-0]	33.3 [33.3-66.7]	p<0.01
Mental Health (MH)	20 [10-24]	48 [40-68]	p<0.01
Physical Health summery (PHs)	27.5 [26.3-28.8]	35.6 [33.2-40.6]	p<0.01
Mental Health summery(MHs)	23.8 [19.9-26]	38.1 [33.1-40.6]	p<0.01

Me [25%-75%] – Mediana [25% cases – 75% cases]; p – Wilcoxon's rank test

21, 28]. The risk of death with conservative treatment is reported to be 12 - 17% [3, 4, 5, 10], so we use it just for preparation before surgery.

In many series it has been reported that endotherapy, including sphincterotomy and placement of a transduodenal pancreatic stent across the site of ductal leak, is successful in 50 - 90% of cases [5, 6, 11, 16, 18, 31]. While this method does have its advantages, it is worthwhile noting that it has a number of side effects. Complications of endoscopic stenting such as perforation, bleeding, exacerbation of pain due to acute pancreatitis, infection of associated fluid collections, alterations in ductal morphology following stenting have been marked in 0 - 9% [2, 4, 20, 30]. Relapse of PA or PPE was in 10 - 50% of patients who henceforth required surgery [5, 20, 30, 32].

The efficiency of surgical management is reported to amount of 80-92% (no relapse was observed) if the adequate decompression of MPD has been achieved [3, 4, 5, 29]. The surgical failure rate is 12-18% if a point of leakage is found before surgery [3, 4, 5, 6, 10], and the surgical mortality rate is 6 - 8.3% [3, 8, 10, 11, 29]. The considering surgical treatment facilitates to decelerate rapidity of CP progression, prevent recurrent acute exacerbations in CP and sometimes improve endocrine and exocrine pancreas functions [12, 13, 14]. In our study, all patients had indications for surgery: 28 (71.8%) underwent Frey's procedure (severe pain, head of pancreas >35 mm, dilated MPD (>7 mm), stones in parenchyma and/or in ductal system); 8 (20.5%) - cystopancreatojejunal anastomosis using Roux-en-Y loop (pain, MPD ≤ 4 mm, pseudocysts connected with MPD); Frey's procedure with cystopancreatojejunal (severe pain, head of pancreas >35 mm, dilated MPD (>7 mm), stones in parenchyma

and/or in ductal system + pseudocysts connected with MPD) was performed three times. Our article shows that surgical treatment of CP complicated PA/PPE can be safely made with low morbidity (12.8%) and mortality (2.6%). There was no relapse of PA/PPE at a follow-up of 24 months. It stands to mention that it was highly significant improvement in all quality-of-life measures [42].

The main deficiency in this current study was not able to conduct a randomized control trial as the pancreatic ascites is a rare complication of chronic pancreatitis.

CONCLUSION

Based on these findings, the following conclusions may be done: up-to-date diagnostic techniques (triple-phase CT, pancreatic-MR, MRCP) are essential in diagnosis of CP and its complications including IPF. Frey's procedure is preferable procedure for the treatment of this cohort of patients. Surgery remains an excellent and safe option for patients suffering CP that leads to significant improvement in quality of life.

Conflict of Interest

The authors declare that there is no conflict of interests.

REFERENCES

1. Uchiyama T, Yamamoto T, Mizuta E, Suzuki T. Pancreatic ascites: a collected review of 37 cases in Japan. *Hepatogastroenterology* 1989; 36:244-8. [PMID: 2478433]
2. Bracher GA, Manocha AP, DeBanto JR, Gates LK Jr, Slivka A, Whitcomb DC, Bleau BL, et al. Endoscopic pancreatic duct stenting to treat pancreatic ascites. *Gastrointest Endosc* 1999; 49:710-5. [PMID: 10343214]
3. Gomez-Cerezo J, Barbado Cano A, Suarez I, Soto A, Ríos JJ, Vazquez JJ. Pancreatic ascites: study of therapeutic options by analysis of case reports and case series between the years 1975 and 2000. *Am J Gastroenterol* 2003; 98:568-77. [PMID: 12650789]
4. Chebli JM, Gaburri PD, de Souza AF, Ornellas AT, Martins Junior EV, Chebli LA, Felga GE, et al. Internal pancreatic fistulas: proposal of a management algorithm based on a case series analysis. *J Clin Gastroenterol* 2004; 38:795-800. [PMID: 15365408]
5. O'Toole D, Vullierme MP, Ponsot P, Maire F, Calmels V, Hentic O, Hammel P, et al. Diagnosis and management of pancreatic fistulae resulting in pancreatic ascites or pleural effusions in the era of helical CT and magnetic resonance imaging. *Gastroenterol Clin Biol* 2007; 31(8-9 Pt 1):686-93. [PMID: 17925768]
6. Pai CG, Suvarna D, Bhat G. Endoscopic treatment as first-line therapy for pancreatic ascites and pleural effusion. *J Gastroenterol Hepatol* 2009; 24:1198-202. [PMID: 19486258]
7. Ahmad SA, Huffman L, McIntyre B. Chronic pancreatitis: recent advances and ongoing challenges. *Curr Probl Surg* 2006; 43:127-238. [PMID: 16530053]
8. **Beger** HG, **Matsuno** S, **Cameron** JL. (Eds.) *Diseases of the pancreas: current surgical therapy*. Springer-Verlag Berlin, Heidelberg; 2008.
9. Morgan KA, Adams DB. Management of internal and external pancreatic fistulas. *Surg Clin North Am* 2007; 87:1503-13. [PMID: 18053844]
10. Lipsett PA, Cameron JL. Internal pancreatic fistula. *Am J Surg* 1992; 163:216-20. [PMID: 1739176]
11. Eckhauser F, Raper SE, Knol JA, Mulholland MW. Surgical management of pancreatic pseudocysts, pancreatic ascites, and pancreaticopleural fistulas. *Pancreas* 1991; 6(Suppl 1):S66-S75. [PMID: 1788255]
12. Malka D, Hammel P, Sauvanet A, Rufat P, O'Toole D, Bardet P, et al. Risk factors for diabetes mellitus in chronic pancreatitis. *Gastroenterology* 2000; 119:1324-32. [PMID: 11054391]
13. Nealon WH, Thompson JC. Progressive loss of pancreatic function in chronic pancreatitis is delayed by main pancreatic duct decompression. A longitudinal prospective analysis of the modified Puestow procedure. *Ann Surg* 1993; 217:458-66; discussion 466-8. [PMID: 8489308]
14. Nealon WH, Matin S. Analysis of surgical success in preventing recurrent acute exacerbations in chronic pancreatitis. *Ann Surg* 2001; 233:233:793-800. [PMID: 11371738]
15. Ellis J, Mulligan I, Rowe J, Sackett DL. Inpatient general medicine is evidence based. A-Team, Nuffield Department of Clinical Medicine. *Lancet* 1995; 346:407-10. [PMID: 7623571]
16. Nordback I, Sand J. The value of the endoscopic pancreatogram in peritoneal or pleural pancreatic fistula. *Int Surg* 1996; 81:184-6. [PMID: 8912090]
17. Kozarek RA, Jiranek GC, Traverso LW. Endoscopic treatment of pancreatic ascites. *Am J Surg* 1994; 168:223-6. [PMID: 8080056]
18. Varadarajulu S, Noone TC, Tutuian R, Hawes RH, Cotton PB. Predictors of outcome in pancreatic duct disruption managed by endoscopic transpapillary stent placement. *Gastrointest Endosc* 2005; 61:568-75. [PMID: 15812410]
19. Fisher WE, Andersen DK, Bell Jr. RH, Saluja AK, Brunicaardi FC Pancreas. In: Brunicaardi FC, Andersen DK, eds. *Schwartz's Principles of Surgery*, 10th ed. USA, McGraw-Hill Education 2015: 1168-1244.
20. Tanaka T, Kuroki T, Kitasato A, Adachi T, Ono S, Hirabaru M, Matsushima H, et al. Endoscopic transpapillary pancreatic stenting for internal pancreatic fistula with the disruption of the pancreatic ductal system. *Pancreatol* 2013; 13:621-4. [PMID: 24280580]
21. Cameron JL. Chronic pancreatic ascites and pancreatic pleural effusions. *Gastroenterology* 1978; 74:134-40. [PMID: 618422]
22. Uchiyama T, Suzuki T, Adachi A, Hiraki S, Iizuka N. Pancreatic pleural effusion: case report and review of 113 cases in Japan. *Am J Gastroenterol* 1992; 87:387-91. [PMID: 1539580]
23. Smith EB. Hemorrhagic ascites and hemothorax associated with benign pancreatic disease. *Arch Surg* 1953; 67:52-56. [PMID: 13064942]
24. Cameron JL, Brawley RK, Bender HW, Zuidema GD. The treatment of pancreatic ascites. *Ann Surg* 1969; 170:668-76. [PMID: 5344034]
25. K. Prakash Pancreatic Ascites and Pleural Effusion. In: Luis Rodrigo Pancreatitis - Treatment and Complications. Croatia, Rijeka, 2012:195-202.
26. Dhar P, Tomey S, Jain P, Azfar M, Sachdev A, Chaudhary A. Internal pancreatic fistulae with serous effusions in chronic pancreatitis. *Aus N Z J Surg* 1996; 66:608-11. [PMID: 8859161]
27. da Cunha JE, Machado M, Bacchella T, Penteadó S, Mott CB, Jukemura J, Pinotti HW. Surgical treatment of pancreatic ascites and pancreatic pleural effusions. *Hepatogastroenterology* 1995; 42:748-51. [PMID: 8751245]
28. Alexakis N, Sutton R, Neoptolemos J. Surgical treatment of pancreatic fistula. *Dig Surg* 2004; 21:262-74 [PMID: 15308865]
29. Telford JJ, Farrell JJ, Saltzman JR, Shields SJ, Banks PA, Lichtenstein DR, Johannes RS, et al. Pancreatic stent placement for duct disruption. *Gastrointest Endosc* 2002; 56:18-24. [PMID: 12085030]
30. Delhaye M, Matos C, Devière J. Endoscopic technique for the management of pancreatitis and its complications. *Best Pract Res Clin Gastroenterol* 2004; 18:155-81. [PMID: 15123090]
31. Baron TH, Morgan DE. The diagnosis and management of fluid collections associated with pancreatitis. *Am J Med* 1997; 102:555-63. [PMID: 9217671]
32. Detsky AS, Baker JP, Mendelson RA, Wolman SL, Wesson DE, Jeejeebhoy KN. Evaluating the accuracy of nutritional assessment techniques applied to hospitalized patients: methodology and comparisons. *JPEN J Parenter Enteral Nutr* 1984; 8:153-9. [PMID: 6538911]

33. Ware JE Jr. SF-36 Health Survey. *Spine (Phila Pa 1976)* 2000; 25:3130-9 [PMID: 11124729]
 34. Novik AA, Ionova TI. Guidelines on studying the quality of life in medicine. Moscow, OLMA-PRESS 2002: 314-316.
 35. Ho HS, Frey CF. The Frey procedure: local resection of pancreatic head combined with lateral pancreaticojejunostomy. *Arch Surg* 2001; 136:1353-8. [PMID: 11735858]
 36. Ray S, Ghatak S, Das K, Dasgupta J, Ray S, Khamrui S, Sonar PK, Das S. Surgical Management of Benign Biliary Stricture in Chronic Pancreatitis: A Single-Center Experience. *Indian J Surg* 2015; 77:608-13. [PMID: 26730073]
 37. Duggan SN, Ní Chonchubhair HM, Lawal O, O'Connor DB, Conlon KC. Chronic pancreatitis: A diagnostic dilemma. *World J Gastroenterol* 2016; 22:2304-13. [PMID: 26900292]
 38. Kondrup J, Rasmussen HH, Hamberg O, Stanga Z. Ad Hoc ESPEN Working Group. Nutritional risk screening (NRS 2002): a new method based on an analysis of controlled clinical trials. *Clin Nutr* 2003; 22:321-36. [PMID: 12765673]
 39. Jupp J, Fine D, Johnson CD. The epidemiology and socioeconomic impact of chronic pancreatitis. *Best Pract Res Clin Gastroenterol* 2010; 24:219-231. [PMID: 20510824]
 40. Joergensen M, Brusgaard K, Crüger DG, Gerdes AM, de Muckadell OB. Incidence, prevalence, etiology, and prognosis of first-time chronic pancreatitis in young patients: a nationwide cohort study. *Dig Dis Sci* 2010; 55:2988-2998. [PMID: 20108119]
 41. Fernández-Cruz L, Margarona E, Llovera J, López-Boado MA, Saenz H. Pancreatic ascites. *Hepatogastroenterology* 1993; 40:150-4. [PMID: 8509046]
 42. Wani NA, Parray FQ, Wani MA. Is any surgical procedure ideal for chronic pancreatitis? *Int J Surg* 2007; 5:45-56. [PMID: 17386915]
-