

Successful Pregnancy Outcome after Removal of Multiple Fibroids Using Triple Tourniquets during First Trimester Pregnancy: A Case Report

Woldeyes WS*, Kibiret Z and Bangu H

Department of Gynecology and Obstetrics,
Tercha General Hospital, Tercha, Ethiopia

***Corresponding author:**

Wondimagegnehu Sisay Woldeyes

✉ wondmsis400@yahoo.com

Department of Gynecology and Obstetrics,
Tercha General Hospital, Tercha,
Urogynecology and Pelvic Reconstructive
Surgery Fellow at Jima University, Ethiopia.

Tel: +251-911907230

Citation: Woldeyes WS, Kibiret Z, Bangu H (2021) Successful Pregnancy Outcome after Removal of Multiple Fibroids Using Triple Tourniquets during First Trimester Pregnancy: A Case Report. Gynecol Obstet Case Rep Vol.7 No.10:164

Abstract

Majority of women with pregnancy and myoma show no or mild symptoms. Even when symptomatic, most can be treated conservatively. On rare occasions myomectomy may be necessary to alleviate the symptoms. This however carries a risk of massive bleeding and possible miscarriage. For myomectomies performed on non-pregnant uterus, we can use triple tourniquets to reduce associated bleeding. Its safety for antepartum myomectomies remains questionable. In this report, we present a rare case where antepartum myomectomy and removal of multiple fibroids was performed for a 28 years old primigravida at 9 weeks of gestation for the indication of severe persistent pain refractory to conservative management. We used triple tourniquets to reduce bleeding during the myomectomy. The pregnancy went well after the procedure and elective cesarean section was performed at term with favorable outcome. Our case demonstrates safety of myomectomy and the use of triple tourniquets in selected cases of fibroids in pregnancy.

Keywords: Myoma; Myoma and Pregnancy; Antepartum myomectomy

Received: September 16, 2021; **Accepted:** October 07, 2021; **Published:** October 14, 2021

Introduction

Depending on the trimester of assessment and size threshold used to diagnose myoma, its prevalence during pregnancy is estimated to be 1.6 to 10.7 percent. While majority of these women do not experience problems, around 10 percent will result in complications [1,2]. Most of these women present with pain but significant others will also have a slightly increased risk of obstetrical complications such as miscarriage, premature labor and delivery, abnormal fetal position, intrauterine growth restrictions and placental abruption. The prevalence of these complications is increased if there are multiple masses, if a myoma is retroplacental and if a myoma is larger than 3.6 cm in diameter [2,3].

Generally pregnancy is considered as a contraindication for myomectomy [4]. This is due to increased risk of bleeding and postoperative morbidity during myomectomy because of the increased vascularisation of the uterus during pregnancy [4,5]. Therefore when myoma is identified during pregnancy, it is generally recommended to consider conservative management

as the first line of treatment with bed rest, hydration and analgesics [1,2,5]. When these conservative measures fail to work, and the patient continues to have intractable pain and/or rapid growth of the myoma the patient remains with the need to choose between possibility of induced abortion or antepartum myomectomy with all its risks. Case reports and case series from different institutions, on the other hand, have reported safety and success with antepartum myomectomy in carefully selected patients [6,7]. The feared bleeding during myomectomy in non-pregnant population can be addressed by using mechanical (Tourniquets) or pharmacologic (vasopressin) methods [8].

Literature on cases of antepartum myomectomy during first trimester is scarce. There is no ample data on the safety of methods used for reducing bleeding for use during antepartum myomectomies. Specifically, we couldn't come across with literature on removal of multiple fibroids during early pregnancy using triple tourniquets. In this case, therefore we report a rare experience where we used triple tourniquets to reduce bleeding and removed multiple fibroids from a gravid uterus. The woman delivered an alive baby at term via cesarean section.

Case Presentation

A 28 years old primigravida presents to our hospital with complaint of lower abdominal pain, urinary frequency and constipation which are worsening in the last two weeks. The woman was seen at our hospital six months before her current visit with similar complaints and diagnosed with symptomatic myoma, but disappeared from follow up. On further questioning, she reports that she missed her menses with her last menstrual period was seven weeks from her current visit. Ultrasound examination at her previous visit revealed multiple subserous and intramural fibroids with the biggest measuring 6 cm by 8 cm. On physical examination at her current presentation, the patient had stable vitals. Abdominal examination revealed enlarged uterus comparable to 34 weeks pregnancy which was tense and considerably tender. Her hematocrit was 34 percent and urine B-hcg test was positive. Ultrasound examination revealed the myomas increased in size with biggest measuring 18 cm along its long axis. There is evidence of cystic degeneration in all the myomas. Gestational sac with yolk sac and a fetal pole with cardiac activity were seen inside the uterus. Gestational age by crown rump length was 7 weeks and 2 days. The gestational sac was located downward and posterior to the myomas and there was around 1 cm of myometrium between the myoma and the gestational sac.

With an impression of first trimester pregnancy with degenerated myoma, the patient was admitted started on parental analgesics (Tramadol and NSAID) and laxatives besides advice to use high fiber diet. After five days of admission for expectant management, the discomfort persisted and the symptoms worsened. Having failed with expectant management, we discussed with the patient and family about risks of pregnancy loss, fetal injury and hysterectomy associated with myomectomy during pregnancy. The patient consented to go ahead with first trimester myomectomy due to the severe discomfort and persistence of symptoms.

Myomectomy was performed at 8 weeks of gestation via mid line abdominal incision. Upon entry into the abdomen, we found multiple myomas. There is a biggest sub serous myoma which has pulled the right tube upwards and extends to broad ligament on that side (**Figure 1**). Another bigger intramural myoma on the left side around the anterior isthmus (**Figure 2**). The uterus appears to have been pushed backwards and three more intramural smaller myomas were identified deep in the myometrium (**Figure 3**). The surface overlying the mass is congested and was highly vascular. We applied triple tourniquet by passing number 10 Foley catheter through avascular part of broad ligaments and securing a tight knot as down on the cervix as possible anteriorly. To address blood supply from the ovarian vessels, we clumped both infundibulopelvic ligaments with soft intestinal clumps (**Figure 4**). Then we made a single longitudinal incision on top of the mass and we managed to inoculate all the fibroids via this incision. We managed to avoid entry into endometrium. We closed the dead space with intermittent mattress and figure of eight stitches using vicryl number-0. We closed the myometrium in three layers using the same stitches and we released the infundibulo pelvic clamps after 30 minutes and the cervical tourniquet after 35 minutes. We secured bleeding from the cut serosa and closed it by applying

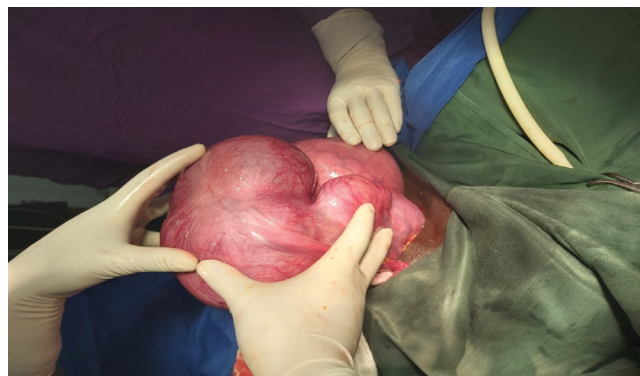

Figure 1 The biggest sub serous myoma (as seen from the right side); which has pulled the right fallopian tube upwards and extends to broad ligament on that side (Between surgeons hands).

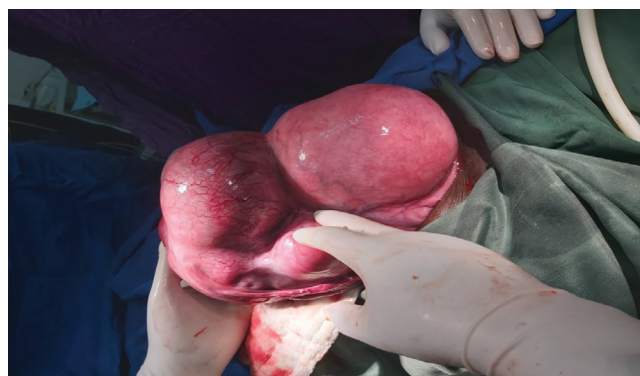


Figure 2 Bigger intramural myoma (the picture taken from the foot side of patient) around the right anterior isthmus and the uterus (pointed by surgeon's fingers) appears to have been pushed backwards.

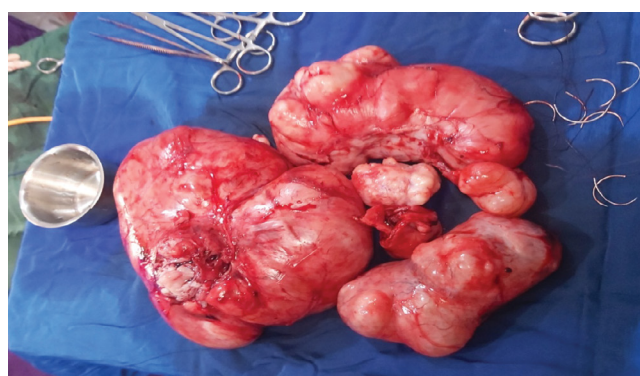

Figure 3 The myomas after inoculation; three more intramural smaller myomas were identified deep in the myometrium.

a base ball stitch using catgut number-0. After checking for hemostasis and correct count reported, we closed the abdomen. The estimated blood loss was around 600 ml. The patient left OR with stable vital sign and bedside ultrasound at recovery room

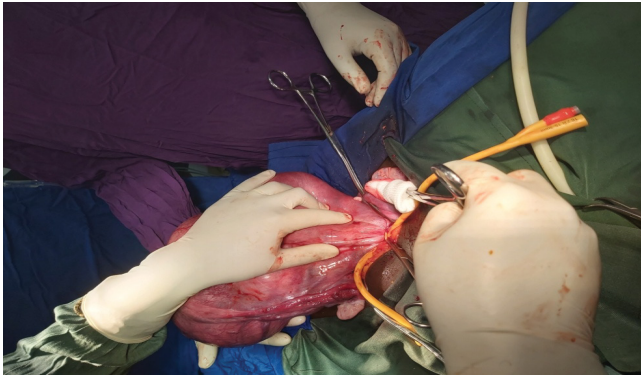


Figure 4 Triple Tourniquets: Through a small hole in the broad ligament on each side of the uterus, a number 10 Foley catheter is placed around the lower uterus and we placed soft intestinal clumps around each infundibulopelvic ligament.

revealed a viable pregnancy. After six days in our hospital the patient was discharged with stable condition with appointment.

Following discharge she received routine prenatal care and the pregnancy progressed without complications until 39 weeks of gestation. Finally an elective cesarean section was offered considering extensive transfundal dissection of the myometrium during the myomectomy. There was no major adhesion during Cesarean section and she delivered a healthy girl with an Apgar score of eight and nine and a weight of 3800 g. Her postpartum course was uncomplicated.

Discussion

Of all patients with myoma and pregnancy 5 to 15 percent will require hospitalization at some point during their pregnancy. Most of these admissions are for pain management, and almost all of these cases do well with supportive care and administration of acetaminophen as a preliminary intervention. Narcotic analgesia, or a course of nonsteroidal anti-inflammatory drugs (NSAID), can be employed when pain is not controlled by these measures. Myomectomy during pregnancy, on the other hand, is considered unsafe due to the potential risks during gravid myomectomy (including hemorrhage necessitating hysterectomy, pregnancy injury and/or pregnancy loss). For patients with intractable pain, several case series have suggested that myomectomy can be safely performed in the first and second trimesters of pregnancy. Our patient, who had severe symptoms during her early pregnancy, had persistent of her symptoms despite conservative measures and was managed with antepartum myomectomy.

In one of the largest series of myomectomy during pregnancy, where 106 pregnant women with uterine fibroids were enrolled in a clinical protocol for operative or conservative management of fibroids. Gestational age at time of surgery included both first and second trimester pregnant women. To go with surgical intervention they choose patients with recurrent pain, a rapidly growing fibroid (defined as doubling in size over eight weeks), or a fibroid >5 cm located in the lower uterine segment or deforming the placental site. According to these criteria, 18 patients

underwent myomectomy and 88 were managed conservatively. No spontaneous abortions occurred in the surgical group, while the conservatively managed group had a 13.6 percent (12/88) spontaneous abortion rate. The rate of preterm birth was lower in the surgical group (5.6 vs. 22.7 percent, respectively), but the cesarean delivery rate was higher (93.7 percent vs. 34 percent). No patient who had a myomectomy underwent puerperal hysterectomy, while 4.5 percent of conservatively managed patients underwent this procedure. Fetal outcomes were good in both groups. Our patient who had rapid growth of the mass and having persistent pain was appropriate candidate for surgical intervention.

The main concern during myomectomy on gravid uterus was hemorrhage due to increased vascularity. In none pregnant women mechanical and pharmacological methods are used to address this concern. The use of vasopressin to decrease blood loss during antepartum myomectomy with favorable outcome has been reported in case reports on both first and second trimester pregnancy [2,5,8]. Gynecologic surgeons do not often have the opportunity to use tourniquets to control bleeding; however, a myomectomy is particularly suited to their use. However, there no sufficient data on its use during myomectomy on gravid uterus. In our setting, we don't have vasopressin and we are dealing with big multiple fibroids, and therefore we decided to use the triple tourniquets to reduce blood loss during the surgery.

Pregnancy outcome after antepartum myomectomy is generally good when patients are carefully selected and operation is performed with vigilance. After the surgery, regular antenatal follow-up can be continued at usual. Decision on final mode of delivery depends on the clinicians' observation at the time of surgery. Generally in case where subserous myoma is removed or where there is no entry into endometrial cavity and there is no extensive dissection of the myometrium trial of labor and vaginal delivery is possible [1,2]. In our case we had removed multiple myoma and made extensive dissection to the myometrium and we opted for elective cesarean delivery at term.

Conclusion

Though most cases of uterine fibroids in pregnancy can be managed conservatively, myomectomy may be indicated in rare occasions. Evidence from case reports and case series indicate favorable outcome with antepartum myomectomy for carefully selected patients. Bleeding during myomectomy in this cases can be reduced by the use of vasopressin or Triple tourniquets as we do in none gravid myomectomy. Despite this report, we believe every effort should be made to avoid antepartum myomectomy until further data are available in absence compelling indications.

Ethical Approval and Consent

Informed written consent was obtained from the patient for treatment, publication of the case and use accompanying images.

Competing Interest

The authors declare that there is no competing interest regarding the publication of this case.

Authors Contribution

WS and ZK had identified, evaluated, diagnosed, followed the case, reviewed ligatures, lead both surgeries and wrote the case report where as HB made pre-anesthetic evaluation and gave anesthesia. All authors read and approved the manuscript.

References

- 1 Qidwai GI, Caughey AB, Jacoby AF (2006) Obstetric outcomes in women with sonographically identified uterine leiomyomata. *Obstet Gynecol* 107: 376.
- 2 Leach K, Khatain L, Tocce K (2011) First trimester myomectomy as an alternative to termination of pregnancy in a woman with a symptomatic uterine leiomyoma: A case report. *J Med Case Rep* 5: 571.
- 3 Burton CA, Grimes DA, March CM (1989) Surgical management of leiomyomata during pregnancy. *Obstet Gynecol* 74: 707-709.
- 4 Cunningham FG, Leveno KJ, Bloom SL, Dashe JS, Hoffman BL, et al.

Acknowledgment

I thank the client for giving me her consent to report her condition and the Tercha General Hospital for allowing me to publish this case report.

(1998) Williams obstetrics. McGraw-Hill, New York, USA.

- 5 Lolis DE, Kalantaridou SN, Makrydimas G, Sotiriadis A, Navrozoglou I, et al. (2003) Successful myomectomy during pregnancy. *Hum Reprod* 18: 1699-1702.
- 6 Celik C, Acar A, Nedim C, Kazim G, Cemalettin A (2002) Can myomectomy be performed during pregnancy? *Gynecol Obstet Invest* 53: 79-83.
- 7 Mollica G, Pittini L, Minganti E, Perri G, Pansini F (1996) Elective uterine myomectomy in pregnant women. *Clin Exp Obstet Gynecol* 1996; 23:168.
- 8 Taylor A, Sharma M, Tsirkas P, Sardo AS, Setchell M (2005) Reducing blood loss at open myomectomy using triple tourniquets: A randomised controlled trial. *BJOG* 2005; 112:340.