

CASE REPORT

Sterile Inflammation from Needle Tracking: An Unrecognized Complication of Endoscopic Ultrasound Guided Fine Needle Aspiration of Pancreatic Cyst

Murali Dharan

Department of Gastroenterology, Univeristy of Connecticut, Farmington, United States

ABSTRACT

Pancreatic cystic lesions are increasingly recognized, in part due to increasing use of imaging modalities. Diagnostic work up includes serial imaging and endosonography guided, fine needle aspiration. While generally safe endosonography - fine needle aspiration does carry associated complications bleeding, infection, perforation, pancreatitis, bile peritonitis, malignant seeding. We report a previously unrecognized complication of duodenitis felt to be due to needle tracking of pancreatic fluid.

INTRODUCTION

Pancreatic cystic lesions are increasingly identified in clinical practice because of the widespread use of imaging modalities. The prevalence of incidental pancreatic cysts is reported to range in up to 2% of patients undergoing CT or MRI imaging [1, 2]. Based on symptoms or imaging characteristics these may require close observation or interventions such as FNA or resection. While generally a safe procedure, EUS-FNA has associated complications including infection, perforation, pancreatitis, bleeding, bile peritonitis and malignant seeding (in FNA of malignant lesions) [3].

We hereby report a case of duodenitis associated with this procedure. This has not been previously reported in the literature to the best of our knowledge.

CASE REPORT

A forty-eight-year-old female with a previous diagnosis of incidental pancreatic cyst on imaging was referred for EUS work up when serial imaging was suggestive of interval increase in size. She was asymptomatic with no antecedent history of pancreatitis. All the lab work was normal. MRCP had shown a normal sized pancreas with a bi-lobed cystic lesion (1.8×0.8 cm) within the uncinata process

of the pancreas, that was concerning for an IPMN (intra-pancreatic mucinous neoplasm). Biliary and pancreatic ductal systems appeared normal. EUS guided FNA done to further characterize the cystic lesion and demonstrated an anechoic lesion (14×12 mm) in the uncinata process of the pancreas with communication with main PD (pancreatic duct). It was a thin walled septate lesion with no internal debris. Color Doppler guided FNA was done with a 22G needle (Wilson Cook Echotip) via the transduodenal approach (**Figure 1**). 2 mL of clear, serous fluid was aspirated and was sent for biochemical and cytological analysis. The cyst was not completely aspirated. Routine aseptic measures were followed and patient also received prophylactic antibiotics. Patient tolerated the procedure well and was discharged. Cyst fluid analysis showed elevated amylase levels of 376700 u/L and CEA levels of 334 ng/mL and cytology did not reveal any evidence of malignancy.

She presented 2 days later with epigastric pain, nausea and vomiting. No fever was documented. Serum amylase and lipase and other lab tests including WBC were normal. CT abdomen showed no abnormality in the head of the pancreas with the loss of normal fascial plane between it and third part of duodenum. Second and third parts of duodenum had prominent wall edema suggestive of duodenitis (**Figure 2**). There was no evidence of pneumoperitoneum. The patient was managed conservatively (nil per os status, IV fluids, analgesia and antibiotics). As her symptoms resolved over the next 3-5 days, her diet was advanced and she was discharged from the hospital.

Findings were consistent with side branch IPMN (elevated amylase levels likely due communication with main PD and elevated CEA levels suggestive of mucinous lesion). Following discussions at the out-patient visit the

Received May 25th, 2017-Accepted July 07th, 2017

Keywords Fistula; Pancreas

Abbreviation EUS endosonography; FNA fine needle aspiration; PCL pancreatic cystic lesions

Correspondence Murali Dharan

Department of Gastroenterology

Univeristy of Connecticut

Farmington Avenue

Farmington, CT

United States

Tel + 1 2035438408

Fax + 1 860 243 9701

E-mail dharan.murali@gmail.com

patient decided to monitor the PCL with serial cross-sectional imaging,

DISCUSSION

EUS guided FNA has a complimentary role in the diagnostic work up of pancreatic cystic lesions. While EUS offers detailed morphologic description of the lesions, FNA provides cytological and biochemical analysis. Reported complication rate of pancreatitis following EUS guided FNA of pancreas ranges from 0 to 2%, and does not appear to be influenced by needle size or type of lesion (solid versus cystic) [4,5,6,7,8,9].

Duodenitis has not been previously described as a known complication of EUS guided FNA. FNA was performed with a single pass using a 22 gauge non-coring needle. Studies have not demonstrated direct correlation with needle size and complication rates. The patient did not meet criteria for post EUS-FNA pancreatitis. The pancreas appeared normal on imaging and serum amylase and lipase within were within normal range. Patient symptoms were likely related to duodenal wall edema (**Figure 3**).

We hypothesize that there was tracking of pancreatic fluid along the needle path with extravasation into the wall of the duodenum. It is conceivable that the thinner duodenal wall (as opposed to the gastric wall) is more susceptible to sterile inflammation related to extravagated pancreatic fluid. Further the exophytic nature of the cyst and caudal relationship of the third and fourth portions of the duodenum, branch type of IPMN cyst and communication with main PD were likely contributing factors. As a non-coring needle was used, significant disruption of the lining of the cyst wall was unlikely – as evidenced by preserved cyst wall on CT scan.

While pancreatitis following EUS-FNA of the pancreas is a well recognized complication, sterile inflammation due to extravasation of pancreatic fluid (related to FNA of pancreatic cyst) needs to be considered as a separate entity akin to needle tracking complications such as bile peritonitis [10, 11] and malignant seeding [12]. This complication is likely to occur exclusively with pancreatic cystic lesions as opposed to pancreatitis which occurs with FNA of both solid and cystic lesions.

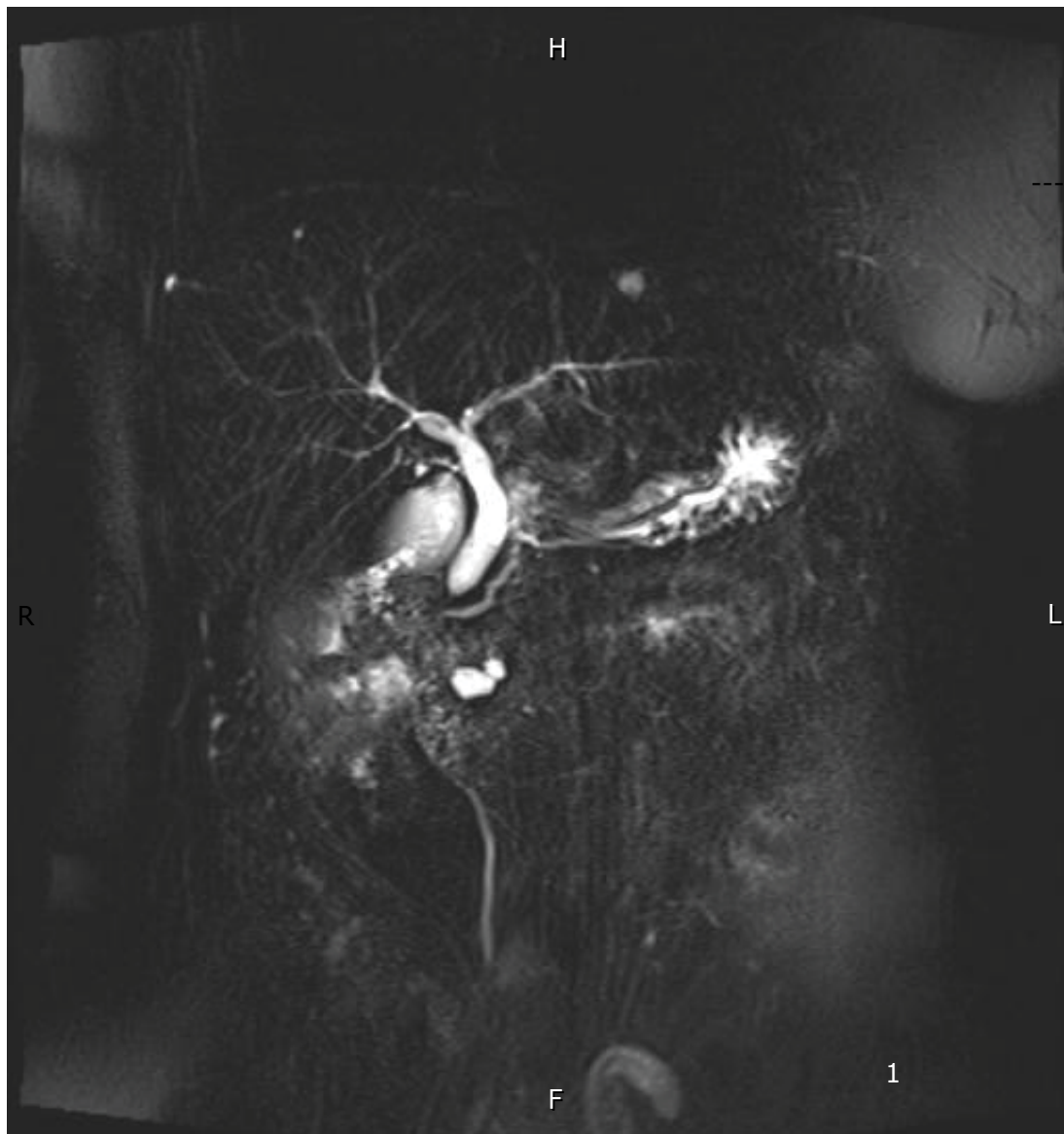


Figure 1. MRCP showing exophytic cyst in the uncinata pancreas.

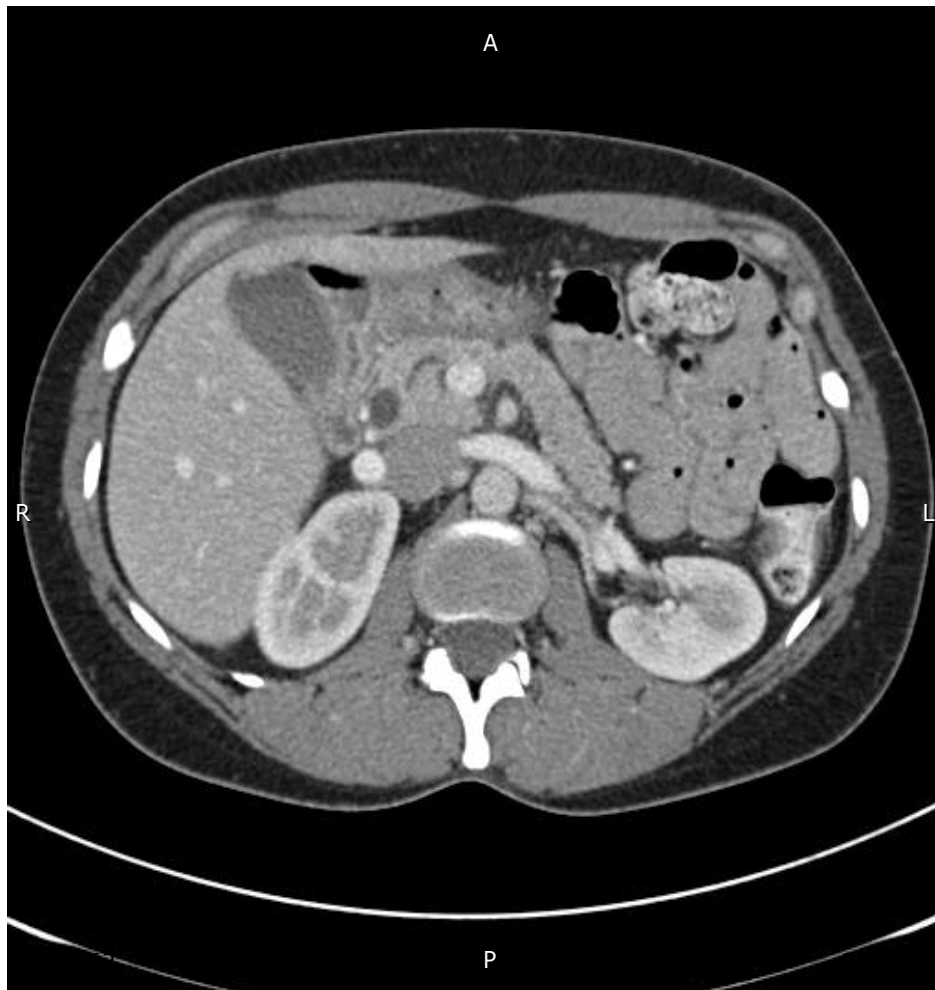

Figure 2. Post EUS-FNA CT showing – cyst without wall disruption and normal pancreas.

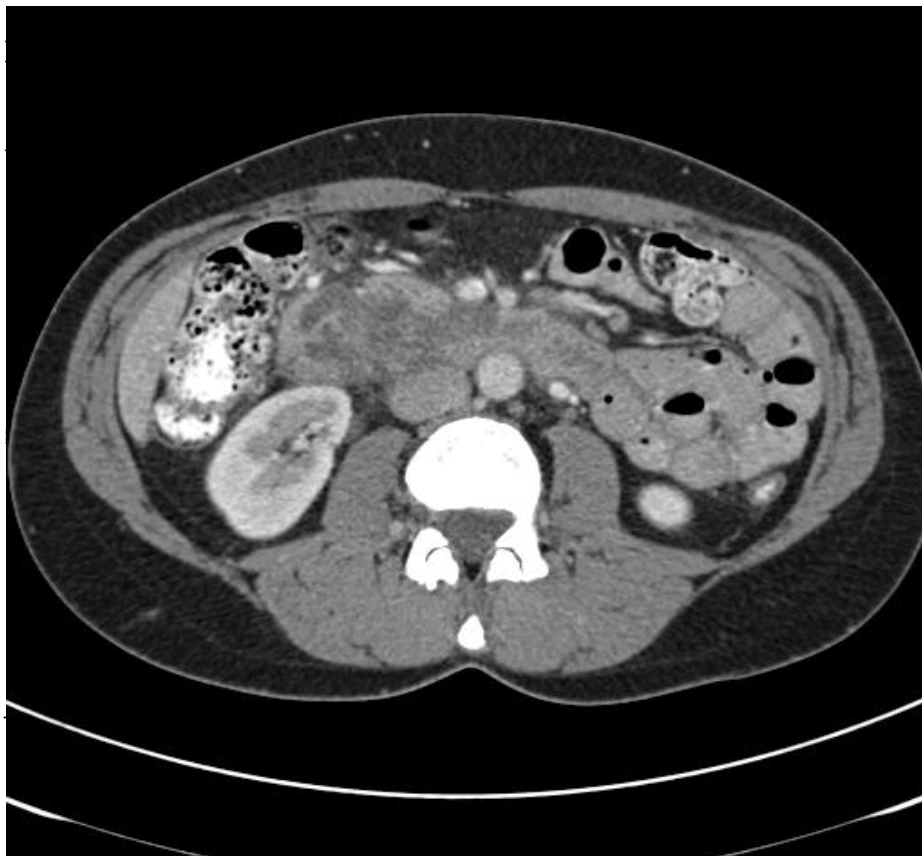

Figure 3. Post EUS-FNA CT showing inflammation of distal duodenum.

As with post EUS-FNA pancreatitis, expectant management and supportive care is often sufficient, as was the case with our patient.

Conflict of Interest

The authors declare that they have no conflict of interest.

References

1. Laffan TA, Horton KM, Klein AP, Berlanstein B, Siegelman SS, Kawamoto S, et al. Prevalence of unsuspected pancreatic cysts on MDCT. *AJR Am J Roentgenol* 2008; 191:802. [PMID: 18716113]
2. de Jong K, Nio CY, Hermans JJ, Dijkgraaf MG, Gouma DJ, van Eijck CH, et al. High prevalence of pancreatic cysts detected by screening magnetic resonance imaging examinations. *Clin Gastroenterol Hepatol* 2010; 8:806-11. [PMID: 20621679]
3. ASGE Standards of Practice Committee, Early DS, Acosta RD, Chandrasekhara V, Chathadi KV, Decker GA, et al. Adverse events associated with EUS and EUS with FNA. *Gastrointest Endosc* 2013; 77:839-43. [PMID: 23684089]
4. Williams D, Sahai A, Aabakken L, Penman I, van Velse A, Webb J, et al. Endoscopic ultrasound guided fine needle aspiration biopsy: a large single center experience. *Gut* 1999; 44:720-6. [PMCID: PMC1727480]
5. O'Toole D, Palazzo L, Arotçarena R, Dancour A, Aubert A, Hammel P, et al. Assessment of complications of EUS guided fine needle aspiration. *Gastrointest Endosc* 2001; 53:470-4. [PMID: 11275888]
6. Eloubeidi MA, Chen VK, Eltoun IA, Jhala D, Chhieng DC, Jhala N, et al. Endoscopic ultrasound-guided fine needle aspiration biopsy of patients with suspected pancreatic cancer: diagnostic accuracy and 30-day complications. *Am J Gastroenterology* 2003; 98:2663-8. [PMID: 14687813]
7. Gress F, Michael H, Gelrud D, Patel P, Gottlieb K, Singh F, et al. EUS-guided fine needle aspiration of the pancreas: evaluation of pancreatitis as a complication. *Gastrointest Endosc* 2002; 56:864-7. [PMID: 12447299]
8. Siddiqui UD, Rossi F, Rosenthal LS, Padda MS, Murali-Dharan V, Aslanian HR. EUS-guided FNA of solid pancreatic masses: a prospective, randomized trial comparing 22-gauge and 25-gauge needles. *Gastrointest Endosc* 2009; 70:1093-7. [PMID: 19640524]
9. Rodríguez-D'Jesús A, Fernández-Esparrach G, Marra-Lopez C, Orive-Calzada A, Sendino O, Araujo IK, et al. Adverse events of EUS-guided FNA of pancreatic cystic and solid lesions by using the lexicon proposed in an ASGE workshop: a prospective and comparative study. *Gastrointest Endosc* 2016; 83:780-4. [PMID: 26301408]
10. Chen HY, Lee CH, Hsieh CH. Bile peritonitis after EUS guided fine needle aspiration. *Gastrointest Endosc* 2002; 56:594-6. [PMID: 12297789]
11. Jacobson BC, Waxman I, Parmar K, Kauffman JM, Clarke GA, Van Dam J. Endoscopic ultrasound guided gallbladder bile aspiration in idiopathic pancreatitis carries a significant risk of bile peritonitis. *Pancreatology* 2002; 2:26-9. [PMID: 12120002]
12. Chong A, Venugopal K, Segarajasingam D, Lisewski D. Tumor seeding after EUS-guided FNA of pancreatic tail neoplasia. *Gastrointest Endosc* 2011; 74:933-5. [PMID: 21951481]