

## CASE REPORT

---

# Solid Pseudopapillary Tumor as a Possible Cause of Acute Pancreatitis

Junichi Sakagami, Keisho Kataoka, Yoshio Sogame, Atsuko Taii, Toshimasa Ojima, Daisuke Kanemitsu, Ryusuke Takada, Reiko Ito, Tomoko Motoyoshi, Hiroaki Yasuda, Shoji Mitsufuji, Takeshi Okanoue

Department of Molecular Gastroenterology and Hepatology, Graduate School of Medical Science, Kyoto Prefectural University of Medicine. Kyoto, Japan

### ABSTRACT

**Context** Acute pancreatitis is not commonly seen in the first presentation of pancreatic neoplasms. Solid pseudopapillary tumor as a cause of acute pancreatitis has not yet been reported. This is the first report of acute pancreatitis resulting from solid pseudopapillary tumor.

**Case report** We report the case of a 21-year-old female who presented with a sudden onset of severe abdominal pain associated with elevated serum pancreatic enzyme concentration. The initial diagnosis was acute pancreatitis. However, subsequent ultrasonography and computed tomography showed an abdominal mass in the tail of the pancreas, retroperitoneal fluid and left pleural effusion. There was scarce pain relief even with large doses of analgesics. A distal pancreatectomy was then performed and a final diagnosis of solid pseudopapillary tumor was made histologically. The surrounding pancreatic tissue was characterized as hemorrhagic edematous pancreatitis.

**Conclusions** Solid pseudopapillary tumor is generally known as a slow-growing pancreatic neoplasm with few, if any, symptoms. However, solid pseudopapillary

tumors should be kept in mind as a possible cause of acute pancreatitis, especially in cases of non-alcoholic young women having an acute pancreatitis attack.

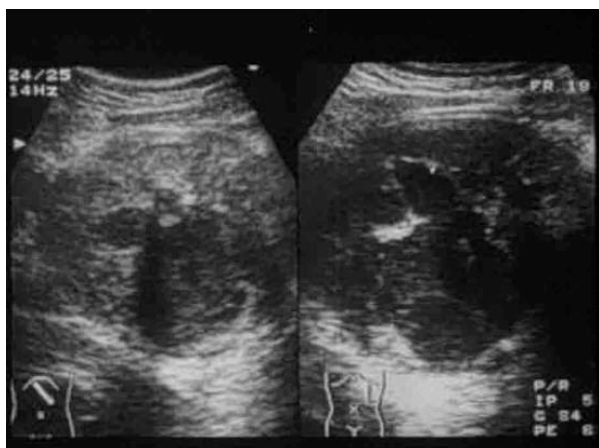
---

### INTRODUCTION

It is widely accepted that major causes of acute pancreatitis are alcohol ingestion and gallstones [1, 2, 3]. A pancreatic neoplasm is a rare etiologic factor of acute pancreatitis [4]. Solid pseudopapillary tumor (SPT) is one of the rare pancreatic neoplasms which occur mostly among young women. Most patients with SPT have been reported to be minimally symptomatic [5, 6]. We herewith report the case of a young woman with SPT which was regarded as a possible cause of acute pancreatitis. To our knowledge, this is the first report of a case of acute pancreatitis which resulted from SPT.

### CASE REPORT

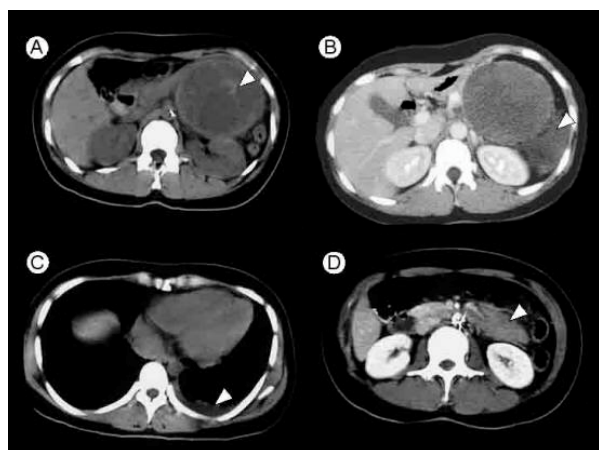
A 21-year-old Japanese female was admitted to our hospital due to a sudden onset of nausea and upper abdominal pain. She had not taken any drugs before the onset of the symptoms. She had no history of alcohol ingestion, gallstone disease, abdominal



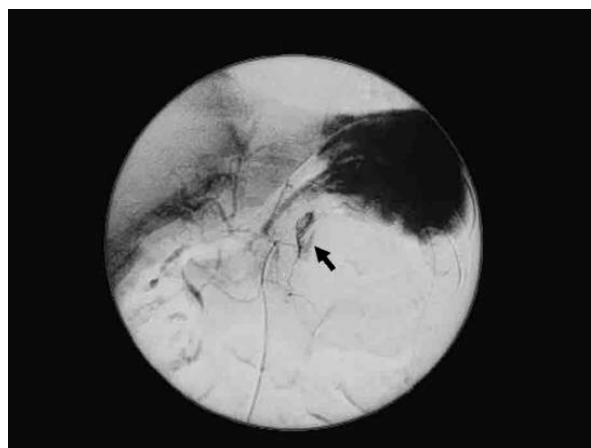
**Figure 1.** A round tumor with non-homogenous echogenicity was located in the left epigastrium. Irregular-shaped cystic lesions were found in the tumor.

trauma or surgery. On physical examination, severe tenderness in the epigastrium with hypoactive bowel sound was noted.

Laboratory data on admission showed elevated serum levels of pancreatic enzymes, i.e., amylase (502 IU/L; reference range: 35-133 IU/L), lipase (540 IU/L; reference range: 7-38 IU/L) pancreatic phospholipase A<sub>2</sub> (580 ng/dL; reference range: 130-400 ng/dL), elastase-I (590 ng/dL; reference range: 0-400 ng/dL), pancreatic secretory trypsin inhibitor (53.6 ng/mL; reference range: 5.9-22.7



**Figure 2.** a. A grossly circumscribed tumor was located on the tail of the pancreas. A high density area indicating internal bleeding was found on unenhanced CT (arrowhead). b. The surrounding fluid retention was present in the retroperitoneum (arrowhead). c. Left pleural effusion was observed (arrowhead). d. The tail of the pancreas caudal to the tumor was poorly enhanced and moderately swollen (arrowhead).



**Figure 3.** Angiography of the celiac artery. The splenic artery was displaced upward. Extravasation of contrast media in the tumor was noted (arrow).

ng/mL). The white cell count was 13,400 mm<sup>-3</sup> (reference range: 3,200-8,500 mm<sup>-3</sup>) and the CRP value was as high as 28.8 mg/dL (reference range: 0-0.4 mg/dL).

Serum values of blood urea nitrogen, creatinine, LDH, alkaline phosphatase, calcium and bilirubin were within their normal ranges. Serum concentrations of CEA and CA 19-9 were also within their normal ranges, i.e., CEA (2.4 ng/mL; reference range: 0-5.0 ng/mL) and CA 19-9 (11.0 U/mL; reference range: 0-37 U/mL).

Abdominal ultrasonography revealed a non-homogeneous round tumor 8 cm in diameter having irregularly-shaped cystic lesions within (Figure 1). A CT scan showed an accumulation of fluid in the retroperitoneal space beside the tumor in the pancreatic tail. The tumor showed internal hemorrhage. Left pleural effusion was also noted. The tail of the pancreas was swollen and poorly enhanced by contrast media (Figure 2, a-d).

Angiography revealed displacement of the splenic artery caused by the hypovascular tumor, in which an extravasation was seen (Figure 3).

The upper abdominal pain was excruciating, although the patient was given large i.v. doses of pentazocine (about 240 mg/day). The administration of buprenorphine hydrochloride instead of pentazocine did not quell the pain either. Although the preoperative diagnosis was not clear, en-block

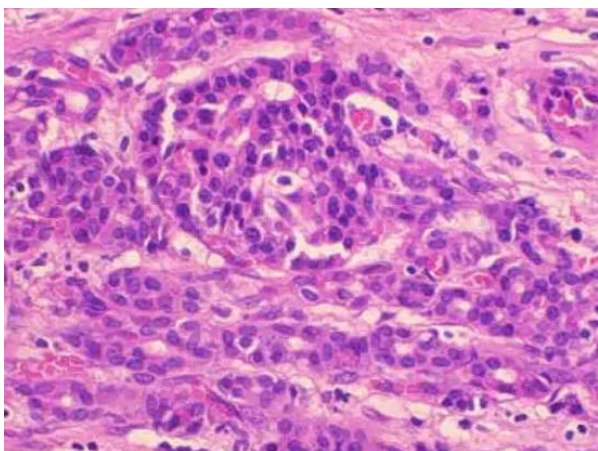


**Figure 4.** The resected tumor measuring 8x9x9cm was well-encapsulated. Hemorrhagic cystic components showed polymorphism within the tumor.

distal pancreatectomy and splenectomy were urgently performed. The resected tumor was spheric in shape and fully enclosed in a tight capsule. The cross-sectional surfaces showed solid and hemorrhagic-cystic components (Figure 4). Tumor rupture or hemoperitoneum was not apparent.

Histological examination after the resection showed the tumor to be well-encapsulated with a fibrous partition free of local invasion and an irregularly arranged pseudopapillary structure composed of fairly uniform tumor cells was found within (Figure 5). The final diagnosis of SPT was made accordingly. The surrounding pancreatic structure was characteristic of hemorrhagic edematous pancreatitis (Figure 6).

The patient made an uneventful recovery in a 3.5-year long follow-up after the surgery.



**Figure 5.** Photomicrograph indicates that the tumor composed of irregular pseudopapillary structures. (hematoxylin and eosin stain; original magnification x400).

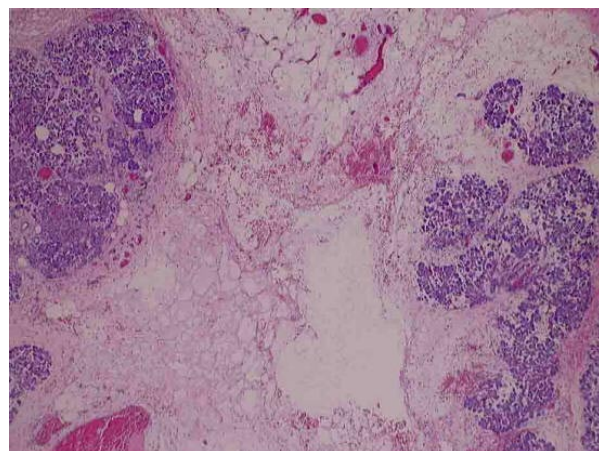
## DISCUSSION

SPT of the pancreas was first described by Frantz in 1959 [7]. Recently, reports of the tumor, predominantly seen among the Asian and Black populations have been increasing, and approximately 500 cases of the tumor have been published to date [8]. SPT accounts for about 1-2% of all non-endocrine pancreatic neoplasms [9].

SPT of the pancreas is considered to be a slow-growing neoplasm of unknown etiology. Kato *et al.* demonstrated that the doubling time of this tumor was extremely long [10]. Furthermore, Enosawa showed that the proliferative activity was quite low even in cases with malignant behavior [11].

The tumor often affects young women and the prognosis is favorable after resection. Half of the tumors in the literature have been found by chance in asymptomatic individuals. The remaining half showed mild abdominal pain or a painless abdominal lump [5, 6, 12, 13, 14, 15]. In the cases reported, physical examinations were of little value except for identification of a mass located in the upper abdomen [14]. Mao *et al.* indicated SPT is often large in size with a mean diameter of 10.3 cm at the time of diagnosis [16]. The lack of symptoms, as described above, may account for the advanced stage of the tumor at the time of discovery.

Although SPT has been reported as a benign



**Figure 6.** Photomicrograph of the surrounding pancreatic tissue shows marked intestinal edema with hemorrhage. (hematoxylin and eosin stain; original magnification x40).

tumor with modest symptoms, we present a case of the tumor which caused severe abdominal pain accompanied by high serum levels of pancreatic enzymes.

As far as we can ascertain, there have been 3 cases of SPT with acute manifestation of intense abdominal pain [17, 18, 19]. All of them had acute onsets following blunt abdominal trauma. However, none of the patients were positive for serum pancreatic enzymes. Unlike these reports, our case had no history of abdominal trauma and had high serum pancreatic enzyme levels. Histological examination along with imaging procedures proved concomitant acute pancreatitis. To our knowledge, there has been no such case of SPT reported so far.

Some cases have been reported with SPT accompanying distant metastases, invasion to surrounding organs or vessels, or local recurrence after resection [8, 20, 21, 22]. Even in such cases with aggressive behavior, the tumors have never been followed by an episode of acute pancreatitis and their prognoses have been favorable. Mao *et al.* demonstrated that 8 of the 292 cases with SPT showed hemoperitoneum caused by the rupture of the tumor capsule. In four of the 8 cases, there was no episode of abdominal trauma [16]. Also in our case, retroperitoneal fluid retention was found by CT. However, abdominal surgery revealed neither hemorrhagic ascites nor tumor rupture. We considered the emergence of retroperitoneal fluid and left pleural effusion concomitant features of the acute pancreatitis. The resected pancreas caudal to the tumor showed marked interstitial edema with hemorrhage. The exact mechanism whereby this tumor may cause acute pancreatitis is not clear. The current case had no histological evidence of lymphatic or vascular invasion. We hypothesize that non-traumatic internal bleeding may lead to rapid tumor expansion, which results in acute pancreatitis triggered by ischemia, distension or duct obstruction.

---

Received May 20<sup>th</sup>, 2004 - Accepted May 28<sup>th</sup>, 2004

**Keywords** Angiography; Pancreatic Neoplasms; Pancreatitis; Tomography, X-Ray; Ultrasonography

**Abbreviations** SPT: solid pseudopapillary tumor

**Correspondence**

Junichi Sakagami  
465 Kajiicho Hirokoji Kawaramachi  
Kamigyoku  
Kyoto  
602-8566 Japan  
Phone: +81-75.251.5519  
Fax: +81-75.251.0710  
E-mail address: green-gables@fan.hi-ho.ne.jp

---

**References**

1. Chang MC, Su CH, Sun MS, Huang SC, Chiu CT, Chen MC, et al. Etiology of acute pancreatitis--a multi-center study in Taiwan. *Hepatogastroenterology* 2003; 50:1655-7. [PMID 14571809]
2. Gislason H, Horn A, Hoem D, Andren-Sandberg A, Imsland AK, Soreide O, et al. Acute pancreatitis in Bergen, Norway. A study on incidence, etiology and severity. *Scand J Surg* 2004; 93:29-33. [PMID 15116816]
3. Cavallini G, Frulloni L, Bassi C, Gabbriellini A, Castoldi L, Costamagna G, et al. Prospective multicentre survey on acute pancreatitis in Italy (ProInf-AISP): results on 1005 patients. *Dig Liver Dis* 2004; 36:205-11. [PMID 15046191]
4. Zyromski NJ, Haidenberg J, Sarr MG. Necrotizing pancreatitis caused by pancreatic ductal adenocarcinoma. *Pancreas* 2001; 22:431-2. [PMID 11345146]
5. Podevin J, Triaux S, Mirallie E, Le Borgne J. Solid-pseudopapillary tumor of the pancreas: a clinical study of five cases, and review of the literature. *Ann Chir* 2003; 128:543-8. [PMID 14559306]
6. Pettinato G, Di Vizio D, Manivel JC, Pambuccian SE, Somma P, Insabato L. Solid-pseudopapillary tumor of the pancreas: a neoplasm with distinct and highly characteristic cytological features. *Diagn Cytopathol* 2002; 27:325-34. [PMID 12451561]
7. Frantz VK. Tumors of the pancreas. In: *Atlas of Tumor Pathology. Section 7, fascicles 27 and 28.* Washington, DC, USA: Armed Forces Institute of Pathology; 1959:32-3.
8. Lam KY, Lo CY, Fan ST. Pancreatic solid-cystic-papillary tumor: clinicopathologic features in eight

patients from Hong Kong and review of the literature. *World J Surg* 1999; 23:1045-50. [PMID 10512945]

9. Solcia E, Capella C, Kloppel G. Tumor of the pancreas. In: *Atlas of Tumor Pathology*. 3rd series, Fascicle 20. Washington, DC, USA: Armed Forces Institute of Pathology; 1997:120-44.

10. Kato T, Egawa N, Kamisawa T, Tu Y, Sanaka M, Sakaki N, et al. A case of solid pseudopapillary neoplasm of the pancreas and tumor doubling time. *Pancreatology* 2002; 2:495-8. [PMID 12378119]

11. Enosawa T. A study on capsular invasion and regressive degeneration of solid cystic tumor of the pancreas: proliferative activity of anti-Ki-67 and contribution of apoptosis. *J Jpn Panc Soc* 1999; 14:59-65.

12. Jagannath P, Bhansali MS, Murthy SK, Mohandas KM, Swaroop VS, DeSouza LJ. Solid and cystic papillary neoplasm of pancreas-a report of seven cases. *Indian J Gastroenterol* 1994; 13:112-4. [PMID 7829138]

13. Bahri I, Njim L, Khabir A, Mahmoudi H, Ghorbel A, Zakhama A, et al. Solid cystic papillary tumor of the pancreas. *Ann Chir* 2001; 126:899-902. [PMID 11760583]

14. Ng KH, Tan PH, Thng CH, Ooi LL. Solid pseudopapillary tumour of the pancreas. *ANZ J Surg* 2003; 73:410-5. [PMID 12801340]

15. Colovic R, Micev M, Zogovic S, Colovic N, Stojkovic M, Grubor N. Solid and cystic-papillary tumor of the pancreas. *Srp Arh Celok Lek* 2000; 128:393-6. [PMID 11337920]

16. Mao C, Guvendi M, Domenico DR, Kim K, Thomford NR, Howard JM. Papillary cystic and solid

tumors of the pancreas: a pancreatic embryonic tumor? Studies of three cases and cumulative review of the world's literature. *Surgery* 1995; 118:821-8. [PMID 7482268]

17. Hansson B, Hubens G, Hagendorens M, Deprettere A, Colpaert C, Eyskens E. Frantz's tumour of the pancreas presenting as a post-traumatic pancreatic pseudocyst. *Acta Chir Belg* 1999; 99:82-4. [PMID 10352738]

18. Cervantes-Monteil F, Florez-Zorrilla C, Alvarez-Martinez I. Solid-cystic pseudopapillary tumor of the pancreas: acute post-traumatic presentation. Case report and review of the literature. *Rev Gastroenterol Mex* 2002; 67:93-6. [PMID 12214341]

19. Potrc S, Kavalar R, Horvat M, Gadzijev EM. Urgent Whipple resection for solid pseudopapillary tumor of the pancreas. *J Hepatobiliary Pancreat Surg* 2003; 10:386-9. [PMID 14598141]

20. Gonzalez-Campora R, Rios Martin JJ, Villar Rodriguez JL, Otal Salaverri C, Hevia Vazquez A, Valladolid JM, et al. Papillary cystic neoplasm of the pancreas with liver metastasis coexisting with thyroid papillary carcinoma. *Arch Pathol Lab Med* 1995; 119:268-73. [PMID 7887782]

21. Pasquiou C, Scoazec JY, Gentil-Perret A, Taniere P, Ranchere-Vince D, Partensky C, et al. Solid pseudopapillary tumors of the pancreas. Pathology report of 13 cases. *Gastroenterol Clin Biol* 1999; 23:207-14. [PMID 10353015]

22. Muller-Hocker J, Zietz CH, Sendelhofert A. Deregulated expression of cell cycle-associated proteins in solid pseudopapillary tumor of the pancreas. *Mod Pathol* 2001; 14:47-53. [PMID 11235905]