

Small Bowel Hernia Following Laparoscopic Extraperitoneal Para-Aortic Lymphadenectomy for Endometrial Cancer

Lanteigne L^{1,2*}, Liakou C¹ and Burbos N¹

¹Department of Obstetrics and Gynecology, Norfolk and Norwich University Hospital, Norwich, United Kingdom (UK)

²Norfolk and Norwich Institute of Multi-professional Education (NANIME), Bob Champion Research and Education Building, Norwich, United Kingdom (UK)

*Corresponding author: Luc Lanteigne

✉ llanteig@sgu.edu

Department of Obstetrics and Gynecology, Norfolk and Norwich University Hospital, Norwich, United Kingdom (UK).

Tel: +1-754-302-1215

Abstract

In the treatment of endometrial carcinoma, surgical management is the mainstay. Total hysterectomy and bilateral salpingo-oophorectomy followed by intraoperative staging is indicated for determining patient management and prognosis. Dissection of the para-aortic and pelvic lymph nodes is performed to predict patient prognosis to determine need for adjuvant chemotherapy. Laparoscopic left extraperitoneal para-aortic lymphadenectomy is an effective approach offering various benefits compared to the conventional transperitoneal route. An internal hernia of small bowel into preperitoneal space has never been reported in a patient undergoing extraperitoneal para-aortic lymphadenectomy. We present the first case of extraperitoneal small bowel hernia, following surgical management and staging of endometrial cancer in a 64-year-old female, which led to bowel strangulation, subsequent ischemia and the need for bowel resection and anastomosis.

Keywords: Extraperitoneal para-aortic lymphadenectomy; Endometrial cancer; Internal hernia; Laparoscopic surgery

Received: August 23, 2021; **Accepted:** September 14, 2021; **Published:** September 21, 2021

Introduction

Endometrial cancer is the most prevalent gynaecologic malignancy in the developed world and is the second most common cancer affecting women [1]. Surgical management is the mainstay, including total hysterectomy and Bilateral Salpingo-Oophorectomy (BSO) followed by intraoperative staging as indicated. Dissection of the para-aortic and pelvic lymph nodes is performed, when required, in order to predict patient prognosis and also to determine the need for adjuvant treatment [2]. The most challenging part of the procedure is the para-aortic lymphadenectomy which can be performed via extraperitoneal or transperitoneal approach, with the former being less commonly used [3].

There are a few reported studies assessing the feasibility and safety of the extraperitoneal para-aortic lymphadenectomy, but none of them reporting on extraperitoneal bowel hernia as a complication of the procedure [4-6]. This complication has been described in the context of peritoneal defects following laparoscopic inguinal hernia repairs either via Transabdominal Preperitoneal (TAPP) or Total Extraperitoneal (TEP) approach [7-10].

This report outlines a case of a post-operative preperitoneal hernia

following an uncomplicated laparoscopic para-aortic and pelvic lymphadenectomy, total hysterectomy, and BSO for endometrial cancer.

Case Presentation

A 64-year-old woman diagnosed with serous endometrial carcinoma underwent total laparoscopic hysterectomy, BSO, pelvic and para-aortic lymphadenectomy. A left extraperitoneal approach involving three ports (12 mm, 10 mm and 5 mm) was utilised to perform para-aortic lymphadenectomy up to the level of the left renal vein. Subsequently, an incision was made on the peritoneum of the left lower abdomen and the 12 mm port was advanced within the peritoneal cavity. Two additional ports were inserted in the right lower abdomen and a transperitoneal approach was used to perform a total hysterectomy, BSO and pelvic lymphadenectomy. At the end of the procedure the peritoneum of the left paracolic gutter was incised to create a fenestration in order to reduce the risk of lymphocyst formation in the para-aortic region and the 12 mm fascial incision

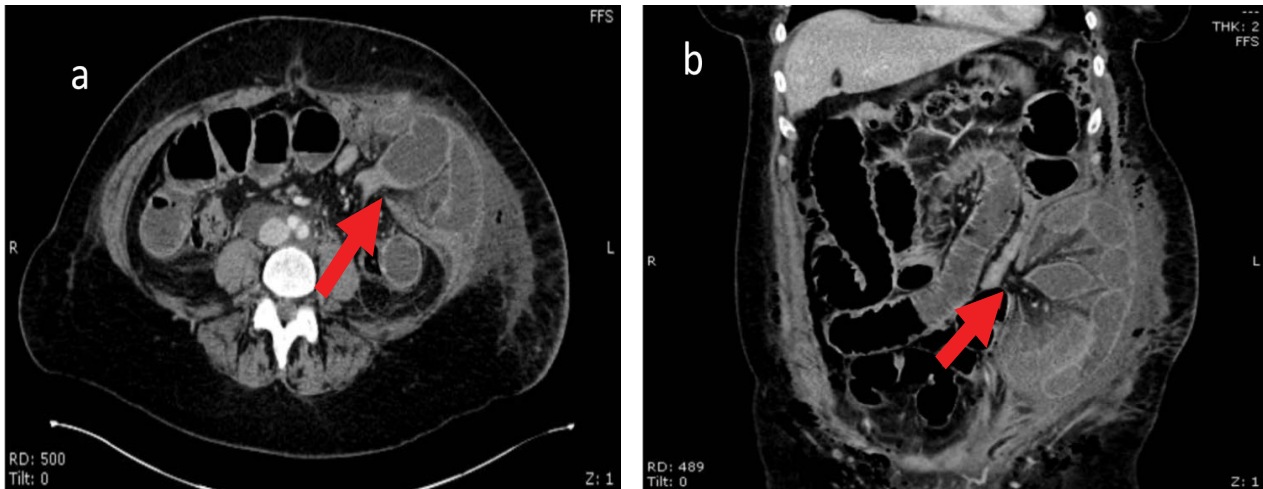


Figure 1 CT scan performed on post-operative day three for clinical indications of bowel obstruction show left extraperitoneal internal hernia. a) Transverse CT scan depicting left extraperitoneal herniation of small bowel through peritoneal defect (red arrow) with significant surrounding soft tissue inflammation and b) Coronal abdominal CT visualized incarcerated and strangulated loops of small bowel in the left extraperitoneal space through peritoneal defect (red arrow). Dilated proximal bowel loops of jejunum identified by the presence of plicae circulares proximal to bowel herniation.

was closed. The procedure was uncomplicated, and the estimated blood loss was less than 0.100 L.

On the third postoperative day, the patient was re-admitted to hospital complaining of abdominal discomfort, nausea and vomiting. Abdominal Computed Tomography (CT) scan showed several loops of small bowel herniating in the left extraperitoneal space and evidence of small bowel dilatation proximal to this point (Figures 1a and 1b). She returned to theatre and the incision at the site of the 12 mm laparoscopic ports in the left lower abdomen was extended. There was no evidence of abdominal wall hernia. However, approximately 60 cm-80 cm of small bowel was found in the left extraperitoneal space herniating through the 12 mm incision in the peritoneum. She underwent a small bowel resection and anastomosis to remove an ischaemic segment of the small bowel. The extended fascial incision and the underlying peritoneal defect were closed. Postoperative recovery was complicated by leakage of lymphatic fluid through the incision in the left lower abdomen. She was discharged home on the fourth postoperative day.

Postoperative histology showed stage 1A serous adenocarcinoma of the endometrium. There was no evidence of metastatic disease in the excised lymph nodes.

Discussion

Left extraperitoneal laparoscopic para-aortic lymphadenectomy was first described by Dargent D, et al. [11]. This approach has been shown to have several benefits over the transperitoneal route, such as shorter operating time, lower risk of adhesions formation and fewer bowel complications [12-15]. The latter can be attributed to the protective effect of the intact peritoneal sac. In addition, the procedure does not require Trendelenburg position of the patient, leading to improved respiratory compliance [16] and has been proven to be efficient even in obese patients [6].

Previous studies reported intraoperative and postoperative complication rates of 5.2%-11.7% during laparoscopic extraperitoneal para-aortic lymphadenectomy [3,17,18]. Complications mainly included visceral injury, lymphocyst formation and wound infection [3,17,18]. Internal hernia into the extraperitoneal space, as seen in this case, has not yet been reported in a patient undergoing extraperitoneal para-aortic lymphadenectomy. Preperitoneal herniation and bowel obstruction, however, have been described following laparoscopic inguinal hernia repair either using Transabdominal Preperitoneal (TAPP) or Total Extraperitoneal (TEP) approach [7-10]. During TEP procedures, the preperitoneal space is dissected and then a mesh is applied to repair the hernia defect.

Postoperative bowel herniation and obstruction may occur due to peritoneal disruption caused during the procedure, which can range between 10%-64% during TEP hernioplasty [19]. Nevertheless, the occurrence of bowel obstruction has been reported to be as low as 0.28% following these procedures [20]. In our patient, internal herniation occurred via the 12 mm port peritoneal incision which was performed in order to proceed from the extraperitoneal lymphadenectomy to the transperitoneal parts of the operation. The small bowel protruded through this incision in the newly developed extraperitoneal space which led to small bowel obstruction.

There is controversy regarding the need for closure of the peritoneal defect following laparoscopic inguinal hernia repairs, with most surgeons recommending routine closure of peritoneal tears, as they can predispose to adhesions, bowel herniation, obstruction and ischemia [21,22]. Methods of peritoneal closure, including suturing, pretied loop and endoscopic stapling, were compared by Lau H, et al. [21]. All methods were comparable with regards to outcome and safety, with staple closure being superior in terms of operative time [21].

However, Shpitz B, et al. [23] in a prospective study of 298

laparoscopic TEP hernia repairs, concluded that peritoneal tears should not be routinely closed as they did not observe any related complications during a mean follow up period of 16 months [23]. Similarly, Voeller claims that the tear is a gaping hole only if the peritoneal cavity is distended with gas and after the CO₂ is evacuated, the edges of the tear come in apposition and seal [24]. He reported no adverse sequelae, such as bowel obstructions, following 2000 TEP procedures without peritoneal defect closure [24].

It could be logically hypothesised that the size of the peritoneal defect determines the need for closure, taking into consideration the various studies suggesting the routine closure of fascial incisions \geq 10 mm. A recent systematic review of laparoscopic procedures showed that the overall prevalence of trocar-site hernia ranges between 0% and 5.2% [25], with almost 96% of trocar-site hernias occurring through ports of minimum 10 mm in size [26]. Currently, conventional gynaecologic surgical practice is closure of fascial incisions \geq 10mm, while incisions <10 mm do not require closure. Midline incisions are more likely to be complicated by hernias, due to the weakness of linea alba [27] while, paramedian incisions seem to be supported by muscle re-opposition and have been shown, in general surgery studies, not to require fascial closure, even when measuring 10 or 12 mm, when blunt trocars are used [28,29]. A possible exception to that is the arcuate line that demarcates an inherent weakness of the abdominal fascia. However, in other studies closure of fascial defects of 5 mm is also recommended where extensive and prolonged manipulation occurred that may have extended or widened the initial defect [30].

The inherent differences in tensile strength and pliability between peritoneal and fascial tissue should be appreciated when considering retroperitoneal hernias. Closure of peritoneal defects may relate differently to the defect size when compared to that of fascial closure for these reasons. The extent of para-aortic nodal dissection and the amount of tissue resected for biopsy and pathology may increase the risk for internal hernia due to formation of a large extraperitoneal space following lymphadenectomy.

Conclusion

Laparoscopic extraperitoneal para-aortic lymphadenectomy is an effective operation for staging and treating endometrial and other gynaecological cancers. We present a case of an internal hernia through the peritoneum requiring subsequent operation and bowel resection on postoperative day 3. Two possible methods could have been applied to reduce the risk of internal hernia and the subsequent bowel obstruction in our case.

Peritoneal closure, along with the fascial closure as performed, would be the first possible preventive action. On that case, the additional risks associated with laparoscopic suturing as well as the increased operative time should be considered. The alternative option could be the enlargement of the peritoneal incision to such extent that the bowel entrapment and incarceration through it would be impossible. Both strategies aim to eliminate narrow openings in the parietal peritoneal layer to decrease the chance of bowel herniation in the newly formed extraperitoneal space. In our view, every attempt should be made to ensure the prevention of such complications,

even at the expense of operating time. We recommend that these two new approaches for mitigating postoperative internal hernias should be investigated further. Otherwise, the increased morbidity and mortality associated with bowel obstruction will negate the well documented benefits of the laparoscopic extraperitoneal approach.

Data Availability

Our conclusions are supported by our case presentation, associated figures, and references cited. All references are readily accessible online.

Declaration of Competing Interest

All contributing authors declare that they have no known competing financial interests, or personal relationships pertaining to any of the work, investigations or use of clinical practices that could have appeared to influence the work presented in this report.

Credit Authorship Contribution Statement

Luc Lanteigne: Writing-Original draft preparation, Writing-Review and Editing; Chrysoula Liakou: Investigation, Methodology, Writing-Review and Editing; Nikolaos Burbos: Supervision, Conceptualisation, Methodology, Investigation, Visualisation, Writing-Review and Editing.t.

References

- 1 Raglan O, Kalliala I, Markozannes G, Cividini S, Gunter MJ, et al. (2019) Risk factors for endometrial cancer: An umbrella review of the literature. *Int J Cancer* 145: 1719-1730.
- 2 Chan JK, Cheung MK, Huh WK, Osann K, Husain A, Teng NN, et al. (2006) Therapeutic role of lymph node resection in endometrioid corpus cancer: A study of 12,333 patients. *Cancer* 107: 1823-1830.
- 3 Yoshida H, Yamamoto M, Shigeta (2020) Learning curve of laparoscopic extraperitoneal para-aortic lymphadenectomy for endometrial carcinoma: A cumulative sum analysis. *Surg Oncol* 35: 254-260.
- 4 O'Hanlan KA, Sten MS, O'Holleran MS, Ford NN, Struck DM, et al. (2015) Infrarenal lymphadenectomy for gynecological malignancies: Two laparoscopic approaches. *Gynecol Oncol* 139: 330-337.
- 5 Occelli B, Narducci F, Lanvin D, LeBlanc E, Querleu D (2000) Learning curves for transperitoneal laparoscopic and extraperitoneal endoscopic paraaortic lymphadenectomy. *J Am Assoc Gynecol Laparosc* 7: 51-53.
- 6 Dowdy SC, Aletti G, Cliby WA, Podratz KC, Mariani A (2008) Extra-peritoneal laparoscopic para-aortic lymphadenectomy: A prospective cohort study of 293 patients with endometrial cancer. *Gynecol Oncol* 111: 418-424.
- 7 McKay R (2008) Pre-peritoneal herniation and bowel obstruction post laparoscopic inguinal hernia repair: Case report and review of the literature. *Hernia* 12: 535-537.
- 8 Eugene JR, Gashti M, Curras EB, Schwartz K, Edwards J (1998) Small bowel obstruction as a complication of laparoscopic extraperitoneal inguinal hernia repair. *J Am Osteopath Assoc* 98: 510-511.
- 9 Lodha K, Deans A, Bhattacharya P, Underwood JW (1998) Obstructing

- internal hernia complicating totally extraperitoneal inguinal hernia repair. *J Laparoendosc Adv Surg Tech A* 8: 167-168.
- 10 Procter LD, Bernard A, Kearney P (2010) Strangulated appendix after Transabdominal Pre-Peritoneal (TAPP) inguinal hernia repair. *Surg Laparosc Endosc Percutan Tech* 20: 42-43.
 - 11 Dargent D, Ansquer Y, Mathevet P (2000) Technical development and results of left extraperitoneal laparoscopic paraaortic lymphadenectomy for cervical cancer. *Gynecol Oncol* 77: 87-92.
 - 12 Querleu D, Dargent D, Ansquer Y, Leblanc E, Narducci F (2000) Extraperitoneal endosurgical aortic and common iliac dissection in the staging of bulky or advanced cervical carcinomas. *Cancer* 88: 1883-1891.
 - 13 Occelli B, Narducci F, Lanvin D, Querleu D, Coste E (2000) De novo adhesions with extraperitoneal endosurgical para-aortic lymphadenectomy vs. transperitoneal laparoscopic para-aortic lymphadenectomy: A randomized experimental study. *Am J Obstet Gynecol* 183: 529-533.
 - 14 Huang M, Slomovitz BM, Ramirez PT (2017) Laparoscopic technique of para-aortic lymph node dissection: A comparison of the different approaches to trans- vs. extraperitoneal para-aortic lymphadenectomy. *Gynecol Minim Invasive Ther* 6: 51-57.
 - 15 Prodromidou A, Machairas N, Spartalis E, Kostakis ID, Iavazzo C, et al. (2018) Transperitoneal vs. extraperitoneal laparoscopic lymphadenectomy for gynecological malignancies: A systematic review and meta-analysis. *Anticancer Res* 38: 4677-4681.
 - 16 Jo YY, Kwak HJ (2017) What is the proper ventilation strategy during laparoscopic surgery? *Korean J Anesthesiol* 70: 596-600.
 - 17 Ramirez PT, Jhingran A, Macapinlac HA, Euscher ED, Munsell MF, et al. (2011) Laparoscopic extraperitoneal para-aortic lymphadenectomy in locally advanced cervical cancer: A prospective correlation of surgical findings with positron emission tomography/computed tomography findings. *Cancer* 117: 1928-1934.
 - 18 Pakish J, Soliman PT, Frumovitz M, Westin SN, Schmeler KM, et al. (2014) A comparison of extraperitoneal vs. transperitoneal laparoscopic or robotic para-aortic lymphadenectomy for staging of endometrial carcinoma. *Gynecol Oncol* 132: 366-371.
 - 19 Muzio G, Bernard K, Polliand C, Rizk N, Champault G (2006) Impact of peritoneal tears on the outcome and late results (4 years) of endoscopic totally extra-peritoneal inguinal hernioplasty. *Hernia* 10: 426-429.
 - 20 Bringman S, Blomqvist P (2005) Intestinal obstruction after inguinal and femoral hernia repair: A study of 33,275 operations during 1992-2000 in Sweden. *Hernia* 9: 178-183.
 - 21 Lau H, Patil NG, Yuen WK, Lee F (2002) Management of peritoneal tear during endoscopic extraperitoneal inguinal hernioplasty. *Surg Endosc* 16: 1474-1477.
 - 22 Felix EL, Harbertson N, Vartanian S (1999) Laparoscopic hernioplasty: Significant complications. *Surg Endosc* 13: 328-331.
 - 23 Shpitz B, Lansberg L, Bugayev N, Tiomkin V, Klein E (2004) Should peritoneal tears be routinely closed during laparoscopic total extraperitoneal repair of inguinal hernias? A reappraisal. *Surg Endosc* 18: 1771-1773.
 - 24 Lau H, Patil NG, Yuen WK, Lee F (2003) Management of peritoneal tear during endoscopic extraperitoneal inguinal hernioplasty. *Surg Endosc* 17: 1335-1336.
 - 25 Swank HA, Mulder IM, la Chapelle CF, Reitsma JB, Lange JF, et al. (2012) Systematic review of trocar-site hernia. *Br J Surg* 99: 315-323.
 - 26 Helgstrand F, Rosenberg J, Bisgaard T (2011) Trocar site hernia after laparoscopic surgery: A qualitative systematic review. *Hernia* 15: 113-121.
 - 27 Singal R, Zaman M, Mittal A, Singal S, Sandhu K, et al. (2016) No need of fascia closure to reduce trocar site hernia rate in laparoscopic surgery: A prospective study of 200 non-obese patients. *Gastroenterology Res* 9: 70-73.
 - 28 Liu CD, McFadden DW (2000) Laparoscopic port sites do not require fascial closure when non-bladed trocars are used. *Am Surg* 66: 853-854.
 - 29 Siqueira TM Jr, Paterson RF, Kuo RL, Stevens LH, Lingeman JE, et al. The use of blunt-tipped 12 mm trocars without fascial closure in laparoscopic live donor nephrectomy. *JSL* 8: 47-50.
 - 30 Yamamoto M, Minikel L, Zaritsky E (2011) Laparoscopic 5 mm trocar site herniation and literature review. *JSL* 15: 122-126.