

Respiratory Failure after Total Hip Replacement

Karen J Woittiez and
Jos Le Noble

VieCuri Medical Centre, department of
Intensive Care, Netherlands

Abstract

Following a hip replacement, a patient developed severe irreversible obstructive shock due to a fat embolism. A lung biopsy showed fat cells and bone fragments in the pulmonary capillaries.

Keywords: Total hip replacement; Obstructive shock; Fat embolism; Disseminated intravascular coagulation

Corresponding author: Woittiez KJ

✉ kwoittiez@viecuri.nl

VieCuri Medical Centre, department of
Intensive Care, Tegelseweg 2105914 BE
Venlo, Netherlands.

Tel: 31773205317

Received: August 25, 2016; **Accepted:** September 20, 2016; **Published:** September 27, 2016

Introduction

An 82 year old woman fractured her right hip after a fall. A total hip replacement was performed. The operation proceeded uneventfully; however, upon drilling for medullary pin placement, the patient became hemodynamically unstable and was transferred to the intensive care unit postoperatively.

Case Report

The patient was hypotensive, despite treatment with high vasopressor doses. Blood examination showed thrombocytopenia and prolonged clotting time. Subsequently, she became severely hypoxic and developed pulseless electrical activity, but regained cardiac output after cardiopulmonary resuscitation. Transthoracic echocardiography showed a dilated right atrium, increased rightward pressure and diastolic bulging. The patient rapidly developed irreversible obstructive shock. Supportive care was therefore discontinued, after which the patient passed away. During autopsy, extensive intrapulmonary abnormalities were observed: indicating that the capillaries contained fat cells (**Figure 1**). Our patient died from a fat embolism. We assume that bone marrow was introduced into the venous system due to increased intramedullary pressure during the drilling for femoral intramedullary pin insertion [1], as evidenced by the presence of two bone fragments in the pulmonary capillaries (**Figure 2**). The fat particles caused lung vessel congestion and secondarily an

overstressing of the right heart, which resulted in hypoxemia and acute right-sided heart failure. Furthermore, the bone marrow in the venous vessels caused considerable activation of coagulation with a decrease in thrombocytes and consumptive coagulopathy (disseminated intravascular coagulation).

Discussion

Fat embolisms are common in patients with long-bone fractures. Using a transesophageal echocardiography, they can be detected in more than 90% of patients during orthopedic surgery [2, 3]. However, it is still unclear why only a small percentage (1-3%) of these patients develops symptomatic fat embolisms [4]. Risk factors for symptomatic fat embolism are patients younger than 35 years, patients suffering from multiple injuries, and patients in whom treatment had been initiated more than 10 h after the trauma [5, 6]. Additionally, an elevated intraosseous pressure during orthopedic surgery is a well-known risk factor [7]. Finally, there is increasing evidence that the severity and incidence of symptomatic fat embolisms are decreased when prophylactic corticosteroids are administered to high-risk patients before surgery [8].

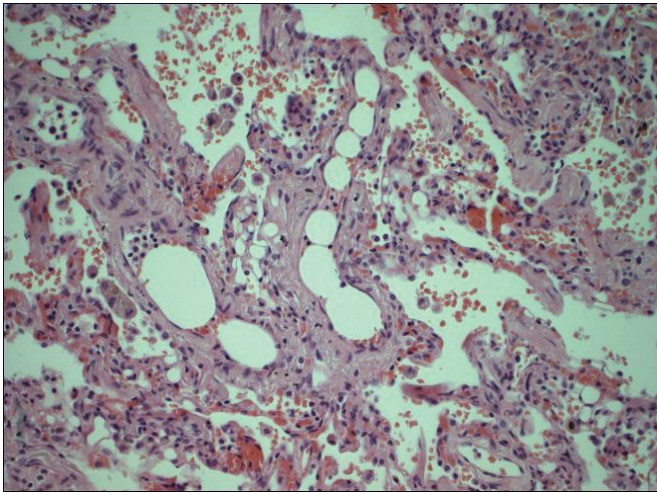


Figure 1 Lung biopsy. Capillaries filled with holes from fat cells (the fat cells themselves are dissolved during the preparation of the tissue sample), lining up in a row in the center of the image like a string of beads.

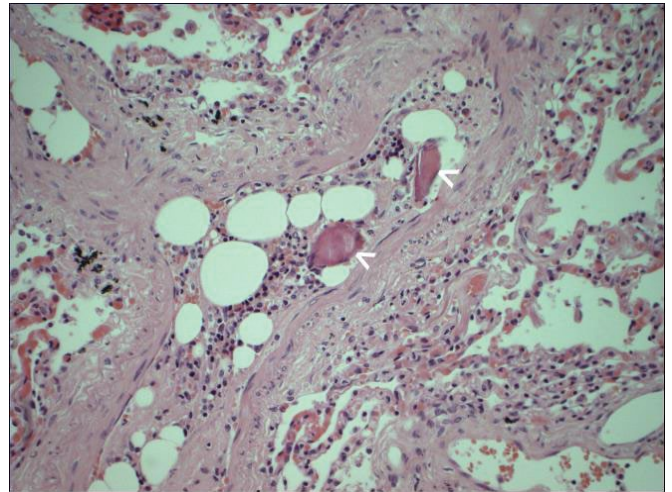


Figure 2 Lung biopsy. Pulmonary capillaries filled with fat cells and two bone fragments (pointed out by the arrows), which can be seen as irregular-shaped fragments in the capillaries.

References

- 1 Kosova E, Bergmark B, Piazza G (2015) Fat embolism syndrome. *Circulation* 131: 317-320.
- 2 Takahashi S, Kitagawa H, Ishii T (2003) Intraoperative pulmonary embolism during spinal instrumentation surgery. A prospective study using transoesophageal echocardiography. *J Bone Joint Surg Br* 85: 90.
- 3 Eriksson EA, Pellegrini DC, Vanderkolk WE, Minshall CT, Fakhry SM, et al. (2011) Incidence of pulmonary fat embolism syndrome at autopsy: an undiagnosed epidemic. *J Trauma* 71: 312.
- 4 Mueller F, Pfeifer C, Kinner B, Englert C, Nerlich M, et al. (2011) Post-traumatic fulminant paradoxical fat embolism syndrome in conjunction with asymptomatic atrial septal defect: A case report and review of the literature. *Journal of Medical Case Reports* 5: 142.
- 5 Gopinathan NR, Sen RK, Viswanathan VK, Aggarwal A, Mallikarjun HC, et al. (2013) Early, reliable, utilitarian predictive factors for fat embolism syndrome in polytrauma patients. *Indian J Crit Care Med* 17: 38-42.
- 6 Bourne MH Jr, Sekiguchi H (2016) Two patients with hypotension and respiratory distress. *Chest* 149: 41-43.
- 7 Heim D, Schlegel U, Perren SM (1993) Intramedullary pressure in reamed and unreamed nailing of the femur and tibia-an *in vitro* study in intact human bones. *Injury* 24: 56-63.
- 8 Sen RK, Tripathy SK, Krishan V (2012) Role of corticosteroid as a prophylactic measure in fat embolism syndrome: A literature review. *Musculoskelet Surg* 96: 1-8.