

## CLINICAL IMAGE

# Recurrent Epigastric Pain: Pancreatic Von Hippel–Lindau

Maddalena Zippi<sup>1</sup>, Priscilla Fina<sup>2</sup>, Wandong Hong<sup>3</sup>, Marco Fiorani<sup>4</sup>, Giuseppe Occhigrossi<sup>1</sup>

<sup>1</sup>Unit of Gastroenterology and Digestive Endoscopy, Sandro Pertini Hospital, Rome, Italy

<sup>2</sup>Unit of Radiology, Sandro Pertini Hospital, Rome, Italy

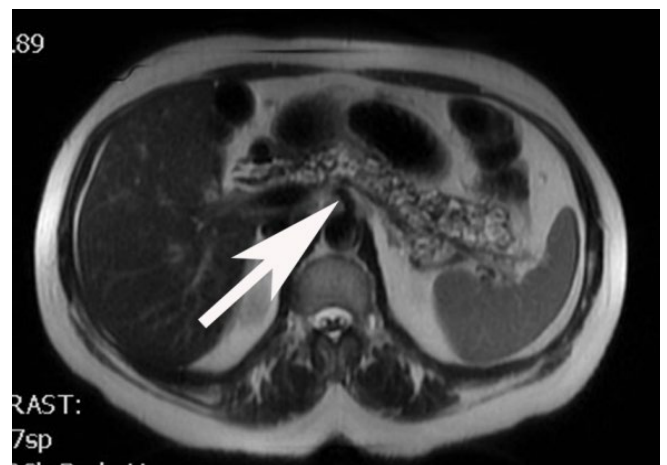<sup>3</sup>Department of Gastroenterology and Hepatology, First Affiliated Hospital of Wenzhou Medical University, Wenzhou City, Zhejiang, The People's Republic of China

<sup>4</sup>Unit of Internal Medicine, Sandro Pertini Hospital, Rome, Italy

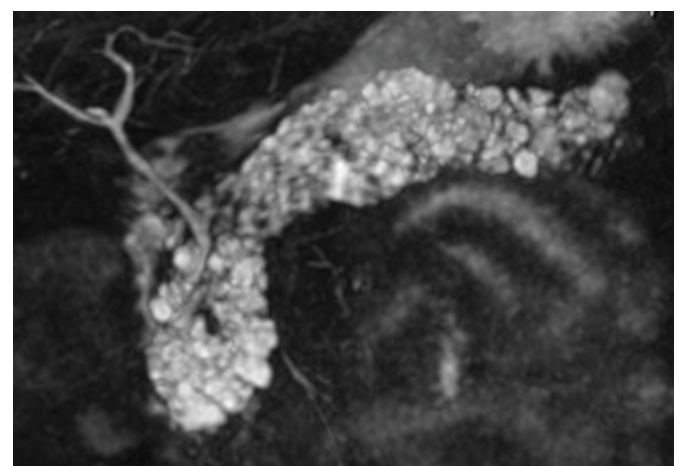
A 56-year-old woman presented recurrent episodes of epigastric pain lasted for three years. No pathological evidence came out through the gastroscopy. Given the persistence of pain, the patient underwent an ultrasound, which showed multiple pancreatic cysts. In order to get further informations, an abdominal magnetic resonance (MR) with cholangiography (MRCP) was performed. In particular, Axial T2-weighted MR image showed multiple simple cysts with size <1 cm (**Figure 1**, white arrow), which replace almost the entire pancreas, as also highlighted by the three-dimensional coronal MRCP (**Figure 2**). The hepato-pancreatic function tests, as well as the CA-19-9, were all normal, while low level of fecal elastase-1 was detected (100-200 µg/g) (Schebo® Biotech Giessen, Germany) and for this reason replacement therapy was started (25.000 IU per meal and 10.000 IU per snack) (Creon®, Abbott, Italy), with an initial symptomatic improvement. A pancreatic von Hippel–Lindau (VHL) disease was confirmed by genetic analysis for mutations of the VHL gene. No extra-pancreatic manifestations related to the underlying disease were occurring. A clinical interview was conducted, from which it emerged that the patient lost her father when he was 70 years owing to a kidney cancer. A genetic counseling has been suggested. The woman was subsequently addressed to an hepato-pancreatic center of reference for further investigations and for the definitive management.

VHL disease, a rare hereditary genetic disorder whose gene is mapped on chromosome 3, is characterized by the appearance of benign cysts and tumors in various organs tending to malignant transformation [1, 2]. Its incidence is approximately 1 in 36,000 live births [2]. It is interesting to note that in most of patients a positive family history of

the ill is registered, while up to 20% of them arise from *de novo* mutations [2]. VHL disease shows a broad spectrum of associated conditions like hemangioblastomas of the brain, spinal cord and retina, endolymphatic sac tumors, pheochromocytoma and paraganglioma, renal cysts and renal cell carcinomas (RCCs), pancreatic cysts and neuroendocrine tumors, and endolymphatic sac tumors [2, 3]. Pancreatic manifestations alone may be present in about 7.6% of patients [4] and may include three types of lesions: simple cysts,



**Figure 1.** Axial T2-weighted MR image showed multiple simple cysts with size <1 cm



**Figure 2.** The three-dimensional coronal MRCP.

Received August 30th, 2017-Accepted October 10th, 2017

**Keywords** Pancreatic Cyst; von Hippel-Lindau Disease

**Correspondence** Maddalena Zippi

Unit of Gastroenterology and Digestive Endoscopy

Sandro Pertini Hospital

Via dei Monti Tiburtini 385, 00157 Rome, Italy

**Tel** +39-06-41433310

**Fax** +39-06-41733847

**E-mail** maddyzip@yahoo.it

serous microcystic adenomas (cystadenomas) and pancreatic neuroendocrine tumors (pNETs) [3].

### Authorship

All the Authors (MZ, PF, WH, MF, GO) have participated in the work: 1) substantial contributions to conception and design, acquisition of data, or analysis and interpretation of data; 2) drafting the article or revising it critically for important intellectual content; and 3) final approval of the version to be published.

---

### Conflict of Interest

The authors declare that there is no conflict of interests regarding the publication of this paper.

---

### References

1. Charlesworth M, Verbeke CS, Falk GA, Walsh M, Smith AM, Morris-Stiff G. Pancreatic lesions in von Hippel-Lindau disease? A systematic review and meta-synthesis of the literature. *J Gastrointest Surg* 2012; 16: 1422-1428. [PMID: 22370733]
2. Varshney N, Kebede AA, Owusu-Dapaah H, Lather J, Kaushik M, Bhullar JS. A Review of Von Hippel-Lindau Syndrome. *J Kidney Cancer VHL* 2017; 4:20-29. [PMID: 28785532]
3. Van Asselt SJ, de Vries EG, van Dullemen HM, Brouwers AH, Walenkamp AM, Giles RH, et al. Pancreatic cyst development: insights from von Hippel-Lindau disease. *Cilia* 2013; 2:3. [PMID: 23384121]
4. Elli L, Buscarini E, Portugalli V, Reduzzi L, Reduzzi C, Brambilla G. Pancreatic involvement in von Hippel-Lindau disease: report of two cases and review of the literature. *Am J Gastroenterol* 2006; 101:2655-2658. [PMID: 16952288]