

## Permanent Pacemaker Assembly Infections: Piecemeal or Complete Explantation Approach?

Charan RKV\*,  
Sanzgiri P, Abhishek S,  
Rohan Thanedar R and  
Kudwa S

### Abstract

Implantable pacemakers (PM's) and cardioverter defibrillators (CD) have been accepted worldwide as the standard treatment for various nodal disease and arrhythmias. As with any invasive procedure, PM-associated complications are rare, except in patients who present late in a critically ill state with septic shock. *Staphylococcus aureus* and *Staphylococcus epidermidis* were identified as the most common organisms responsible for PM-mediated infections. Appropriate management of M-associated infection involve complete removal of the generator and leads, regardless of the extent and location of the infection. Explantation of the complete PM system has also proven to be one of the most reliable methods to eradicate PM infection. In this study, we report the clinical course of an elderly female who underwent permanent pacemaker implantation (PPI) for complete heart block (CHB) and later developed complications during PM upgradation.

**Keywords:** Pacemaker infection; Complete heart block; Endocarditis; Cardiac implantable electronic device

**Received:** February 15, 2018, **Accepted:** February 22, 2018, **Published:** February 28, 2018

### Introduction

Cardiovascular implantable electronic devices (CIEDs) were introduced into routine clinical use in the 1960's to protect against sudden cardiac death. Cardiac device-associated infection is a rare complication following pacemaker insertion. Recent reports revealed that worldwide implantation rates of CIED as estimated at 1,250,000 pacemakers and 410,000 cardioverter defibrillators per year, with an annual increase of roughly 5% [1,2]. The use of these devices has raised steadily and with it also the rate of cardiac device infections (CDI). Complications related to pacemaker implantation could be related to surgical, hardware, software or device malfunction, leading to failure to pace, failure to sense, pulse generator failure and pacemaker mediated tachycardia. In clinical practice CDIs can be classified as isolated pocket infection, bloodstream infection and cardiac device related infective endocarditis (CDRIE). Isolated pocket infection is the most frequent, accounting for more than half of CDIs [2,3]. Device related infection is associated with substantial morbidity ranging from 8% in those with complete device removal, or up to 46% in whom the device is only partially explanted [4].

In patients with implanted cardiac pacemakers, the most common

entry port for bacteria into the bloodstream is the subcutaneously located generator pocket. Eighty percent of infections involving pacemakers are caused by methicillin-resistant *Staphylococcus aureus* (MRSA), and coagulase-negative staphylococci. Gram-negative bacilli, such as *Escherichia coli* and *Serratia marcescens*, *Pseudomonas aeruginosa*, *Klebsiella pneumoniae*; fungi such as *Candida albicans*, *Torulopsis glabrata*, and *Aspergillus* species [1,4]. Around half of these are due to *Staphylococcus* infections [5].

Amongst all cardiac device infections, the pocket infection is the most challenging. The infection originating from the pocket often tracks along the lead to cause seeding of the entire assembly often leading to systemic complications. The clinical presentation of pacemaker infection is highly variable and treatment of device infections varies according to the location and extent of infection and the clinical characteristics of the patient [6]. Infections involving the generator pocket are often accompanied by fever, chills while pacemaker endocarditis is associated with new murmur caused by regurgitation or a change in a pre-existing murmur, leucocytosis, splenomegaly, anaemia, and microscopic hematuria [7].

Department of Interventional Cardiology,  
Lilavati Hospital & Research Centre, Bandra,  
Mumbai

**Corresponding author:** Charan RKV

✉ chrnr@rediffmail.com

Department of Interventional Cardiology,  
Lilavati Hospital & Research Centre, Bandra,  
Mumbai

**Tel:** +91(22)26407655

**Citation:** Charan RKV, Sanzgiri P, Abhishek S, Thanedar RR, Kudwa S (2018) Permanent Pacemaker Assembly Infections: Piecemeal or Complete Explantation Approach? Cardiovasc Investig. Vol.2 No.1:2

## Case Report

A 60 years old female not a known case of diabetes mellitus (DM) or hypertension (HTN) underwent permanent pacemaker implantation (PPI) for complete heart block (CHB). It was a cardiac implantable electronic device (CIED), a VVI pacemaker implanted through right subclavian vein (SCV) and generator or battery was placed into a subcutaneous pocket created in the right infra-clavicular region.

The patient started developing giddiness and syncope within 2 years post pacemaker implantation. The ECG findings were suggestive of pacemaker output failure most likely due to lead displacement or fracture. The pacemaker was converted into a unipolar mode and the damaged lead was replaced. She was asymptomatic for next 6 yrs and towards the end-of-battery life, given the option of upgrading the pacemaker to newer dual chamber (DDDR) type.

Two weeks after upgrading the pacemaker to DDDR type, she started experiencing fever with chills and discharge from pocket site (**Figures 1A and 1B**). Cultures of discharge grew polymicrobial flora of *Acinetobacter baumannii* and non-fermenting Gram –ve bacilli like *Stenotrophomonas maltophilia*, *Burkholderia cepacia* and *Sphingomonas paucimobilis*.

Under antibiotic cover, the generator or battery and the whole pocket on the Right side was excised leaving the leads behind. Venogram results revealed a normal bilateral venous system. Temporary pacing lead was placed from the Left internal jugular vein and right ventricle paced with an external pacemaker to tide over the crisis. The same pulse generator was Re-sterilized, downgraded to VDD type and implanted into the Left infra clavicular pocket a day later. She was asymptomatic for about 10 days, then she started complaining of fever with chills, and swelling with discharge from the left pocket site (**Figure 1C**).

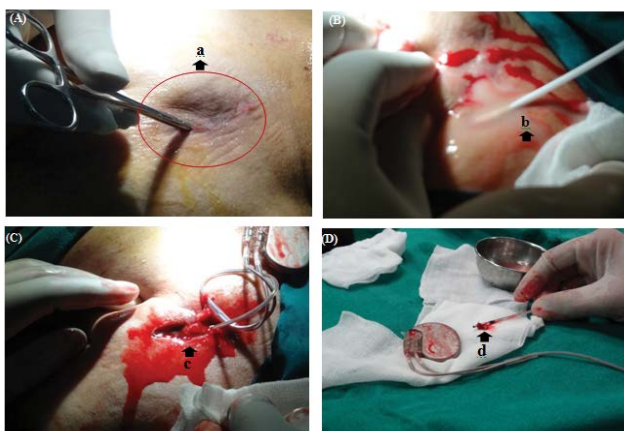
Blood cultures were positive for *Burkholderia cepacia* and pus cultures from generator site were positive for *Acinetobacter baumannii*. Antibiotic treatment started with linezolid and colistin (polymyxin E), which are effective against most Gram-negative bacilli including *Staphylococcus hemolyticus*.

A venogram now showed B/L internal jugular vein (IJV) thrombosis, filling defect in the left subclavian vein and interruption of right (RT) subclavian vein at its junction with the superior vena cava (SVC). The left pocket was excised and whole pacemaker assembly removed along with the leads (**Figure 1D**). The pacemaker electrode was placed surgically after a sternotomy and subcutaneous tunnelling to give epicardial stimulation and a pocket was created for generator was created in upper abdomen. In spite of our best efforts, her condition continued to deteriorate, and she died as a result of septic shock with multiple organ failure.

## Discussion

Endocarditis related to pacemaker lead infection is a rare but serious complication of permanent transvenous pacing [1]. Implantation of devices to treat heart failure or prevent arrhythmias have increased over the years due to the fact that younger patients are receiving CIEDs and therefore surviving long enough to require more pulse generator changes and lead revisions, which are associated with a higher infection rate. These infections are associated with severe morbidity and mortality; high treatment costs and long hospital stay [1]. In a systematic review by Baddour et al. [6] reported that incidence of pacemaker-associated infection constitute about 0.13 to 0.19%. Recently Boyle et al. [8] reported pacemaker endocarditis related infections constitute about 10% of all endocarditis cases in the western countries. In an observational retrospective study of 8303 pacemaker insertions, 0.5% of all insertions were associated with pacemaker endocarditis [9]. In another retrospective study conducted by residents of Olmsted County, Minnesota, USA, between 1975-2004, reported the incidence of infection was higher for an ICD device, than for a pacemaker: (0.9 versus 1.0 per 1000 device-years) [10]. Nery et al. [11] in a prospective study conducted between 2005 and 2007 reported that, out of 2417 patients who had a cardiac device inserted, 24 patients (1%) developed device-related infection. In a case series of 118 patients with device-associated endocarditis, 14.3% grew *Staphylococcus aureus* from cultures taken from the leads.

Our patient had a history of multiple interventions. First, implantation of VVI pacemaker. Next, lead replacement due to fractured electrode which leads to increased impedance. This was followed by upgradation to dual chamber pacemaker, using same ventricular electrode. Subsequent infection to the pacemaker assembly leads to unfortunate turn of events. The pacemaker device was explanted and same device was re-implanted after sterilisation on the opposite side via the left subclavian vein puncture. It was not surprising that the device showed infection again because, any infection in the pacemaker pocket extends to the venous channels, resulting in thrombophlebitis, and thereafter extends to the endocardial surface of valves and may manifest as infective endocarditis and vegetation on tricuspid or pulmonary valves. There is conclusive evidence that if effective treatment is



**Figure 1** (A) Infection following upgradation of pacemaker to DDDR type; (B) Purulent discharge from the pocket site on right side; (C) Infection following implantation of re-sterilized generator on the left side; (D) Complete explantation of pacemaker assembly. (a: infection/flammation area; b: purulent discharge; c: implantation of generator and d: explantation of pacemaker).

desired complete device removal is mandatory. Extraction of all hardware is now recommended in all cases of pocket infection and endocarditis, regardless of whether or not there is definite evidence lead involvement. Not only were repeat infection rates low in patients who had devices removed regardless of the timing of reimplantation. Hence, obviously, removal and replacement of device with extraction of electrode followed by two weeks of targeted antibiotic therapy and negative blood cultures 72 hrs prior to re-implantation should be the most scientific approach.

Pocket infection, lead infection and valve endocarditis can frequently coexist. Non-specific signs and symptoms of systemic infection may be the only clinical features. Many years ago, Lee et al. [12] has reported that successful treatment of pocket infections without removal of the entire pacemaker assembly system. Back in 1986, at the dawn of extraction techniques, Hurst et al. [13] published the data on 19 patients with pacemaker pocket infection that were successfully treated by debridement and local closed irrigation without hardware removal.

CIED infections have a varied presentation. They can present as febrile illness, pacemaker pocket inflammation, discharge from wound, abscess, erosion of part of pacemaker through skin, endocarditis of the leads, tricuspid valve endocarditis with regurgitation or rarely pulmonary embolism. To make diagnosis of CIED infection, one requires a high index of suspicion. It requires clinical awareness; careful patient history assessment, precise physical examination and a basic workup (i.e., blood cultures, transthoracic and transoesophageal echocardiography). Use of C-reactive protein (CRP) and procalcitonin assessment can aid in diagnosis especially in blood culture negative cases [14].

## References

- 1 Usulan DZ, Gleva MJ, Warren DK, Mela T, Chung MK, et al. (2012) Cardiovascular implantable electronic device replacement infections and prevention: results from the REPLACE Registry. *Pacing Clin Electrophysiol* 35: 81-87.
- 2 Brignole M, Auricchio A, Baron-Esquivias G, Bordachar P, Boriani G, et al. (2013) ESC Guidelines on cardiac pacing and cardiac resynchronization therapy: the Task Force on cardiac pacing and resynchronization therapy of the European Society of Cardiology (ESC). Developed in collaboration with the European Heart Rhythm Association (EHRA). *Eur Heart J* 34: 2281-2329.
- 3 Tarakji KG, Wazni OM, Harb S, Hsu A, Saliba W, et al. (2014) Risk factors for 1-year mortality among patients with cardiac implantable electronic device infection undergoing transvenous lead extraction: The impact of the infection type and the presence of vegetation on survival. *Europace* 16: 1490-1495.
- 4 Cacoub P, Leprince P, Hounsfater P, Doroub R, Weckslers B, et al. (1998) Pacemaker infective endocarditis. *Am J Cardiol* 82: 480-484.
- 5 Khaldoun GT, Christopher RE, Pascal D, Charles KC (2016) Cardiac implantable electronic device infection in patients at risk. *Arrhythmia & Electrophysiology Review* 5: 6-71.
- 6 Baddour LM, Cha YM, Wilson WR (2012) Clinical practice. Infections of cardiovascular implantable electronic devices. *N Engl J Med* 367: 842.
- 7 Wilkoff BL, Love CJ, Byrd CL, Bongiorni MG, Carrillo RG, et al. (2009) Transvenous lead extraction: Heart Rhythm Society expert consensus on facilities, training, indications, and patient management: this document was endorsed by the American Heart Association (AHA). *Heart Rhythm* 6: 1085-1104.
- 8 Boyle TA, Usulan DZ, Prutkin JM, Greenspon AJ, Baddour LM, et al. (2017) Reimplantation and repeat Infection after Cardiac implantable Electronic Device Infections Experience from the MEDIC (Multicenter Electrophysiologic Device Infection Cohort) Database. *Circ Arrhythm Electrophysiol* 10: e004822.
- 9 Arber N, Pras E, Copperman Y, Schapiro JM, Meiner V, et al. (1994) Pacemaker endocarditis. Report of 44 cases and review of the literature. *Medicine (Baltimore)* 73: 299.
- 10 Usulan DZ, Sohail MR, St Sauver JL, Friedman PA, Hayes DL, et al. (2007) Permanent pacemaker and implantable cardioverter defibrillator infection: a population-based study. *Arch Intern Med* 167:669-675.
- 11 Nery PB, Fernandes R, Nair GM, Sumner GL, Ribas CS, et al. (2010) Device-related infection among patients with pacemaker and implantable defibrillators: incidence, risk factors, and consequences. *J Cardiovasc Electrophysiol* 21: 786-790.
- 12 Alperstein A, Fertig RM, Feldman M, Watford D, Nystrom S, Delva G, et al. (2017) Septic thrombophlebitis of the internal jugular vein a case of Lemierre's syndrome. *Intractable Rare Dis Res* 6:137-140.

- 13 Lee JH, Geha AS, Murthy RN, Brian L, Cmolik BL, et al. (1996) Salvage of infected ICDs: Management without removal. *Pacing Clin Electrophysiol* 19: 437-442.
- 14 H14. Hurst LN, Evans HB, Windle B, Klein GJ (1986) The salvage of infected cardiac pacemaker pockets using a closed irrigation system. *Pacing and Clinical Electrophysiology* 9: 785-792.
- 15 Kumar A and Agrawal T (2014) A study of unusual pacemaker infection by *Mycobacterium tuberculosis* in Indian Patients. *Indian Pacing Electrophysiol J* 14: 291-296.
- 16 Lennerz C, Vrazic H, Haller B, Braun S, Petzold T, et al. (2017) Biomarker-based diagnosis of pacemaker and implantable cardioverter defibrillator pocket infections: A prospective, multicentre, case-control evaluation. *PLoS ONE* 12: e0172384.
- 17 Natarajan A, Hindocha D, Kular N, Fergey S, Davies JR (2012) Vasculitic rash: Do not jump to conclusions. *Clin Med* 12: 179-180.