

CASE REPORT

Pancreatic Metastasis of an Ovarian Malignant Mixed Mullerian Tumor Identified by EUS-Guided Fine Needle Aspiration and Trucut Needle Biopsy

Rogelio G Silva, Laila Dahmouh, Henning Gerke

Division of Gastroenterology and Hepatology, Department of Medicine
and Department of Pathology, University of Iowa Hospitals and Clinics. Iowa City, Iowa, USA

ABSTRACT

Context Malignant mixed Mullerian tumors are rare ovarian neoplasms that account for less than 2% of ovarian malignancies. They have a generally poor prognosis and often develop recurrent disease. To our knowledge, this is the first report of a malignant mixed Mullerian tumor with metastasis to the pancreas. The metastatic tumor was identified by endoscopic ultrasound guided fine needle aspiration (EUS-FNA) and Trucut needle biopsy of the pancreas.

Case report We describe a 69-year-old female with concomitant Duke's C adenocarcinoma of the colon and stage III-C malignant mixed Mullerian tumor that presented with malignant ascites, increasing abdominal girth and a pancreatic head mass. EUS revealed an 11 cm cystic mass in the head of the pancreas that was characterized as a carcinosarcoma/malignant mesodermal mixed tumor by EUS-FNA and Trucut needle biopsy. The tumor was morphologically identical to the surgical specimen of her ovarian mass. The patient was treated with palliative chemotherapy and a three-month follow up CT scan did not reveal any new metastatic lesions.

Conclusion The pancreas is a rare site of metastasis and more commonly seen in renal

cell carcinoma, melanoma or lung tumors; amongst others. Although ovarian adenocarcinoma has been reported as a primary site of pancreatic metastasis, it has not been previously described originating from a mixed Mullerian tumor of the ovary presenting as a cystic pancreatic head mass.

INTRODUCTION

Malignant mixed Mullerian tumors are the second most common type of uterine sarcoma but are a rare cause of ovarian malignancy (less than 2%). They are generally responsive to chemotherapy but have a poor prognosis and often develop recurrent disease [1, 2, 3]. We report a case of a malignant mixed Mullerian tumor of the ovary with metastasis to the pancreas confirmed by EUS fine needle aspiration. To our knowledge, no other case has been reported in the literature.

CASE REPORT

We present a 69-year-old female with a prior history of stage III-C malignant mixed Mullerian tumor and Duke Classification C adenocarcinoma of the sigmoid colon who was referred to the endosonography service for the evaluation of a pancreatic mass. The patient had both malignancies diagnosed simultaneously 4 years earlier and had been

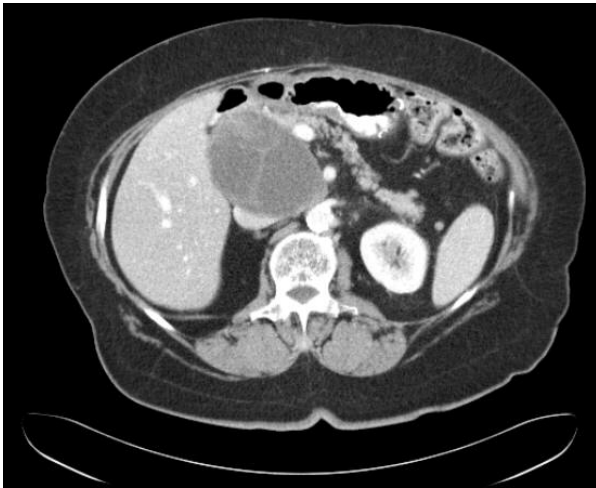


Figure 1. Contrast enhanced CT of the abdomen revealing a 7.3x9.4 cm septated mass in the area of the head of the pancreas with distortion of the normal anatomy.

treated with surgical resection including bilateral salpingo-oophorectomy, hysterectomy, omentectomy, liver wedge resection and sigmoid colectomy with colostomy. The patient's initial symptoms were increasing abdominal girth and she had been found to have malignant ascites at the time of her evaluation. CT scan of the abdomen revealed normal ovaries but a barium study revealed an apple-core lesion in the sigmoid colon. During surgical resection, an 8 cm right ovarian mass was identified as well as peritoneal seeding with metastasis to the greater omentum. Another tumor was identified in the sigmoid colon and near the area of the gallbladder bed consistent with Mullerian tumor metastasis. She was subsequently treated with 6 cycles of carboplatin and taxol. Multiple peritoneal biopsies at the time of colostomy take down 6 months later as well as follow up colonoscopies failed to reveal recurrent disease. Yearly CT scans of the abdomen had been unremarkable until 4 years later when CT revealed a 7.3x9.4 cm complex cystic mass in the area of the head of the pancreas (Figure 1). EUS was performed and revealed an 11 cm cystic mass in the area of the head of the pancreas with thick septations and a solid-appearing area (Figure 2). Both fine needle aspiration and Trucut core biopsies were performed. Microscopic examination of

the fine-needle aspiration material showed cohesive clusters of highly atypical hyperchromatic spindle cells embedded in a myxoid matrix (Figure 3a). Identical cells and background were noted in the concurrent Trucut biopsy (Figure 3b). Review of the patient's previously diagnosed ovarian tumor showed a carcinosarcoma/malignant mesodermal mixed tumor (MMMT) with the sarcomatous component being morphologically identical to the tumor cells noted in the aspirate and biopsy (Figure 3c). Interestingly, the metastatic tumor was exclusively composed of the sarcomatous component. She is currently receiving repeat chemotherapy with carboplatin and taxol. Repeat CT scan of the abdomen 3 months later did not demonstrate new metastatic lesions or change in the pancreatic mass. The patient is alive and tolerating her chemotherapy well.

DISCUSSION

Metastasis to the pancreas is rare. In one study of 1,050 pancreatic FNA specimens of intraparenchymal lesions, only 3.8% were due to metastatic tumor in the pancreas [4]. Pancreatic metastases are more commonly reported in patients with renal cell carcinoma or melanoma but other causes have included lung, breast, colon, hepatic or gastric carcinomas [5, 6, 7]. The pancreatic head is

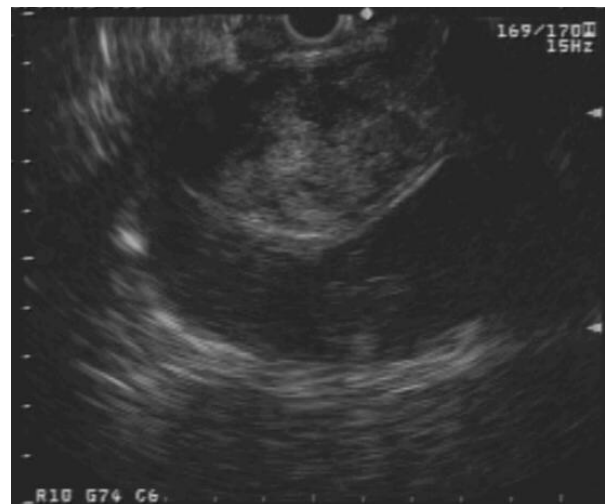


Figure 2. Linear array endosonographic image of a large cystic mass in the head of the pancreas with heterogeneous solid area.

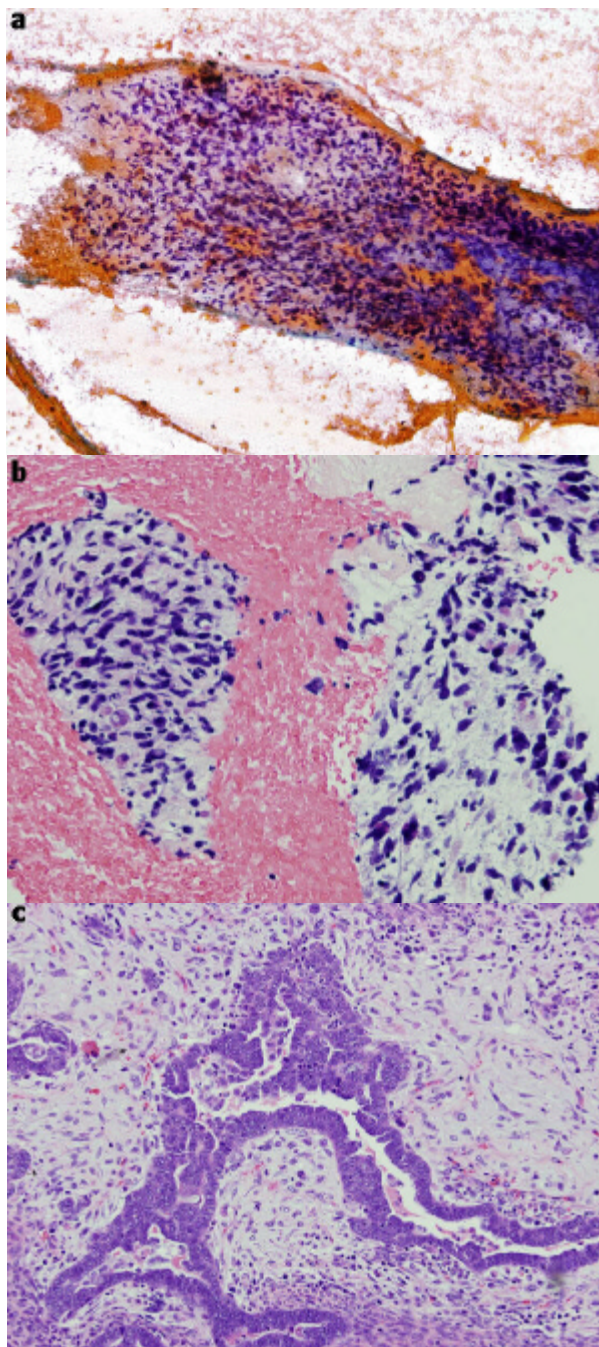


Figure 3. **a.** Pancreatic FNA: cluster of highly atypical hyperchromatic spindle cells noted in a myxoid background (Papanicolaou stain). **b.** Pancreatic biopsy: clusters of hyperchromatic spindle cells noted in a myxoid background (H&E stain). **c.** Ovarian tumor: carcinosarcoma/ malignant mesodermal mixed tumor (MMMT) with serous carcinoma in the center, surrounded by spindle cells myxoid sarcoma (H&E stain).

the most common site of metastasis [4]. Schumacher described one case of ovarian adenocarcinoma metastasis to the pancreas in 1993 [8]. Our case describes a rare malignancy causing an even rarer metastatic

lesion to the pancreas. Malignant mixed Mullerian tumors are generally considered to have a poor prognosis and often have wide metastasis at the time of diagnosis [3]. As in our case, the pancreas cannot be excluded as a potential site of distant metastasis and may mimic a cystic neoplasm of the pancreas.

Received October 10th, 2005 - Accepted November 24th, 2005

Keywords Endosonography; Mixed Tumor, Mullerian; Neoplasm Metastasis; Pancreas

Abbreviations MMT: malignant mesodermal mixed tumor

Correspondence

Rogelio G Silva, Jr
Division of Gastroenterology and Hepatology
Department of Medicine
University of Iowa, Hospital and Clinics
200 Hawkins Drive, JCP 4544
Iowa City
Iowa 52242
USA
Phone: +1-319.356.2709
Fax: +1-319.353.6399
E-mail: rogelio-silva@uiowa.edu

References

1. Brown E, Stewart M, Rye T, Al-Nafussi A, Williams AR, Bradburn M, et al. Carcinosarcoma of the ovary: 19 years of prospective data from a single center. *Cancer* 2004; 100:2148-53. [PMID 15139057]
2. Kahanpaa KV, Wahlstrom T, Grohn P, Heinonen E, Nieminen U, Widholm O. Sarcomas of the uterus: a clinicopathologic study of 119 patients. *Obstet Gynecol* 1986; 67:417-24. [PMID 3945454]
3. Le T, Krepart GV, Lotocki RJ, Heywood MS. Malignant mixed mesodermal ovarian tumor treatment and prognosis: a 20-year experience. *Gynecol Oncol* 1997; 65:237-40. [PMID 9159331]
4. Volmar KE, Vollmer RT, Jowell PS, Nelson RC, Xie HB. Pancreatic FNA in 1000 cases: a comparison of imaging modalities. *Gastrointest Endosc* 2005; 61:854-61. [PMID 15933687]
5. DeWitt J, Jowell P, Leblanc J, McHenry L, McGreevy K, Cramer H, et al. EUS-guided FNA of

pancreatic metastases: a multicenter experience. *Gastrointest Endosc* 2005; 61:689-96. [PMID 15855973]

6. Robbins EG 2nd, Franceschi D, Barkin JS. Solitary metastatic tumors to the pancreas: a case report and review of the literature. *Am J Gastroenterol* 1996; 91:2414-7. [PMID 8931428]

7. Wente MN, Bergmann F, Frohlich BE, Schirmacher P, Buchler MW, Friess H. Pancreatic metastasis from gastric carcinoma: a case report. *World J Surg Oncol* 2004; 2:43. [PMID 15585066]

8. Schumacher A. Delayed diagnosis of ovarian cancer with metastasis to the pancreas. *Zentralbl Gynakol* 1993; 115:568-9. [PMID 8147172]
