

CASE REPORT

A Case Report of Uncommon Frank Fistulous Communication between Liver Hydatid Cyst and Gallbladder

Mohamed Ali Chaouch, Meryam Mesbahi, Mossab Ghannouchi, Jihed Rebhi, Ramine Sboui, Yassine Tlili, Mohamed Taha Abdelkafi, Karim Nacef, Moez Boudokhane

Department of General Surgery, Tahar Sfar Hospital, Mahdia, Tunisia

ABSTRACT

Introduction Liver hydatid cyst and the gallbladder fistulous communication are rare. We report a case of a cholecysto-hydatid cyst fistula discovered by acute pancreatitis. **Case presentation** A 38-year-old woman presented for acute pancreatitis. Ultrasonography objectified a downsizing gallbladder due to a compression by a multi-vesicular hydatid-cyst. Abdominal CT-scan found an acute pancreatitis stage B with a thick-walled multi-located hepatic cyst lesion and suggests the presence of many daughter cysts in the gallbladder lumen. Intra-operatively, we found a large liver hydatid cyst with close adhering to the gall bladder. Lagrot's procedure was adopted. During the cholecystectomy, a fistulous communication between the liver hydatid cyst and the gallbladder was found with presence of daughter cysts in the gallbladder. **Conclusion** Cholecysto-hydatid cyst communication could be discovered by several complications such as acute pancreatitis. This complication should be predicted preoperatively, checked intraoperatively, and well managed postoperatively in case of residual cystic cavity related complications.

INTRODUCTION

Hydatid cyst is a worldwide zoonosis caused by *Echinococcus granulosus* [1]. It affects essentially the liver [1]. The most frequent complication of liver hydatid cyst is intrabiliary rupture [2]. It presents the cornerstone of hydatid disease evolution and it may lead to acute cholecystitis, acute cholangitis owing to obstruction of the biliary tree, or even acute pancreatitis [2]. However, its occurrence between a liver hydatid cyst and the gallbladder is uncommon. Early diagnosis of this form of frank intrabiliary fistula and treatment remains mandatory to avoid life-threatening complications. The aim of this work is to report an uncommon complication of hydatid disease: cholecysto-hydatid cyst frank fistula, discovered by acute pancreatitis.

CASE PRESENTATION

A 38-year-old woman, from a rural region with a past medical history of intermittent right upper quadrant pain, presented for an epigastric pain for 3 days with no fever or jaundice. Physical examination revealed epigastric tenderness. The rest of the clinical examination was unremarkable. Biological data showed a high lipase blood level at 26 times the normal values,

Alanine aminotransferase (ALT) was at 204 UI/l, aspartate aminotransferase (AST) was at 210 UI/l, and increased serum total bilirubin (92.9 $\mu\text{mol/l}$; normal range, 3–17 $\mu\text{mol/l}$). The diagnose of acute pancreatitis was retained. Abdominal ultrasonography was performed. It objectified a downsizing gallbladder due to a compression by a multi-vesicular cystic lesion of 85 × 50 mm with a heterogeneous echogenic interior. This cyst is located in segments IV, V, and VII suggesting a hydatid cyst type III (Gharbi's classification). There was no biliary stones nether bile duct dilation. The abdominal CT-scan objectified an acute pancreatitis stage B of Balthazar with a thick-walled multi-located hepatic cyst lesion. There were many endogenous and exogenous daughter cysts. The largest one was of 70 × 80 mm localized in the segments IV, V, and VI. It suggests also the presence of daughter cysts in the gallbladder lumen (**Figure 1**). Then, the diagnosis of cholecysto-hydatid cyst complicated by an acute pancreatitis was retained. A broad-spectrum antibiotic (cephalosporin 3 g/day) was used and the patient was put on oral Albendazole (10 mg/kg/day) for 4 days before surgery. Intra-operatively, under general anesthesia using a right subcostal incision, we found a large liver hydatid cyst of segment IV closely adhering to the gall bladder. The gall bladder was tense with edematous wall. Conservative treatment for the liver hydatid cyst was retained. Lagrot's procedure was adopted. The aspiration of the cyst content brings an infected fluid with multiple endogenous daughter cysts. Regarding the preoperative liver biological data perturbation, a cholecystectomy and intraoperative cholangiography were performed. During cholecystectomy, a fistulous communication about one centimeter between the liver hydatid cyst and the gallbladder was found with presence of daughter cysts in the gallbladder (**Figure 2**). The intraoperative cholangiography was

Received September 04th, 2019 - Accepted October 18th, 2019

Keywords Echinococcosis; Hepatic; Gallbladder; Fistula; Communication

Abbreviations ALT alanine aminotransferase; AST aspartate aminotransferase

Correspondence Mohamed Ali Chaouch

Department of General Surgery, Tahar Sfar Hospital, Mahdia, Tunisia

Tel +21626206105

Fax +21626206105

E-mail docmedalichaouch@gmail.com

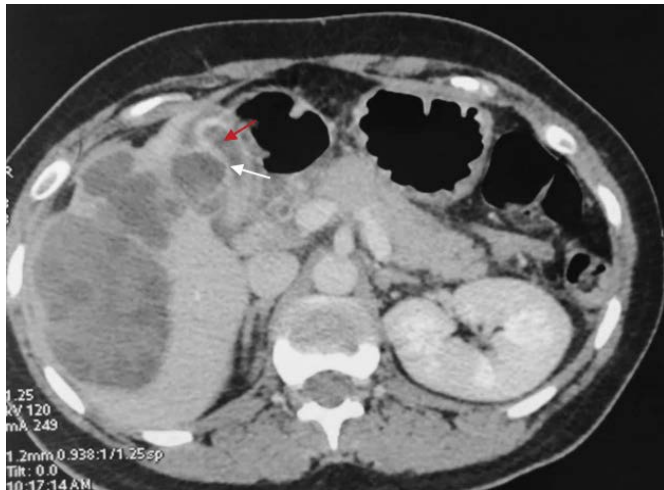

Figure 1. Coronal abdominal CT-scan picture showing a multi-located hepatic cyst lesion with many endogenous daughter cysts and exogenous daughter cysts adhering to the gallbladder (white arrow). Presence of daughter cysts in the gallbladder lumen (red arrow).

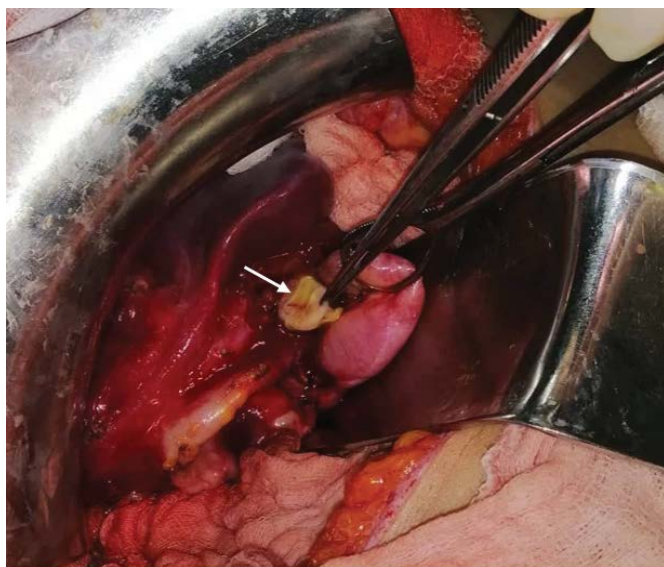


Figure 2. Intraoperative view showing the extraction of hydatid daughter cysts (white arrow) through the communication between the gallbladder and the liver hydatid cyst.

normal. After checking the absence of any other cysto-biliary communication, omentum was mobilized and placed to obliterate the residual cavity. The postoperative delay was uneventful. The patient was examined in the outpatient clinic, no liver hydatid cyst recurrence found after 6 months of follow-up.

DISCUSSION

Intrabiliary hydatid cyst rupture is the most frequent complication of liver hydatid cysts and there is no consensus concerning the terminology of hydatid cyst with intrabiliary rupture [2]. Its incidence depends largely on the definition used to retain the occurrence of this rupture. It interests the right duct in 55 %, the left duct 25% and rarely the gallbladder [3] these cysts were generally asymptomatic until they were complicated [4]. Intracystic pressure increases along with the diameter of a hydatid cyst and lead to a spontaneous intrabiliary rupture [5]. These abnormal communications were boosted by cyst

infection [5]. This pressure causes intermittent passage of cyst fluid and minor fragments into the biliary system. It leads to cyst infection, cholangitis, sepsis, jaundice, pancreatitis, acute cholecystitis, liver abscesses, and adjacent organs fistula [5]. This cysto-biliary fistula may occur essentially in two forms: an occult rupture in 10% to 37% of cases or a frank rupture in 3% to 17% of cases [2, 6]. Generally, the frank intrabiliary rupture is easily suggested preoperatively. Careful past medical history, patient story, physical examination and complementary exams predict this complication [5, 6]. There were essentially obstructive jaundice, hyperbilirubinemia, high gamma-glutamyl transferase level and high alkaline transferase in the blood samples [6]. In our case, a frank cholecysto-hydatid cyst rupture has occurred. Presence of daughter cysts in the gallbladder lumen was suggested by the imaging features and it was confirmed intra-operatively. They were enclosed, in the gallbladder, without crossing over the cystic duct to achieve the common bile duct. In our case, it was the cause of an acute pancreatitis.

In these cases, CT-scan and ultrasound present useful diagnostic tools [6]. The only direct sign of cysto-biliary rupture is the visualization of a cyst wall defect or communication between the cyst and a biliary radicle [7]. The abdominal ultrasound had a sensitivity of 66.7% and a specificity of 100% [6]. Concerning abdominal CT-scan, it detects 75% of major cysts rupture [7]. These imaging features may identify the daughter cysts within the biliary tree [8]. Often this complication is discovered intra-operatively proved by bile in the hydatid cyst fluid [5]. In the present case, CT-scan have suggested the presence of cholecysto-hydatid cyst communication and the diagnose was confirmed after finding hydatid daughter cysts in the gallbladder lumen. Magnetic resonance cholangiography may become an effective diagnostic tool. It was not performed I our case. In our days, it is yet to be defined in the assessment of hydatid cyst intrabiliary rupture [9]. Surgeons should suspect this complication preoperatively. A broad-spectrum antibiotic should be chosen and patients should be treated surgically as early as possible [10]. In addition, when intrabiliary rupture is suspected, percutaneous drainage and use of scolicial agents should be avoided [2, 5]. In our case, a conservative treatment was adopted: Largo's procedure [11]. This procedure consists in a resection of the prominent dome of the liver hydatid cyst and eliminates the parasites using a scoliosis solution (saline serum).

CONCLUSION

Cholecysto-hydatid cyst communication is extremely rare. Often, it could be discovered by several complications such as acute pancreatitis. This abnormal communication should be predicted preoperatively and checked intraoperatively.

Acknowledgements

There were no acknowledgements to mention it.

Conflicts of Interest

The authors declare no competing interest.

REFERENCES

1. Dziri C, Haouet K, Fingerhut A, Zaouche A. Management of cystic echinococcosis complications and dissemination: where is the evidence? *World J Surg* 2009; 33:1266-1273. [PMID: 19350321]
 2. Kayaalp C, Bostanci B, Yol S, Akoglu M. Distribution of hydatid cysts into the liver with reference to cystobiliary communications and cavity-related complications. *Am J Surg* 2003; 185:175-179. [PMID: 12559452]
 3. Kumar R, Reddy SN, Thulkar S. Intrabiliary rupture of hydatid cyst: diagnosis with MRI and hepatobiliary isotope study. *Br J Radiol* 2002; 75:271-274. [PMID: 11932222]
 4. Chaouch MA, Dougaz MW, Khalfallah M, Jerraya H, Nouira R, Bouasker I, et al. A case report of complicated appendicular hydatid cyst mimicking an appendiceal mucocele. *Clin J Gastroenterol* 2019; 1-4. [PMID: 30972709]
 5. Nacef K, Chaouch MA, Ben Khalifa M, Chaouch A, Ghannouchi M, Maatouk M, et al. Liver Hydatid Cyst Complicated by Biliary and Colonic Fistula Diagnosed after Intra-Operative Cholangiography. *Surg Infect Case Rep* 2017; 2:92-94.
 6. Atli M, Kama NA, Yuksek YN, Doganay M, Gozalan U, Kologlu M, et al. Intrabiliary rupture of a hepatic hydatid cyst: associated clinical factors and proper management. *Arch Surg* 2001; 136:1249-1255. [PMID: 11695968]
 7. Reddy AD, Thota A. Cysto-biliary communication (CBC) in hepatic hydatidosis: predictors, management and outcome. *Int Surg J* 2019; 6.
 8. Chaouch MA, Dougaz MW, Cherni S, Nouira R. Daughter cyst sign in liver hydatid cyst. *J Parasit Dis* 2019; 1-2.
 9. Laghi A, Teggi A, Pavone P, Franchi C, De Rosa F, Passariello R. Intrabiliary rupture of hepatic hydatid cysts: diagnosis by use of magnetic resonance cholangiography. *Clin Infect Dis* 1998; 26:1465-1467. [PMID: 9636884]
 10. Jerraya H, Khalfallah M, Osman SB, Nouira R, Dziri C. Predictive factors of recurrence after surgical treatment for liver hydatid cyst. *Surg Endosc* 2015; 29:86-93. [PMID: 24962861]
 11. Noomen F, Mahmoudi A, Fodha Md BM, Fodha M. Surgical treatment of hydatid cysts of the liver. *EMC Surg Tech Dig Sys* 2013; 8:1-18.
-