

# Non-oliguric Renal Failure with Nephromegaly as the presenting Manifestation of Acute Lymphoblastic Leukemia in a Young Adult

Rushi Deshpande<sup>1</sup>, Ashwin Patil<sup>2</sup>, Sudhiranjan Dash<sup>3</sup>, Ganpati Bhat<sup>4</sup>, \*Shaurya Mehta<sup>5</sup>

<sup>1,2,3,5</sup>Department of Nephrology, Jaslok Hospital, Mumbai, India

<sup>4</sup>Ganpati Bhat, Department of Oncology, Jaslok Hospital, Mumbai, India

\*Corresponding author: Shaurya Mehta, DNB Resident, Department of Nephrology, Jaslok Hospital, Mumbai, India

✉ shaurya.mehta.91@hotmail.com

**Citation:** Shaurya Mehta et al. (2020) Non-oliguric Renal Failure with Nephromegaly as the presenting Manifestation of Acute Lymphoblastic Leukemia in a Young Adult, No. 4:5. Ann Clin Nephrol.4.5, 104

**Received:** November 20, 2020; **Accepted:** : November 28, 2020; **Published:** December 06, 2020

## Abstract

Renal failure as the initial presenting manifestation of acute lymphoblastic leukemia (ALL) is uncommon. In Acute leukemia, commonly occurring renal complications are due to leukemic infiltration of the kidneys, treatment-related side effects such as tumor lysis syndrome, nephrotoxic drugs, sepsis. We have presented a case of 25 year female presenting with non-oliguric Acute kidney injury of unknown etiology presenting with raised creatinine and abdominal pain without any other predisposing factor. On thorough investigation, she was diagnosed to have Acute Lymphoblastic Leukemia. The clinical lesson to be learnt from this case is that a complete detailed clinical examination and laboratory work up must be done before labelling AKI as unknown etiology.

## Introduction

In acute leukemia, commonly occurring renal complications are due to the following: leukemic infiltration of the kidneys, treatment-related side effects such as tumor lysis syndrome, nephrotoxic drugs, sepsis, Hyperuricemia and hypercalcemia.[1, 2] Hyperuricemia is a well-recognized complication of tumor lysis syndrome[2] and in most cases, it occurs after the initiation of chemotherapy. Renal failure as the initial presenting manifestation of acute lymphoblastic leukemia (ALL) is not commonly seen.

Here, we report a case of a young female who presented with unexplained acute renal failure and on evaluation was diagnosed to have ALL with predominant renal manifestations.

### Case:

A 25 years old unmarried female residing in Mumbai, visited our hospital with complaints of

- Insidious onset and progressive abdominal distension since 2 months

- Generalised weakness and weight loss (not quantified) since 1 month
- abdominal pain off & on since 20 days which was dull aching in nature, localised to lumbar regions.
- Swelling in B/L lower limbs since 10 days, pitting in nature and aggravating on prolonged standing.

This lady was recently diagnosed with Hypertension 1 month ago during a visit to a local doctor for abdominal discomfort. There was no h/o oliguria, facial puffiness, breathlessness, hematuria, frothing urine, burning micturition. There was no other significant relevant history. There were no other co-morbidities and family history was unremarkable.

On examination, significant findings included high BP 160/100 mmHg in right upper limb in supine position, pedal edema in both legs and bilateral enlarged and ballotable non-tender kidneys on palpation.

No palpable lymphadenopathy, bony tenderness, pallor, icterus

Weight: 53.3 kg Height: 157 cm Body Mass Index 21.6

Salient Investigations were as follows: Hb 10.5 gm/dl, elevated TLC 13200 cells/cm, Platelet count 3.22 lacs, Normal peripheral smear.

Creatinine 5.32 mg/dL, BUN 34 mg/dL, Na/K 135/5.4 mEq/L, Uric acid 10.4 mg/dL, Calcium 9.4 mg/dL, Albumin 3.3 g/dL, LDH 1104 U/L, ESR 75 mm/hr.

Complete urine examination showed Albuminuria, occasional RBC & 6-8 pus cells per high power field. ANA/C3/C4/ANCA were within normal limits. USG abdomen showed bilateral enlarged kidneys, Right 16.6\*10 cm and Left 16.7\*8.4 cm, with raised echogenicity, CMD well maintained, along with bilateral enlarged ovaries. HRCT CHEST was done which did not show any lymphadenopathy and pulmonary infiltrates.

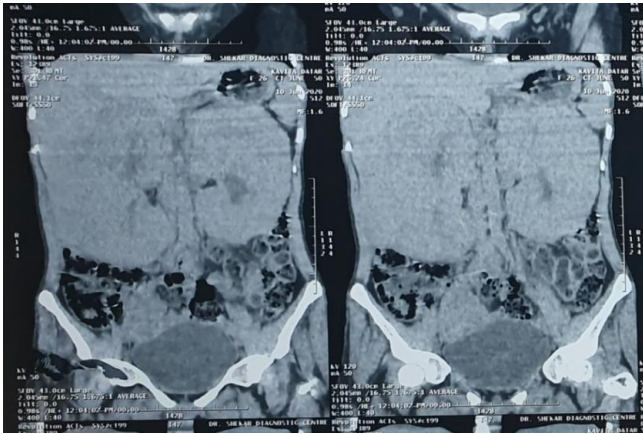

Fig 1: Bilateral massive Nephromegaly on CT Abdomen

CT abdomen (non-contrast enhanced) revealed following findings: (fig 1)

- Rt kidney 17.1\*8.2 cm, Lt 15.2\*8.2 cm with thickened parenchyma. Slight lobulated contours with parenchymal hypo enhancement and irregular areas of preserved normal enhancement within its parenchyma. Mild dialation of pelvicalyceal system seen. No visible multiple parenchymal cysts or focal lesion. No visible lymphadenopathy.
- Lt ovary 4.5\*3.5 cm, Rt 5.8\*4.8 cm. Multipole tiny follicles seen with the enlarged ovaries

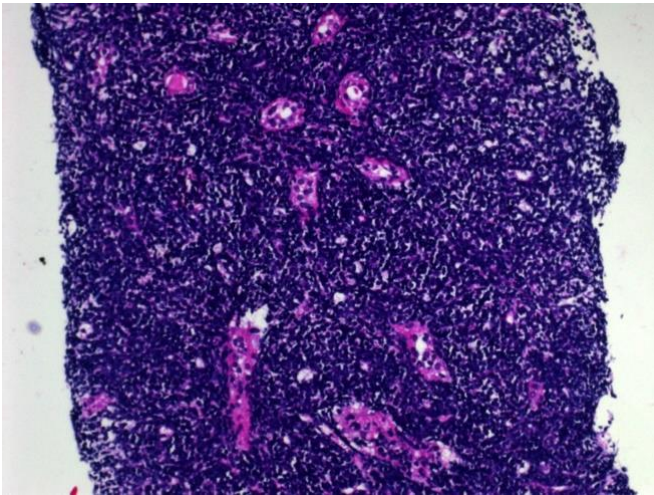


Fig 2: Interstitium is replaced by small to medium sized lymphocytes which are present in sheets and have completely overwhelmed the parenchyma.

A diagnostic kidney biopsy showed (fig2)

- Normal glomeruli with thin basement membrane
- Patent capillary lumina
- Only a few intact tubules showing severe hydropic changes
- Entire interstitium is replaced by small to medium sized lymphocytes which are present in sheets and have completely overwhelmed the entire parenchyma.

- Immunoperoxidase shows tumor cells staining positive (3+) with Tdt, PA5 and 1467.
- A large number of cells stain positive (2+) with CD19, CD 79q and CD10
- IgG, IgA, C3, C1q, Kappa and Lambda are all negative.
- Above findings suggestive of B- lymphoblastic Lymphoma Leukemia

The patient was subjected to Bone marrow biopsy & aspiration for histopathology and immune phenotyping. Findings included Myeloid:Erythroid ratio 3:1 and 45% infiltration of abnormal Lymphoid cells. Bone marrow histopathology did not show any evidence of B cell lymphoblastic leukemia / lymphoma and Immunoperoxidase was PAX5 and Tdt negative. Flowcytometry showed positivity for CD19 (bright positive 90), CD 22 (positive 88), CD38 (bright positive 85), CD200 (dim positive 87) and CD 79a (dim positive 87). Karyotyping showed monosomy 13 and t(1;19). Patient was managed as per Acute Lymphoblastic Leukemia protocols and protocols for anti-tumor lysis protocols.

Discussion:

Leukemia and lymphoma are hematologic malignancies derived from bone marrow or lymphoid cells, respectively and can involve other organs, including the kidneys. Kidney manifestations encompass a broad spectrum of disease- prerenal acute kidney injury (AKI), acute tubular necrosis (ATN), renovascular disease, parenchymal infiltration, obstruction, glomerulopathies, and electrolyte and acid-base abnormalities. Kidney injury may result from the underlying malignancy per se or as a secondary complication of therapy or associated infections.

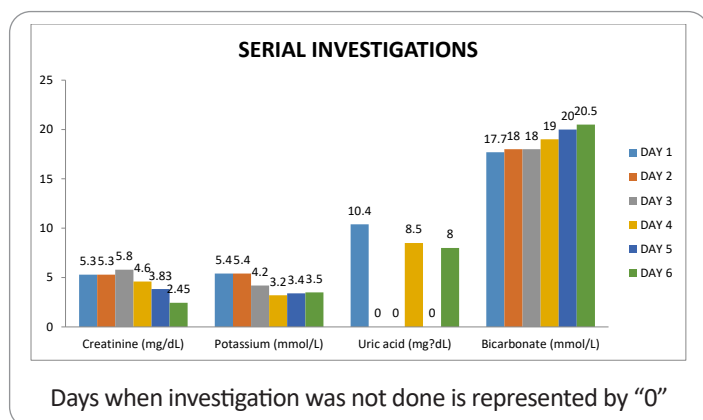
Extra medullary ALL is rare and has classically been described in the setting of relapsed disease in pediatric population. Kebaili et al described a 13 years old female with left solid renal mass discovered on routine ultrasound imaging 32 months after complete remission [3]. Similarly, De Alivia and Menell described a 16 years old male presenting with painless hematuria and solitary left exophytic renal mass 36 months after completing chemotherapy for ALL [4]. In both cases, renal biopsy confirmed lymphoblastic infiltration while bone marrow biopsy/aspirate was normal.

The kidney is the most common extra reticular and extra hematopoietic organ infiltrated by leukemia and lymphoma, with infiltration seen in 60% to 90% of patients with hematologic malignancy.(5) Kidney dysfunction varies from asymptomatic to severe and requiring renal replacement therapy. In a series of 1200 autopsy cases, the prevalence of kidney infiltration was 63% in chronic lymphocytic leukemia (CLL), 54% in acute lymphoblastic leukemia (ALL), 34% in chronic myeloid leukemia (CML), and 33% in acute myeloid leukemia (AML).(6)

Kidney failure as a primary manifestation due to lymphomatous or leukemic infiltration is rare especially in a young adult. AKI from infiltration is seen in only 1% of cases of all patients with acute leukemias (7). Symptoms and signs associated with infiltration include flank pain, hematuria, abdominal distension, or hypertension(7). Infiltration has to be bilateral in nature, and enlargement is

usually uniform. Kidney biopsy is often useful in these patients for 2 reasons. First, the extent and location of infiltration tends to influence prognosis. Interstitial infiltration tends to be associated with AKI, as opposed to glomerular infiltration, which presents as a glomerulopathy. Secondly, biopsy may help differentiate subtypes of lymphoma or leukemia and alter disease treatment. Specific stains can be used to identify cellular markers. Targeting these cells with chemotherapy is important because improvement of kidney function depends on treatment of the underlying disease. Regression and improvement in kidney function should be prompt (ie, occurring sometime within 2-3 days of therapy). Kidney failure resulting from infiltration is thought to be secondary to acute tubular compression and disruption of the kidney microvasculature from increased interstitial pressure leading to ATN.

Patient was started on alkaline diuresis, dexamethasone and uric acid reducing agents on Day 2. Potassium homeostasis was maintained medically. Serial laboratories were done (Table 1)



Targeting these cells with chemotherapy is important because improvement of kidney function depends on treatment of the underlying disease. Regression and improvement in kidney function should be prompt (ie, occurring sometime within 2-3 days of therapy).[8]

Our case is unique in that non-oliguric renal failure was the presenting feature with nearly normal peripheral blood counts, normal peripheral blood smear, hyperuricemia, no evidence of lymphadenopathy, Bilateral enlarged kidney, elevated LDH, lymphoblastic leukemia on renal biopsy, Bone marrow study including biopsy and flowcytometry showing bone marrow involvement with more than 20% leukemic cells and markers of B- cell Lymphoblastic leukemia/lymphoma.

A clinical lesson to be learnt in this case is that diagnosis wise one has to search for a cause for unexplained AKI. Before labelling a patient as AKI of unknown etiology, it is prudent to evaluate the patient thoroughly. In this case the clue for underlying disease came from patients clinical examination with hyperuricemia, high LDH and enlarged kidneys.

#### Acknowledgement:

We would like to thank Dr. Shaila Khubchandani, consultant, department of Pathology, Jaslok Hospital, Mumbai, India, for her

expert opinion on kidney and bone marrow biopsy.

**Funding:** None

**Conflicts of Interest:** None

#### Abbreviations:

ALL : Acute Lymphoblastic leukemia

BP: Blood Pressure

ESR: Erythrocyte sedimentation Rate

AKI: Acute Kidney Injury

LDH: Lactate Dehydrogenase

CMD: Corticomedullary Differentiation

ATN: Acute Tubular Necrosis

Na: Sodium

K: Potassium

mEq/L: milliequivalent per litre

cmm: cubic millimetre

ANA: Antinuclear antibodies

ANCA: Antineutrophil Cytoplasmic Antibodies

#### References:

- Munker R, Hill U, Jehn U, Kolb HJ, Schalhorn A. Renal complications in acute leukemias. *Haematologica* 1998;83:416-21.
- Lommatzsch SE, Bellizzi AM, Cathro HP, Rosner MH. Acute renal failure caused by renal infiltration by hematolymphoid malignancy. *Ann Diagn Pathol* 2006;10:230-4
- Kebaili K, Manel AM, Chapelon C, Taylor P, Philippe N, et al. (2000). "Renal enlargement as presentation of isolated renal relapse in childhood leukemia," *Journal of Pediatric Hematology/Oncology*. 22: 454-456.
- Alivia De, Menell J. (2010). "Isolated Renal Relapse in ALL" *Journal of Pediatric Hematology/Oncology*. 32: 150-151.
- Richmond J, Sherman RS, Diamond HD, Craver LF. Renal lesions associated with malignant lymphomas. *Am J Med*. 1962;32:184-207.
- Barcos M, Lane W, Gomez GA, et al. An autopsy study of 1206 acute and chronic leukemias (1958 to 1982). *Cancer*. 1987;60(4): 827-837
- Lundberg WB, Cadman ED, Finch SC, Capizzi RL. Renal failure secondary to leukemic infiltration of the kidneys. *Am J Med*. 1977; 62(4):636-642.
- Obrador GT, Price B, O'Meara Y, Salant DJ. Acute renal failure due to lymphomatous infiltration of the kidneys. *J Am Soc Nephrol*.1997;8(8):1348-1354.