

CASE REPORT

Necrotizing Pancreatitis and Gas Forming Organisms

Theodore Hufford, Terrence Lerner

Metropolitan Group Hospitals Residency in General Surgery, University of Illinois, United States

ABSTRACT

Context Acute Pancreatitis is a common disease of the gastrointestinal tract that accounts for thousands of hospital admissions in the United States every year. Severe acute necrotic pancreatitis has a high mortality rate if left untreated, and always requires surgical intervention. The timing of surgical intervention is of importance. Here we present a case of a patient with severe necrotizing pancreatitis with possible gas producing bacteria in the retroperitoneum shown on imaging and cultures. **Case Report** The patient is a Seventy-two-year old male presenting to the emergency department with complaining of severe epigastric pain for the past 48 hours. The labs and clinical symptoms were consistent with pancreatitis. However, the imaging showed necrotic pancreatitis that required immediate intervention. During the course of six weeks, the patient underwent numerous surgical procedures to debride the necrotic pancreas. The patient was ultimately clinically stable to be discharged and transferred to a skilled-nursing facility, but returned 3 days later with a post-surgical wound infection vs. anastomotic leak with enterocutaneous fistula. **Conclusion** The patient ultimately expired 7 days after his second admission to the hospital due to multi-organ failure secondary to sepsis.

INTRODUCTION

Acute Pancreatitis (AP) is a common disease of the gastrointestinal (GI) tract that accounts for thousands of hospital admissions in the United States every year. AP is an acute process that causes mild inflammation to severe necrosis of the pancreatic tissue [1, 2]. In most instances, AP is mild and minimal and no surgical or pharmacological intervention is required [1, 3]. In other cases, AP may develop to a more severe form of the disease which could lead to the necrosis of pancreatic parenchyma or peri-pancreatic tissue [3, 4]. Severe acute pancreatitis has a high mortality rate if left untreated and in the otherwise healthy patient, will sometimes requires surgical intervention [1, 2, 3, 4].

Necrotizing pancreatitis, a condition where the pancreas may become swollen and many cells undergo cell death, or necrosis, which can manifest in both an infectious and/or non-infectious etiology [2, 3]. The timing of surgical intervention for necrotizing pancreatitis is of significant importance [2]. In the past, immediate surgical intervention was correlated with a high mortality rate [2, 3, 5]. With infectious necrotizing pancreatitis, the use of antimicrobials agents and delaying surgical intervention

has proven to decrease mortality by about 40% in most cases [6]. Finding the cause of the infection is of the utmost importance in necrotizing pancreatitis cases. Most infecting organisms are coliform bacteria that migrate via vessels of the GI tract [7]. Some of these organisms have been known to produce gas, increasing the mortality rate to more than 50% [5]. And the overall prognosis for emphysematous pancreatitis is uncertain [6]. Both the use of aggressive antimicrobial agents to control the body's systemic inflammatory response, and appropriate surgical interventions has correlated with improved mortality rates [2, 5, 7]. However, not all types of pancreatitis require antimicrobial agents. Current guidelines do not recommend the routine use of antimicrobial agents in uncomplicated pancreatitis unless an extra-pancreatic infection is suspected [8].

Here we present a case of a patient with severe necrotizing pancreatitis with possible gas producing bacteria in the retroperitoneum behind the duodenum and tracking up into what looks like the inferior mediastinum as shown on imaging modalities.

CASE REPORT

A Seventy-five-year old Asian male presented to the emergency department with complaints of severe abdominal pain that had persisted for the past two days. He presented with epigastric abdominal pain, complaints of nausea, non-bloody or non-bilious emesis, hiccups and anorexia. The patient stated the pain began suddenly and has continuously worsened over the past 2 days. At presentation, the patient denied fever or chills or other gastrointestinal symptoms other than those are already listed. Past medical history was significant for a history of peptic ulcer disease, hypertension, benign prostatic

Received April 03rd, 2016 - Accepted June 22nd, 2016

Keywords Pancreatitis, Acute Necrotizing

Abbreviations AP Acute Pancreatitis; GI Gastrointestinal

Correspondence Theodore Hufford

Metropolitan Group Hospitals Residency in General Surgery
University of Illinois

836 W. Wellington, Room 4807

Chicago, IL 60657

United States

Tel + 773-296-5347

Fax + 773-296-5570

E-mail tjhufford80@gmail.com

hyperplasia, and hepatitis B. The patient was a non-smoker and no alcohol or drug abuse reported.

Upon initial physical examination, vital signs were stable, the patient was afebrile, left upper quadrant pain, tenderness as well as some voluntary guarding was noted in the mid-epigastrium. His lower abdomen was benign and would stay that way throughout his hospital course.

Laboratory tests revealed various abnormal values: high White blood cell count ($11.0 \times 10^3/\text{mCL}$), with high percentage of Bands present (16%), high glucose levels (169 mg/dL), high lipase (3,610 Units/L), liver function markers were also elevated Alkaline Phosphatase (158.0 units/L), Alanine Transaminase (ALT), (269 units/L), Aspartate Transaminase (AST) (284 units/L) and total bilirubin (3.20 mg/dL), and total Calcium (8.8 mg/dL), Erythrocyte sedimentation rate, C-reactive protein, triglycerides and amylase levels were not determined.

On Computerized tomography (CT) scan of the chest, pelvis and abdomen, the pancreatic tail was predominantly involved. Large amounts of free air was seen within the retroperitoneal space surrounding the pancreatic tail and extending along the inferior and lateral margin of the gastric body and fundus (**Figure 1ab**) pancreatitis (**Figure 1c**).

Additional air is seen dissecting superiorly through the esophageal hiatus with several small foci of extraluminal air seen along the margins of the esophagus (**Figure 1a**). There is extensive inflammation of the retroperitoneal fat extending from the gastrohepatic ligament area, surrounding the pancreas and inferiorly to the 3rd portion of the duodenum, showing possible emphysematous pancreatitis (**Figure 2ab**).

Using intravenous contrast to enhance the CT, it shows the pancreatic tail is predominantly involved. There has been further fluid collection within the prior air-filled cavity superiorly and along the left lateral aspect (**Figure 3**). The pancreatic body and head enhance homogeneously and do not seem involved. However, the pancreatic tail does not enhance appreciably and is presumably necrotic. Fluid and inflammatory change extended into the paracolic gutters, more so on the right (**Figure 4ab**).

Based on the imaging done and clinical symptoms of the patient, two plausible diagnoses were the cause of the patient's admission to the hospital. Given the large amounts of free air contained within the retroperitoneum, a duodenal perforation is the most likely cause. Furthermore, looking at the necrotic, fluid filled pancreatic tail, a possible gas-producing organism could be the etiology of the free air found in the retroperitoneal space. Given the current status of the patient, empiric, broad-spectrum antimicrobial treatment was started, and acute surgical intervention was delayed until clinical improvement was noted.

Throughout the course of the patient's stay at the hospital, the patient had numerous organisms from histological and fluids sampled to determine the source

of infection. Extended spectrum Beta-lactamase (ESBL) producing *Enterobacter aerogenes* and some clusters of *Enterococcus faecalis* were present in both peritoneal and wound samples. Upon admission, the patient was empirically started on piperacillin-tazobactam. However, once culture and sensitivity results were available, the antimicrobial agents were changed to imipenem/cilastatin and vancomycin to provide adequate coverage. Once the patient was clinically stable, an exploratory laparotomy and debridement of the necrotic pancreatic tissue was performed. A few days later, a second exploratory laparotomy to further assess the extent of the necrotic pancreas and also a negative-pressure wound therapy vac device was placed, along with further debridement of the necrotic pancreas. Due to the need for enteral feeding, a jejunostomy tube was placed which subsequently became infected and required multiple visits to the operating room for replacement.

Once it was decided the patient was clinically stable and ready for a possible discharge to a long-term acute care facility (LTAC), the decision was made to perform a complex abdominal closure with a retrorectus repair with an added biological mesh.

Almost 6 weeks after his admission to the emergency department for emphysematous pancreatitis, the patient was both clinically and hemodynamically stable to be transferred to a LTAC facility and scheduled to follow up in 1 month.

One week post-hospital discharge, the patient presented to the emergency department with a 3-day history of increased bilious output from the wound-site with low-grade fevers and leukocytosis. The patient ultimately expired a few days later most likely due to the development of multi-organ system failure secondary to sepsis caused by hospital-acquired pneumonia, infected pancreatitis, and jejunal bile leak.

DISCUSSION

Infected pancreatitis necrosis can have multiple etiologies with the most likely being ascending bacterial infection from the duodenum or bowel perforation. Furthermore, even though the patient had bacterial cultures growing gas-producing organisms, the amount of free air seen in the retroperitoneum was too abundant to be explained solely on the basis of a colony of gas forming organisms. In this case, given his acute onset of pain without an insidious component, an acute perforation in the duodenum seems to better explain the patient's overall clinical picture. As for the etiology of the bowel perforation, the patient denies any recent medical procedures, therefore, an iatrogenic cause can be excluded. A duodenal perforation is most likely the cause given the patient's history of peptic ulcer disease [9, 10].

Given all of these findings, this unfortunate man succumbed to his infection, however, a few key points are necessary to be clarified. In the event the necrosectomy is likely to be required, early debridement with sump drain

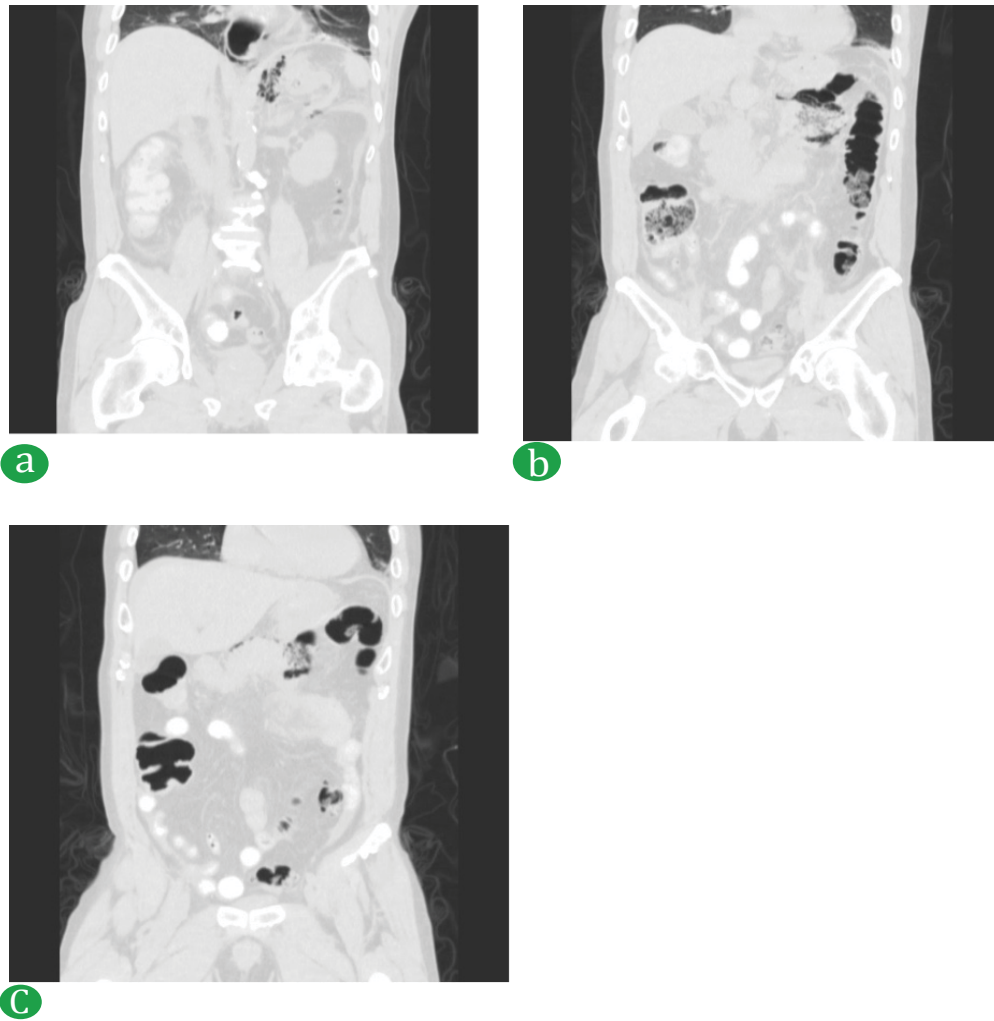


Figure 1. Computerized tomography (CT) scan of the chest. (a). gastric body, (b). fundus, and (c). pancreatitis.

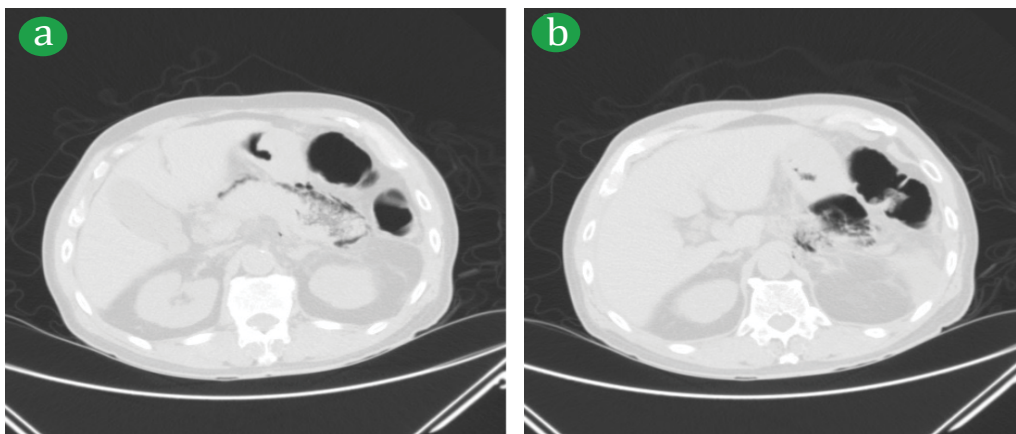


Figure 2. (ab). Emphysematous pancreatitis.

placement is very important. In this case, necrosectomy was delayed due to patient condition, however it must also be noted that debridement is a very aggressive and morbid procedure that increases the risk of complications and mortality [3, 5].

Overall, the important lessons learned here are that pancreatic necrosis when infected should be treated expeditiously. Using appropriate antimicrobial agents is of utmost importance. Also, adequate fluid hydration is necessary for the treatment of pancreatitis; the

balancing act between hydration and diuresis is an appropriate consideration and risking over-hydration of the patients with significant risk factors and comorbidities could lead to increased complications. The key to the reduction of over-hydration is frequent assessment during the first 24-48 hours of presentation [8]. Ranson's Criteria, while slowly becoming a historical calculation, may still play some role, especially in the setting of acute pancreatitis of unknown etiology in the critically ill patient [11].

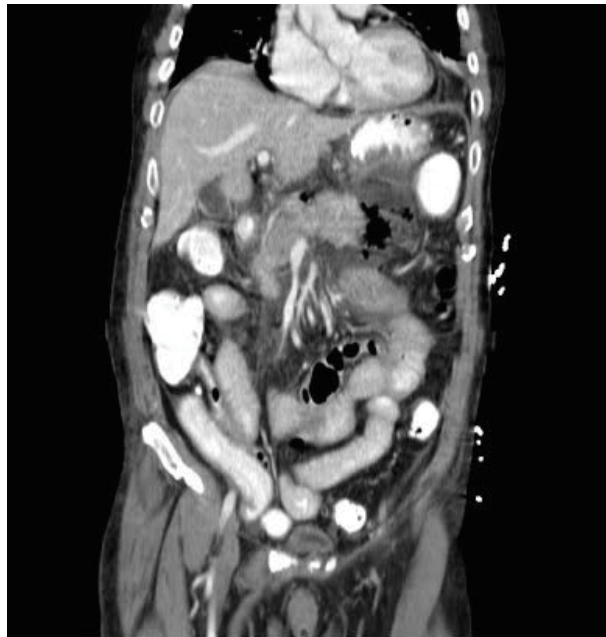

Figure 3. Prior air-filled cavity superiorly and along the left lateral aspect.

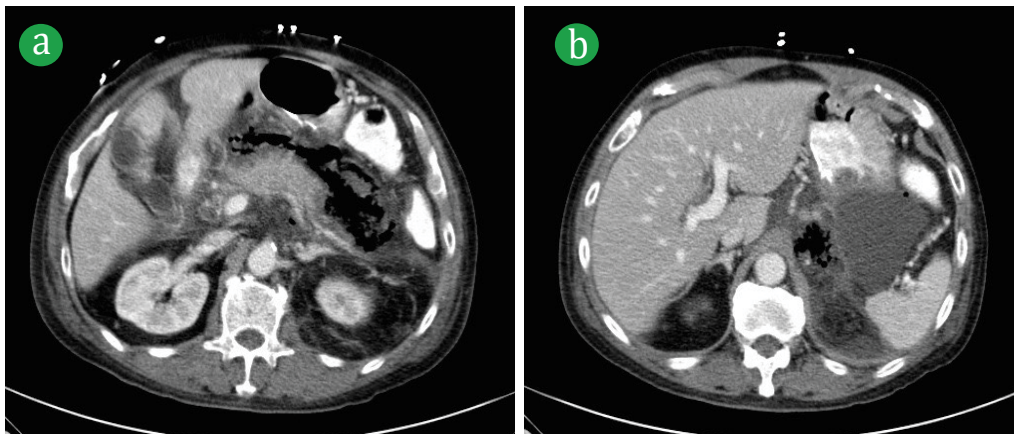


Figure 4. (ab). Fluid and inflammatory change extended into the paracolic gutters.

Conflict of Interest

The authors declare that there is no conflict of interests regarding the publication of this paper.

References

1. Frossard JL, Steer ML, Pastor CM. Acute pancreatitis. *Lancet* 2008; 371:143-152. [PMID: 18191686]
2. Peery AF, Crockett SD, Barritt AS, Dellon ES, Eluri S, Gangarosa LM, Jensen ET. Burden of gastrointestinal, liver, and pancreatic diseases in the united states. *Gastroenterology* 2015; 149:1731-1741. [PMID: 26327134]
3. Cameron J, Cameron A. Pancreatic necrosis. In *Current surgical therapy*. 11edtn; 450-454.
4. Banks PA, Freeman ML, Practice Parameters Committee of the American College of Gastroenterology. Practice guidelines in acute pancreatitis. *Am J Gastroenterology* 2006; 101:2379-2400. [PMID: 17032204]
5. Beger H, Rau B. Severe acute pancreatitis: Clinical course and management. *World J Gastroenterol* 13:5043-5051. [PMID: 17876868]
6. Petrov MS, Shanbhag S, Chakraborty M, Phillips AR, Windsor JA. Organ failure and infection of pancreatic necrosis as determinants of mortality in patients with acute pancreatitis. *Gastroenterology* 2010; 139:813-820. [PMID: 20540942]
7. Grayson DE, Abbott RM, Levy AD, Sherman PM. Emphysematous infections of the abdomen and pelvis: a pictorial review 1. *Radiographics* 2002; 22:543-561. [PMID: 12006686]
8. Tenner S, Baillie J, DeWitt J, Vege SS, American College of Gastroenterology. American college of gastroenterology guideline: management of acute pancreatitis. *Am J Gastroenterol* 2013; 108:1400-1415. [PMID: 23896955]
9. Di Saverio S, Bassi M, Smerieri N, Masetti M, Ferrara F, Fabbri C, Ansaloni L, et al. Diagnosis and treatment of perforated or bleeding peptic ulcers: 2013 WSES position paper. *World J Emerg Surg* 2014; 9:45. [PMID: 25114715]
10. Irvin TT. Mortality and perforated peptic ulcer: A case for risk stratification in elderly patients. *Br J Surg* 1989; 76:215-218. [PMID: 2720316]
11. Busquets J, Peláez N, Secanella L, Darriba M, Bravo A, Santafosta E, Valls C, et al. Evolution and results of the surgical management of 143 cases of severe acute pancreatitis in a referral center. *Cir Esp* 92:595-603. [PMID: 24916318]