

CASE REPORT

Multi-Modality Therapy for Primary Squamous Cell Carcinoma of the Ampulla of Vater - Report of a Rare Case with Literature Review

Sudarshan Reddy, Sadaf Ali Bangri, K Dinesh, Ajaz A Wani,
Sharan Kumar N, Khalid Basheer B, Sourabh J

Department of Surgical Gastroenterology, Sher I Kashmir Institute of Medical Sciences,
Soura, Srinagar, Jammu and Kashmir, India, 190011

ABSTRACT

Background Primary squamous cell carcinoma of the ampulla of Vater is a rare tumor, and the treatment and prognosis of which is not well known because of limited number of reported cases in the literature. Here, we report the case of primary squamous cell carcinoma of the ampulla of Vater, treated with multimodality therapy (surgery and adjuvant chemotherapy), and have a longer survival than the reported cases in the literature. **Case presentation** A Sixty-five-year-old woman presented with painless progressive jaundice and generalized itching. The clinical presentation, radiographic and endoscopic investigations strongly suggest periampullary carcinoma. We performed Pylorus-preserving pancreaticoduodenectomy with curative intent. Histopathological examination and immunohistochemistry analysis revealed primary squamous cell carcinoma of ampulla of vater. The postoperative course was uneventful. The patient received adjuvant chemotherapy, and patient is on follow up with no tumor recurrence, and having a good quality of life for last 1 year after multimodality therapy. **Conclusion** Primary squamous cell carcinoma of the ampulla of Vater is a rare histological type. The literature review revealed the poor prognosis of all the reported cases of primary squamous cell carcinoma of the ampulla of Vater. The optimal treatment and prognosis is unclear. To the best of our knowledge, this is the first report of primary squamous cell carcinoma of the ampulla of Vater that was treated with multimodality therapy. With our experience, we suggest that multimodality treatment should be the mainstay therapy for primary squamous cell carcinoma of the ampulla of Vater. However, more number of studies on clinico-pathological findings and treatment modality are required to determine appropriate treatment strategy and prognosis of this tumor.

BACKGROUND

Periampullary carcinomas arise within 2 cm of the major duodenal papilla and comprise carcinomas of the pancreas, ampulla of vater, distal common bile duct, and duodenum [1]. The majority of periampullary cancers are adenocarcinomas. The most common periampullary adenocarcinoma is pancreatic (40-60%) followed by ampulla of vater (10-20%), distal cholangiocarcinoma (10%), and duodenal carcinoma (5-10%) [2, 3]. According to the WHO classification of the digestive system tumors, most ampullary neoplasms are adenocarcinomas, other forms such as squamous cell carcinoma is extremely rare [4]. The clinicopathological characteristics, optimal treatment and prognosis of primary squamous cell carcinomas of the ampulla of Vater are not well known mainly due to the lack of clinical data. Here, we report the case of primary squamous cell carcinoma of the ampulla

of Vater, treated with multimodality therapy (surgery and adjuvant chemotherapy), and have a longer survival after surgery.

CASE PRESENTATION

A Sixty-five-year-old woman presented with painless progressive jaundice and generalized itching of 3 weeks duration. She also reported generalized fatigue, loss of appetite. She past medical history and family history was unremarkable. On physical examination she had icterus and scratch marks over the body. Abdominal examination revealed palpable gallbladder.

Laboratory tests revealed abnormal Liver function tests: total bilirubin: 22.7 mg/dL, direct bilirubin: 18.0 mg/dL, alkaline phosphatase: 279 IU/L (reference range: 30-120 IU/L), aspartate aminotransferase (AST): 24 IU/L, alanine aminotransferase (ALT): 22 IU/L. Serum levels of carbohydrate antigen 19-9 (CA 19-9) and carcinoembryonic antigen (CEA) were 115 U/mL and 2.65 ng/mL, respectively. She had anemia with hemoglobin levels at 9.7 g/dL.

Abdominal ultrasonography showed a distended gallbladder, dilatation of the intra- and extrahepatic bile ducts with abrupt cut off. Magnetic resonance imaging (MRI) and magnetic resonance cholangiopancreatography (MRCP) examinations demonstrated a T1 hypointense lesion with a size of 34×23 millimeters in the periampullary region occluding the distal segment of the common bile

Received July 25th, 2016 - Accepted August 28th, 2016

Keywords Ampulla of Vater; Carcinoma; Pancreas

Abbreviations CECT contrast enhanced computerised tomography; MRCP magnetic resonance cholangiopancreatography; MRI magnetic resonance imaging; PD pancreatico-duodenectomy; SCC squamous cell carcinoma

Correspondence Sudarshan Reddy
Department of Surgical Gastroenterology
Sher-i-Kashmir Institute of Medical Sciences
Surgical Gastroenterology
Srinagar, Jammu & Kashmir India

Phone 81-76-265-2794

Fax 81-76-234-4524

E-mail deepuksr26@gmail.com

duct. Side-viewing duodenoscopy revealed friable ulcero-infiltrative growth of major duodenal papillae measuring about 3×2 centimeters, and took biopsy from the lesion. The biopsy was inconclusive. The multi row detector computed tomography (MDCT) of the abdomen and pelvis showed a distended gallbladder, dilatation of the intra- and extrahepatic bile ducts with abrupt cut off due to enhancing mass lesion in periampullary region with a size of 33×26 millimeters and main pancreatic duct was prominent. Periampullary lesion away from the main vessels, and lesion was resectable. CT – chest was normal.

Patient underwent pylorus preserving pancreaticoduodenectomy with curative intent. The macroscopic inspection of the resected specimen revealed a 3×2 cm, solid, grey white ulcero-infiltrative tumor originating from the ampulla of Vater and infiltrated pancreas. Histopathological examination showed a well-differentiated squamous cell carcinoma (**Figure 1**). Multiple serial sections of the tumor specimen revealed same histological component. No regional lymph node metastases or perineural invasion were observed. All resection margins were free of tumor. Lymphovascular invasion was observed. Immunohistochemical analysis showed that the tumor cells were positive P40, P63 and CK7, support squamous differentiation of the carcinoma. The disease was classified as stage IIA (T3N0M0) according to the AJCC seventh edition (2010) of the TNM staging system. The postoperative course was uneventful. The patient received 6 cycles of Paclitaxel plus Carboplatin based adjuvant chemotherapy and patient remained under close follow-up in every 3 months. Her follow up imaging doesn't reveal any features of local or distant recurrence, with good quality of life, and completed 1 year period of follow up after surgery.

DISCUSSION

The intramural portion of the common bile duct runs obliquely about 1.5 centimeter in the posteromedial wall of second part of the duodenum. Here main pancreatic duct joins the common bile duct, and forms a dilated common channel known as ampulla of vater, which opens into papilla of vater [5, 6]. Common bile duct and duodenal epithelium merge in the ampullary region. Adenocarcinoma is the most common ampullary neoplasm, which may be either pancreaticobiliary type or intestinal type. 85% of ampullary carcinomas

are Intestinal type adenocarcinomas [7]. These two subtypes resemble pancreatic and duodenal carcinomas respectively, which have different molecular alterations, tumor growth and biology, distinct histological and immunohistochemical features, and clinical outcome [8, 9, 10]. The other unusual histological tumor types of ampulla of vater includes mucinous, adenosquamous [11, 12, 13], signet cell [14, 15], clear cell, neuroendocrine [16, 17] and squamous cell carcinoma, very few cases of which were reported in literature.

The ampulla of Vater do not have squamous epithelium and, therefore, the pathogenesis of primary squamous cell carcinoma of ampulla of vater remains unclear, the four prevailing hypotheses describes mechanism -(1) pluripotent stem cells capable of inducing the malignant transformation of squamous cell carcinoma [18], (2) squamous metaplasia of intestinal mucosa as a result of chronic inflammation due to the bile and pancreatic juice reflux, choledochal cyst, choledocholithiasis [19], (3) malignant transformation of ectopic squamous epithelium and (4) progression of an adenocarcinoma into adenosquamous and eventually to squamous cell carcinoma [20].

In our case, Histopathological examination revealed a well-differentiated squamous cell carcinoma. Multiple serial sections of the tumor specimen showed same histological component, there was no evidence of squamous metaplasia, the immunohistochemical profiling confirms the diagnosis of squamous cell carcinoma. Pathak GS *et al.* reported a case of coexistent ampullary squamous cell carcinoma with adenocarcinoma of the pancreatic duct [21]. The metastatic work up with the extensive imaging studies excluded the presence of a primary squamous cell cancer elsewhere and, therefore, we consider present case as a pure primary squamous cell carcinoma of the ampulla of Vater. Sreenarasimhaiah and Hoang reported a case of squamous cell carcinoma of esophageal, that was metastasized to the ampulla of Vater [22], Buyukcelik *et al.* reported a case of laryngeal squamous cell carcinoma that was metastasized to the ampulla of Vater [23].

The literature was searched through PubMed using the terms ampulla of vater, papilla and primary squamous cell carcinoma, and four reported cases of primary squamous cell carcinoma of the ampulla of Vater [24, 25, 26, 27],

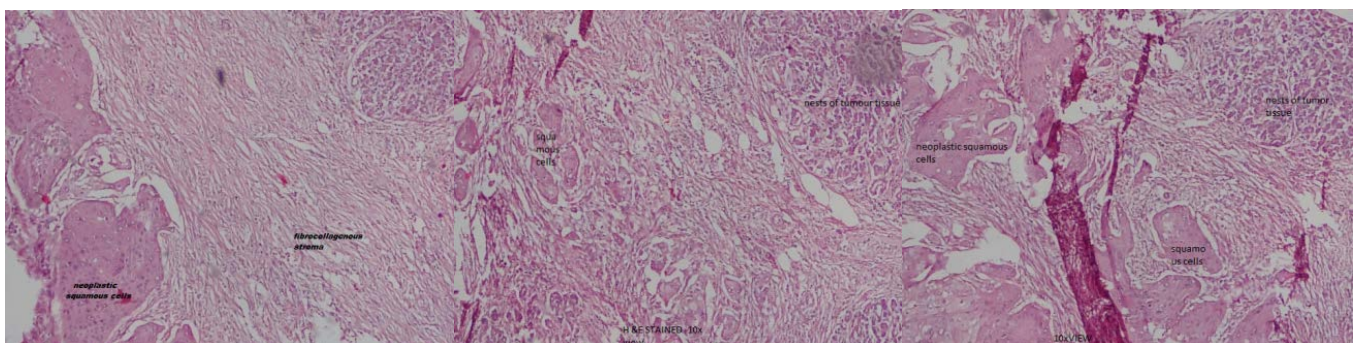


Figure 1. Histopathological examination showed a well-differentiated squamous cell carcinoma.

one reported case of coexistent ampullary squamous cell carcinoma with adenocarcinoma of the pancreatic duct [21] were retrieved from the literatures. Data of these reported cases, including the present patient, are summarized in **Table 1**.

The demographic data analysis showed mean age at diagnosis was 56 years (range, 28–72), and five of six patients (83%) were female. In the present case patient presented with the symptoms of obstructive jaundice and subsequent evaluation revealed the diagnosis of carcinoma of the ampulla of Vater. All other patients presented with symptoms such as jaundice, abdominal pain and generalized itching, which were similar to the symptoms of ampullary adenocarcinoma.

In the past literature the risk versus benefit ratio analysis of surgery, poor outcome following surgery for periampullary carcinoma questioned the role of surgical resection for periampullary carcinoma [28, 29, 30, 31, 32]. Memon *et al.* in their reported study supported the surgical resection for ampullary carcinomas [33]. However, we are strongly believes that surgery with curative intent remains the cornerstone in the treatment of periampullary carcinoma. Surgical procedures performed were pancreaticoduodenectomy, including PPPD, in five cases (83%) and one case managed with percutaneous transhepatic biliary drainage plus radiotherapy (17%). In the present case patient treated with PPPD and adjuvant chemotherapy (17%). Overall survival was range from zero to 12 months. In the present case patient is alive, and free of tumor recurrence for last 12 months after surgery with adjuvant chemotherapy (multimodality therapy).

Long-term survival of primary squamous cell carcinoma (SCC) in the ampulla of vater was not well known because of limited literature. Lemura *et al.* studied cholangiocarcinomas in mouse models, reported that SCC component grows more aggressively than adenocarcinoma component in their animal models [34]. Honda *et al.* and Wilson *et al.* reported that SCC has significantly shorter doubling time than adenocarcinoma in the lung cancer [35, 36]. Hong *et al.* and Yamana *et al.* reported that pure squamous cell carcinomas of the biliary tract were associated with decreased survival rates compared to adenocarcinomas and adenosquamous carcinomas [37, 38]. Based on the literature review, primary squamous cell carcinomas of the ampulla of Vater should be considered as more aggressive than adenocarcinomas.

Local recurrence is most common after surgery for biliary tract cancer, is the main limitation for cure, which recommends and provides important justification for the use of adjuvant therapy. In patient with resectable biliary cancers the role of adjuvant chemotherapy or chemoradiotherapy is poorly established [39]. In majority cases the recommendations in the NCCN (National Comprehensive Cancer Network) guidelines on the use of adjuvant chemoradiotherapy or chemotherapy are not specific to the particular biliary tract cancer type because these recommendations were made on the basis of limited data and the heterogeneity of the patient populations in the published studies. NCCN guidelines recommends adjuvant chemotherapy or chemoradiotherapy for patients underwent curative resection of extra-hepatic cholangiocarcinomas with negative resection margins and negative regional lymph nodes. In our case patient received 6 cycles of Paclitaxel plus Carboplatin based Adjuvant chemotherapy according to NCCN guidelines and patient remained under close follow-up in every 3 months. The patient is on follow up for last 12 months after multimodality therapy (surgery plus adjuvant chemotherapy), and patient remains free of tumor recurrence with good quality of life. Hence, we strongly recommend that multimodality treatment should be the mainstay therapy for primary squamous cell carcinoma of the ampulla of Vater. However more studies are required as of now.

CONCLUSION

Primary squamous cell carcinoma of the ampulla of Vater is a rare histological type. The literature review revealed the poor prognosis of all the reported cases of primary squamous cell carcinoma of the ampulla of Vater. The optimal treatment and prognosis is unclear. To the best of our knowledge, this is the first report of primary squamous carcinoma of the ampulla of Vater that was treated with multimodality therapy. With our experience, we suggest that multimodality treatment should be the mainstay therapy for primary squamous cell carcinoma of the ampulla of Vater.

However, more number of studies on clinicopathological findings and treatment modality are required to determine appropriate treatment strategy and prognosis of this tumor.

Table 1. Reported cases of primary squamous cell carcinoma of the ampulla of Vater in the literature.

Year	Author	Age (years)	Sex	Symptoms	Biopsy	Treatment	AJCC stage	Prognosis (months)
1996	Chen CM	72	F	Jaundice, abdominal pain, fever	SCC	PTBD & RT	NM	Died during RT
2009	Gupta A	28	F	Jaundice, abdominal pain	SCC	PD	NM	NM
2009	Pathak GS	50	F	Jaundice, generalized itching	SCC ADC-pancreatic duct	PD	NM	NM
2014	Bolanaki H	68	M	Jaundice, dark coloured urine	SCC	PD	IIA	5 Dead
2016	Balci B	54	F	Jaundice, abdominal pain, weight loss	SCC	PD	IIA	NM
	Present case	65	F	Jaundice, generalized itching	SCC	PPPD & Adjuvant CT	IIA	12 Alive

SCC squamous cell carcinoma; ADC adenocarcinoma; PD pancreaticoduodenectomy; PPPD pylorus preserving pancreaticoduodenectomy; PTBD percutaneous transhepatic biliary drainage; RT radiotherapy; CT chemotherapy; NM not mentioned

Conflict of Interest

The authors have no potential conflict of interest.

References

1. Kim JH, Kim MJ, Chung JJ, Lee WJ, Yoo HS, Lee JT. Differential diagnosis of periampullary carcinomas at MR imaging. *Radiographics* 2002; 22:1335-52. [PMID: 12432106]
2. Yeo CJ. The Whipple procedure in the 1990s. *Adv Surg* 1999; 32:271-303. [PMID: 9891749]
3. Bettschart V, Rahman MQ, Engelken FJ, Madhavan KK, Parks RW, Garden OJ. Presentation, treatment and outcome in patients with ampullary tumours. *Br J Surg* 2004; 91:1600. [PMID: 15515106]
4. Bosman FT. International Agency for Research on C. WHO classification of tumours of the digestive system. In: World Health Organization classification of tumours. International Agency for Research on Cancer. 4th ed. Lyon: IARC Press, 2010.
5. Dowdy GS Jr. The biliary tract. Philadelphia: Lea and Febier 1969.
6. Michels NA. Blood supply and anatomy of the upper abdominal organs. Philadelphia: Lippincott 1995.
7. Kimura W, Futakawa N, Yamagata S, Wada Y, Kuroda A, Muto T, Esaki Y. Different clinicopathologic findings in two histologic types of carcinoma of papilla of water. *Jpn J Cancer Res* 1994; 85:161-165. [PMID: 7511574]
8. Kimura W, Futakawa N, Zhao B. Neoplastic diseases of the papilla of Vater. *J Hepatobiliary Pancreat Surg* 2004; 11:223-31. [PMID: 15368105]
9. Fischer HP, Zhou H. Pathogenesis of carcinoma of the papilla of Vater. *J Hepatobiliary Pancreat Surg* 2004; 11:301-9. [PMID: 15549428]
10. Westgaard A, Pomianowska E, Clausen OP, Gladhaug IP. Intestinal-type and pancreatobiliary-type adenocarcinomas: how does ampullary carcinoma differ from other periampullary malignancies? *Ann Surg Oncol* 2013; 20:430-9. [PMID: 22956064]
11. Ueno N, Sano T, Kanamaru T, Tanaka K, Nishihara T, Idei Y, Yamamoto M, et al. Adenosquamous cell carcinoma arising from the papilla major. *Oncol Rep* 2002; 9:317-20. [PMID: 11836599]
12. Song HG, Yoo KS, Ju NR, Park JC, Jung JO, Shin WG, Moon JH, et al. A case of adenosquamous carcinoma of the papilla of Vater. *Korean J Gastroenterol* 2006; 48:132-6. [PMID: 16929159]
13. Yavuz E, Kapran Y, Ozden I, Bulut T, Dizdaroğlu F. Pancreatobiliary adenosquamous carcinoma (report of two cases). *Pathologica* 2000; 92:323-6. [PMID: 11198466]
14. Ishibasi Y, Ito Y, Omori K, Wakabayashi K. Signet ring cell carcinoma of the ampulla of Vater. A case report. *J Pancreas* 2009; 10:690-3. [PMID: 19890196]
15. Hara T, Kawasima H, Ishigooka M, Kashiyama M, Takanashi S, Hosokawa Y. Signet-ring-cell carcinoma of the ampulla of Vater: a case report. *Hepatogastroenterology* 2002; 49:561-3. [PMID: 11995497]
16. Sugawara G, Yamaguchi A, Isogai M, et al. Small cell neuroendocrine carcinoma of the ampulla of Vater with foci of squamous differentiation: a case report. *J Hepatobiliary Pancreat Surg* 2004; 11:56-60. [PMID: 15747032]
17. Albores-Saavedra J, Henson DE, Klimstra D. Malignant epithelial tumors of the ampulla. In: Rosai J (eds) Tumors of the gallbladder, extrahepatic bile ducts, and ampulla of Vater. Atlas of Tumor Pathology. Armed Forces Institute of Pathology Washington DC, 2000; 290-293. [PMID: 8293387]
18. Barnhill M, Hess E, Guccion JG, Nam LH, Bass BL, Patterson RH. Tripartite differentiation in a carcinoma of the duodenum. *Cancer* 1994; 73:266-72. [PMID: 8293387]
19. Hu JB, Zhu YH, Jin M, Sun XN. Gastric and duodenal squamous cell carcinoma: metastatic or primary? *World J Surg Oncol* 2013; 11:204. [PMID: 23957943]
20. Kardon DE, Thompson LD, Przygodzki RM, Heffess CS. Adenosquamous carcinoma of the pancreas: a clinicopathologic series of 25 cases. *Mod Pathol* 2001; 14:443-51. [PMID: 11353055]
21. Pathak GS, Deshmukh SD, Yavalkar PA, Ashturkar AV. Coexistent ampullary squamous cell carcinoma with adenocarcinoma of the pancreatic duct. *Saudi J Gastroenterol* 2011; 17:411-3. [PMID: 22064341]
22. Sreenarasimhaiah J, Hoang MP. Esophageal squamous cell carcinoma with metastasis to the ampulla. *Gastrointest Endosc* 2005; 62:310-1. [PMID: 16047006]
23. Buyukcelik A, Ensari A, Sarioglu M, İşikdogan A, İçli F. Squamous cell carcinoma of the larynx metastasized to the ampulla of Vater. Report of a case. *Tumori* 2003; 89:199-201. [PMID: 12841672]
24. Balci B, Calik B, Karadeniz T, Sahin H, Ugurlu L, Aydin C. Primary squamous cell carcinoma of the ampulla of Vater: a case report. *Surg Case Rep* 2016; 2:2. [PMID: 26943678]
25. Bolanaki H, Giatromaolaki A, Sivridis E, Karayiannakis AJ. Primary squamous cell carcinoma of the ampulla of Vater. *JOP* 2014; 15:42-5. [PMID: 24413783]
26. Gupta A, Kumar S, Kumares TS, Gupta S, Makhija M, Singh B. Primary squamous cell carcinoma of the ampulla of Vater-a rare entity. *Inter J Surg* 2009; 2:2.
27. Chen CM, Wu CS, Tasi SL, Hung CF, Chen TC. Squamous cell carcinoma of the ampulla of Vater: a case report. *Changcheng Yi Xue Za Zhi* 1996; 19:253-7. [PMID: 8921644]
28. Whipple AO, Parsons WB, Mullins CR. Treatment of carcinoma of the ampulla of Vater. *Ann Surg* 1935; 102:763-79. [PMID: 17856666]
29. Madjov R, Chervenkov P. Carcinoma of the papilla of Vater. Diagnostic and surgical problems. *Hepatogastroenterology* 2003; 50:621-4. [PMID: 12828046]
30. Annual report of the pathological autopsy cases in Japan, edited by the Japanese Society of Pathology 1992; 34: 1438.
31. Di Giorgio A, Alfieri S, Rotondi F, Prete F, Di Miceli D, Ridolfini MP, Rosa F, et al. Pancreatoduodenectomy for tumors of Vater's ampulla: report on 94 consecutive patients. *World J Surg* 2005; 29:513-518. [PMID: 15776300]
32. Chan C, Herrera MF, de la Garza L, Quintanilla-Martinez L, Vargas-Vorackova F, Richaud-Patín Y, Llorente L, et al. Clinical behavior and prognostic factors of periampullary carcinoma. *Ann Surg* 1995; 222:632-7. [PMID: 7487210]
33. Memon MA, Shiwani MH, Anwer S. Carcinoma of the ampulla of Vater: results of surgical treatment of a single center. *Hepatogastroenterology* 2004; 51:1275-7. [PMID: 15362731]
34. Iemura A, Yano H, Mizoguchi A, Kojiro M. A cholangio cellular carcinoma nude mouse strain showing histologic alteration from adenocarcinoma to squamous cell carcinoma. *Cancer* 1992; 70:415-22. [PMID: 1319814]
35. Honda O, Johkoh T, Sekiguchi J, Tomiyama N, Mihara N, Sumikawa H, Inoue A, et al. Doubling time of lung cancer determined using three-dimensional volumetric software: comparison of squamous cell carcinoma and adenocarcinoma. *Lung Cancer* 2009; 66:211-7. [PMID: 19250697]
36. Wilson DO, Ryan A, Fuhrman C, Schuchert M, Shapiro S, Siegfried JM, Weissfeld J. Doubling times and ct screen-detected lung cancers in the pittsburgh lung screening study. *Am J Respir Crit Care Med* 2012; 185:85-9. [PMID: 21997335]
37. Hong SM, Kim MJ, Jang KT, Yoon GS, Cho H, Frierson HF, Yu E. Adenosquamous carcinoma of extrahepatic bile duct: clinicopathologic study of 12 cases. *Int J Clin Exp Pathol* 2008; 1:147-56. [PMID: 18784802]
38. Yamana I, Kawamoto S, Nagao S, Yoshida T, Yamashita Y. Squamous cell carcinoma of the hilar bile duct. *Case Rep Gastroenterol* 2011; 5:463-70. [PMID: 21960950]
39. Cereda S, Belli C, Reni M. Adjuvant treatment in biliary tract cancer to treat or not to treat? *World J Gastroenterol* 2012; 18:2591-2596. [PMID: 22690066]