

## CASE REPORT

# Missed Opportunity of Diagnosis and Treatment of Primary Hyperparathyroidism Lands Patient to Life Threatening Acute Necrotising Pancreatitis

Suchin Dhamnaskar, Prashant Sawarkar, Sumit Mandal, Preeti Vijayakumaran

Seth G.S. Medical College, King Edward VII Memorial Hospital, Parel, Mumbai, India

### ABSTRACT

**Introduction** We report this case to emphasise the importance of considering primary hyperparathyroidism as a cause of bone disease like pathological fracture and being aggressive in investigating by serum PTH assay and timely treatment. This can prevent future complications like pancreatitis. **Case Report** We present a case of a 30-year-old young lady who had a pathological fracture of distal radius due to primary hyperparathyroidism induced osteoclastic bone resorption. The patient presented to another hospital where malignancy was ruled out by biopsy. But the diagnosis of primary hyperparathyroidism was missed and remained untreated. Four months later she developed life-threatening acute necrotising pancreatitis with multi-organ failure. She could be salvaged but developed diabetes mellitus. After control of the acute state, she underwent parathyroidectomy for definitive treatment. Thus we emphasise the importance of considering primary hyperparathyroidism as a differential diagnosis of pathological bone fracture.

### INTRODUCTION

We report this case to emphasise the importance of considering primary hyperparathyroidism as a cause of bone disease like pathological fracture and being aggressive in investigating by serum PTH assay and timely treatment. This can prevent future complications like pancreatitis.

### CASE REPORT

A Thirty-year-old female patient was transferred from a peripheral hospital with acute necrotising pancreatitis of unknown aetiology for ICU care. On admission patient had severe tachycardia of 122/min, tachypnea of 26/min, hypoxia with 91% oxygen saturation on pulse oximetry, metabolic acidosis with arterial blood gas showing pH-7.26, HCO<sub>3</sub>-16 mmol/L, PaO<sub>2</sub>-72 mmof Hg and PaCO<sub>2</sub>-31 mm of Hg, hypotension of systolic blood pressure 96 mm of Hg and diastolic blood pressure of 74 mm of Hg and oliguria of total urine approximately 350 mL over last 24 hours suggestive of severe systemic inflammatory response syndrome and multisystem involvement. She

had tender and distended abdomen. Serum lipase was 460 U/L more than five times the normal upper limit of 85 U/L. She had neutrophilic leucocytosis of 19,000/mm<sup>3</sup> and lactic acidosis with serum lactate of 10.3 mmol/L. Serum creatinine and liver enzymes were within normal limits. Serum triglyceride levels were normal. Chest X-ray showed bilateral pleural effusion. Ultrasonography of the abdomen showed oedematous, hypoechoic bulky pancreas with surrounding fat stranding. There were no gallstones.

Contrast-enhanced computerised scan (CECT) of chest and abdomen was done to know further morphological details of the pancreas and to get a clue towards aetiology of pancreatitis. It revealed near total pancreatic necrosis. Incidentally, it also picked up two-centimetre sized lesion near left lower thyroid suggestive of left lower parathyroid adenoma (**Figure 1**). The CT also showed lytic lesions in bones at various sites like vertebral bodies and iliac bones (**Figure 2**). Serum calcium was 13.1 mg/dL (normal range-9 to 11). Serum parathyroid hormone level was 928 pg/mL (normal range-15 to 65 pg/mL) which was markedly raised. Thus the diagnosis of hyperparathyroidism related severe acute necrotising pancreatitis was made.

We noticed deformity of right forearm of patient with restricted movements. X-ray showed a malunited fracture of the radius with some lytic lesions around. On further enquiry, she gave a history of fracture of right forearm 4 months ago following trivial trauma due to slipping while getting up from ground. An X-ray then showed suspicious lytic lesions (**Figure 3**) at fracture site suggestive of a pathological fracture. In view of this, she was referred to a dedicated tertiary care cancer hospital, where biopsy was taken from lytic lesions at the fracture site to rule out

Received September 26th, 2016 - Accepted November 11th, 2016

**Keywords** Hyperparathyroidism, Primary; Pancreatitis, Acute Necrotizing; Parathyroidectomy

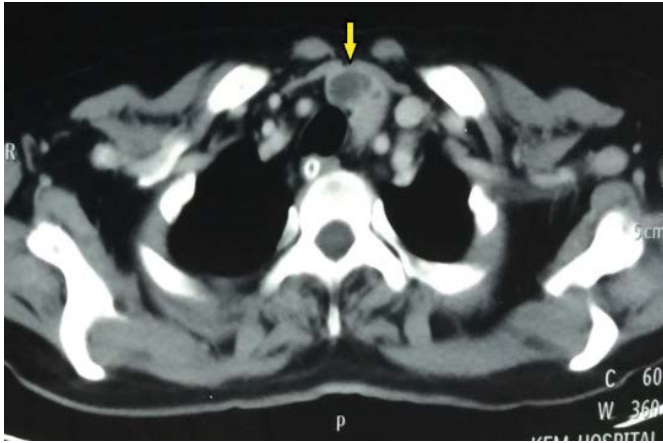**Abbreviations** DEXA dual energy X-ray absorptiometry; PTH parathyroid hormone; PHPT primary hyperparathyroidism; TBS trabecular bone score

**Correspondence** Suchin Dhamnaskar

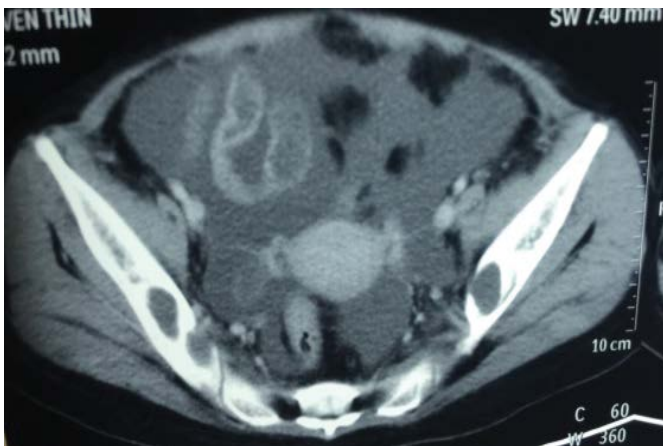
Department of General Surgery  
Seth G.S. Medical College, King Edward VII Memorial Hospital  
Acharya Donde Marg, Parel, Mumbai - 400012  
India

**Tel** + 022 24107000

**E-mail** suchinsd@gmail.com



**Figure 1.** CECT showing left inferior parathyroid adenoma (yellow arrow).



**Figure 2.** CECT image through the pelvis showing lytic lesions in the iliac bones.

malignancy. Biopsy was negative for malignancy. Following this patient was treated conservatively for fracture but the diagnosis of hyperparathyroidism was missed.

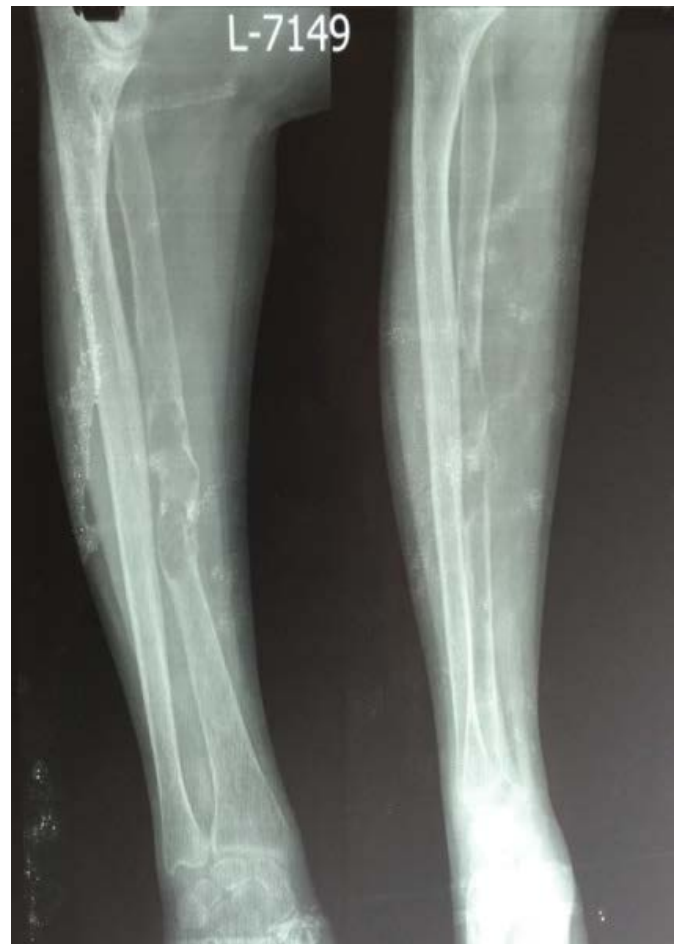The patient had a stormy course in ICU requiring inotropic supports, prolonged respiratory support, broad-spectrum antibiotics to control sepsis and multiple interventions like pleural taps and percutaneous pigtail catheter drainage of infected necrotic collections. The patient did not require any formal surgical procedure like pancreatic necrosectomy or internal drainage procedures and percutaneous image guided catheter drainage of necrotic collections were sufficient. Hypercalcemia was controlled by bisphosphonates. After control of sepsis, the patient was subjected to left lower parathyroidectomy (**Figure 4**). Post parathyroidectomy patient developed 'hungry bone syndrome' (hypocalcaemia due to the rapid uptake of calcium by bones) which was managed by intravenous calcium. The patient had a good recovery after above but developed diabetes as a sequel of pancreatitis. She was discharged 6 weeks later on oral calcium, vitamin D supplements and oral antidiabetic drugs.

## DISCUSSION

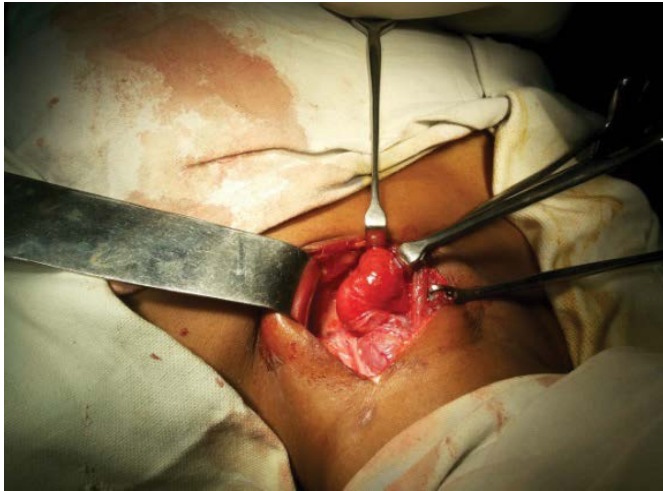
Primary hyperparathyroidism (PHPT) is excessive secretion of parathyroid hormone (PTH) most commonly caused by a single adenoma of one of the four parathyroid glands, but less common causes include parathyroid

hyperplasia, carcinoma and multiple endocrine neoplasia types 1, 2A [1]. PTH causes increased intestinal absorption of calcium, increases renal reabsorption of calcium and causes an increase of osteoclastic activity all of which results in hypercalcemia. Increased osteoclastic activity mobilises calcium from the cortical bones which leads to various skeletal manifestations of PHPT like osteoporosis, osteopenia, lytic lesions, osteoclastomas, pathological fractures or extreme condition termed brown tumours or osteitis fibrosa cystica [2] also known as Von Recklinghausen's disease of bone who described it first. Excessive secretion of PTH causes bone resorption accompanied by fibrovascular marrow replacement and increased osteoblastic activity which manifests as slowly enlarging painful bony mass which mimics malignant bone tumour and eventually leads to pathological fracture. This is locally aggressive but not a true malignancy which can be easily ruled out on cytology or biopsy which shows diffuse proliferation of multinucleated osteoclastic giant cells with fibrovascular stroma. It is called 'brown tumour' due to characteristic reddish brown appearance due to micro-fractures and haemorrhages which release pigment haemosiderin. It reverses completely on the treatment of hyperparathyroidism [3, 4].

Other systemic manifestations of PHPT include nephrolithiasis (calcium oxalate or phosphate stones), nephrocalcinosis, gastrointestinal, cardiovascular,



**Figure 3.** X-ray showing pathological fracture of radius with osteoclastoma, lytic lesion at fracture site.



**Figure 4.** Intraoperative picture of left inferior parathyroid adenoma being excised.

and neuropsychiatric cognitive disorders like anxiety, depression or confusion states. The majority of patients with PHPT have bone affections as a presenting feature. A large group of patients has asymptomatic PHPT which can only be detected by routine ambulatory measurements of serum calcium and/or PTH assay [5]. In the western world, PHPT has become third most common endocrine disease after type 2 diabetes mellitus and thyroid diseases [5, 6, 7].

Causes of pathological fracture of bone include resorption of bone mass (osteoporosis), reduction in bone quality (osteomalacia, osteonecrosis), insufficient bone production (giant cell granuloma, aneurysmal bone cyst), pathological bone remodelling (Paget's disease) or local destruction due to tumour or infection [8]. It needs to be detected clinically, radiologically and cause ascertained by bone biopsy/histopathologically and if needed by metabolic work up. Diagnosis of bone diseases due to PHPT can be done by simple X-rays or skeletal survey in overt cases. Some of the characteristic lesions include 'salt and pepper appearance' of skull bones, subperiosteal bone resorption of cortical bones and distal phalanges, osteopenia, osteoclastomas and pathological fractures. Distal one-third of the radius is particularly important site due to catabolic effect of PTH on predominantly cortical bone [9, 10]. Other diagnostic tools include bone mineral density, DEXA (dual energy X-ray absorptiometry), high-resolution CT scan and trabecular bone score (TBS).

The association between PHPT and acute pancreatitis is controversial but pooled clinical and experimental data is suggestive of such association and implicate hypercalcemia. Hence it is prudent to consider PHPT in patients with unexplained pancreatitis. Probable mechanism being hypercalcemia inducing premature activation of pancreatic proteases leading to pancreatitis [11]. The most common cause of hypercalcemia is PHPT [1, 12]. PHPT induced acute pancreatitis needs to be managed on the same principles with supportive acute care as pancreatitis of any other etiology [13]. Hypercalcemia during the acute phase is controlled by bisphosphonates, calcitonin and all these

patients should undergo parathyroidectomy for definitive treatment of PHPT. Parathyroid surgery is an appropriate treatment in asymptomatic patients with PHPT too unless contraindicated due to medical reasons as surgery controls hypercalcemia effectively and improves bone mineral density [14].

In our case, accurate and timely diagnosis and treatment of PHPT, at the prior presentation with pathological fracture of the distal third of radius would have controlled hypercalcemia effectively and avoided life-threatening severe acute necrotising pancreatitis. The patient developed diabetes mellitus post pancreatitis at a young age of 30 years with the risk of long-term end organ injury which could have been completely avoided by timely diagnosis and treatment of PHPT.

## CONCLUSION

This case report emphasises the importance of timely diagnosis and treatment of PHPT to avoid its complications. One should have a high index of suspicion in pathological fracture or other bone diseases and subject these patients to calcium and PTH assay because the bone disease is the usual presentation of hyperparathyroidism. Similarly, when aetiology of pancreatitis is not obvious one should consider or rule out hyperparathyroidism by PTH assays. Early diagnosis and treatment of hyperparathyroidism can prevent future complications or morbidity.

## Conflict of Interest

All authors declare having no conflict of interests or financial disclosures.

## References

1. Fraser WD. Hyperparathyroidism. *Lancet* 2009; 374:145-158. [PMID: 19595349]
2. Health H 3rd. Critical spectrum of primary hyperparathyroidism: evolution with changes in medical practice and technology. *J Bone Miner Res* 1991; 6:S63-S70. discussion:S83-S84. [PMID: 1763671]
3. Atabek ME, Pirgeon O, Sert A, Esen HH. Extensive brown tumours caused by parathyroid adenoma in an adolescent patient. *Eur J Paediatr* 2008; 167:117-119. [PMID: 17273830]
4. Parfitt AM. Parathyroid hormone and periosteal bone expansion. *J Bone Miner Res* 2002; 17:1741-43. [PMID: 12369776]
5. Bilezikian JP, Silverberg SJ. Clinical practice. Asymptomatic primary hyperparathyroidism. *N Engl J Med* 2004; 350:1746-1751. [PMID: 15103001]
6. Adami S, Marcocci, Gatti D. Epidemiology of primary hyperparathyroidism in Europe. *J Bone Miner Res* 2002; 17:N18-N23. [PMID: 12412773]
7. Warmer RA, Khosla S, Atkinson EJ, Achenbach SJ, Oberg AL, Grant CS, Melton LJ 3rd. Incidence of primary hyperparathyroidism in Rochester, Minnesota, 1993-2001- An update on changing epidemiology of the disease. *J Bone Miner Res* 2006; 21:171-177. [PMID: 16355286]
8. Adler CP. Pathologic bone fracture: definition and classification. *Langenbecks Arch Chir Suppl* 11 Verh Disch Ges Chr 1989; 489-486. [PMID: 2577585]

9. Bandeira F, Cusano NE, Silva BC, Cassibba S, Almeida BC, Machado VC, Bilezikian JP. Bone disease in primary hyperparathyroidism. *Arq Bras Endocrinol Metabol* 2014; 58:553-561. [PMID: 25166047]
  10. Silva BC, Costa AG, Cusano NE, Kousteni S, Bilezikian JP. Catabolic and anabolic actions of parathyroid hormone on skelton. *J Endocrinol Invest* 2011; 34:801-810. [PMID: 21946081]
  11. Bai HX, Giefer M, Patel M, Husain SZ. The association of primary hyperparathyroidism with pancreatitis. *J Clin Gastroenterology* 2012; 46:656-661. [PMID: 22874807]
  12. Al-Azem H, Khan A. Primary hyperparathyroidism. *CMAJ* 2011; 183:E685-E689. [PMID: 21540163]
  13. Frossard JL, Steer ML, Pastor CM. Acute pancreatitis. *Lancet* 2008; 371: 143-152. [PMID: 18191686]
  14. Silverberg SJ, Shane E, Jacobs TP, Siris E, Bilezikian JP. A 10 Year Prospective Study of Primary Hyperparathyroidism with or without Surgery. *N Engl J Med* 1999; 341:1249-1255. [PMID: 10528034]
-