

REVIEW ARTICLE

Middle Preserving Pancreatectomy: A Viable Option for Parenchyma Preserving Pancreatic Resection

Vikas Gupta¹, Vikash Moond¹, Santhosh Irrinki¹, Ashwini Sood², Ajay Gulati³, Amanjit Bal⁴, KimVaiphei⁴, Saroj K Sinha⁵, Rakesh Kochhar⁵

Department of General Surgery¹, Nuclear Medicine², Radiodiagnosis³, Pathology⁴ and Gastroenterology⁵, Postgraduate Institute of Medical Education and Research, Chandigarh 160012, India

ABSTRACT

Background Multicentric pancreatic neoplasm offers a unique challenge to the surgeon with respect to the surgical procedure to be performed. Traditionally total Pancreatectomy was considered as the standard treatment in these patients. But due to the inevitable pancreatic state associated with the procedure alternative parenchyma sparing pancreatic surgeries have evolved as effective options. Middle preserving pancreatectomy is one such option when the pancreatic body is unaffected by any pathology. **Methodology** Two patients with multi centric pancreatic tumors who underwent middle preserving pancreatectomy for suspected neuroendocrine tumor were reviewed. We have also reviewed the English literature and found 26 cases of middle preserving pancreatectomy. The demographic, intra-operative and postoperative morbidity, mortality and the risk of pancreatic insufficiency associated with the procedure were evaluated. **Results** The overall morbidity was 32.1% (9/28), pancreatic fistula rate 17.8% (5/28), risk of re-operation estimated as 3.5% (1/28). There was no perioperative mortality. The rate of endocrine and exocrine insufficiency to be 25% (7/28) and 17.8% (5/28), respectively. The reported length of remnant pancreas has varied between 2cm to 8 cm. There has been no reported case of pancreatic remnant necrosis and disease recurrence in the remnant pancreas on follow up. **Conclusion** Middle preserving pancreatectomy is a feasible, safe and effective alternative in carefully selected patients with benign or low grade multicentric pancreatic neoplasms.

INTRODUCTION

Multicentric pancreatic neoplasm though rare can be encountered in patients with neuroendocrine tumors, cystic neoplasms, synchronous pancreatic adenocarcinoma or metastatic lesion from other organs [1]. These lesions offer a unique challenge to the surgeon with respect to the surgical procedure to be performed. The balance between radical resection and post-operative quality of life has to be considered. Conventionally total Pancreatectomy was the surgical option for multi focal pancreatic neoplasm, however it is associated with impaired functional outcome in terms of long term exocrine and endocrine insufficiency [2]. Parenchyma preserving pancreatic resection for multiple and low grade lesion has been described to circumvent the functional consequences associated with total pancreatectomy. These may vary from enucleation to segmental resection to preservation of small pancreatic segment. Middle preserving pancreatectomy is an attractive

option in such patients [3]. Ever since its first description in 1999, only 26 cases has been reported in the English literature so far. Middle Preserving Pancreatectomy is a rare surgical procedure mainly due to lack of suitable cases. We hereby report our experience with two cases of middle preserving pancreatectomy performed over a period of seven years.

METHODOLGY AND RESULTS

The present study describes two patients who underwent Middle preserving Pancreatectomy for multi centric pancreatic neoplasm. From January 2011 to December 2017 two patients undergoing middle preserving pancreatectomy were reviewed retrospectively. Demographic, biochemical, radiological, operative and follow up data were retrieved. During the study period a total of 308 pancreatic resection were performed which included 276 pancreatico-duodenectomies, 27 distal pancreatectomies and 3 middle pancreatectomies. The incidence of Middle Preserving Pancreatectomy was 0.6%

Both patients had almost identical presentation. Both were young females with clinical presentation of intermittent paroxysmal hypertension along with elevated urine and serum catecholamine level. One of them was a diabetic (**Table 1**).

Received March 04th, 2018 - Accepted June 25th, 2018

Keywords Pancreatic Neoplasms; Paraganglioma

Correspondence Vikas Gupta

Postgraduate institute of medical education and research

General surgery, sector 12

chandigarh, 160012, India

Tel + 9872041120

E-mail vikaspgi@gmail.com

Table 1: Clinical Details of Patients undergoing MPP in our Institute.

	Case #1	Case #2
Age	37 Y	19 Y
Sex	Female	Female
Clinical presentation	Diffuse, dull aching abdominal pain and intermittent, throbbing occipital headache	Intermittent paroxysmal hypertension and pain abdomen
Duration of symptom	6 months	1 month
Loss of weight and appetite	Present	Absent
Co-morbidity	Type II DM(on OHA) Hypertensive	Hypertensive
Serum chromogranin	436 ng/mL	546 ng/mL
Urinary nor metanephrines	637	887
Urinary nor-metanephrines creatinine ratio	2422 microg/g creatinine	246 microg/g creatinine
HbA1c	6.2	5.4
C peptide	1.1	NA
Imaging Findings		
Biphasic CECT abdomen (Figure 1)	8.6 × 4 × 3.8 cm heterogenously enhancing lobulated mass in right adrenal gland with Venous phase washout. Similar arterial hyperen-hancing lesion in head & uncinate (4.3 × 3.8 × 4.4 cm), body (1.3 × 1.1 cm) and tail (4 × 3.5 × 2 cm) of pancreas	6.7 × 3 × 2.8 cm and 3 × 4.2 × 4 cm heterogenously enhancing mass in right and left adrenal gland respectively. Arterial hyperenhancing lesion in head of pancreas closely adhered to duodenum(1.9 × 2.4 cm) with similar small lesion in its vicinity and (1.5×2 cm) lesion in tail of pancreas
DOTATATE scan (Figure 2)	Increased tracer uptake in hetero-genously enhancing lesion in right supra-renal location (suv-7.6). Increased uptake in enhancing lesion in head of pancreas(suv 14.6) and also tracer avid lesion in the body & tail of pancreas	Somatostatin receptor expressing lesion in the head of pancreas. Similar somatostatin receptor expressing masses in both adrenal gland
Intra-Operative Findings (Figures 3&4)		
Intra-operative time	270 min	300 min
Blood loss	300 mL	200 mL
Pancreatic head	<ul style="list-style-type: none"> Multiple lesion present (largest 2 × 2 cm) which were infiltrating the duodenum Pancreatico-duodenectomy was performed 	<ul style="list-style-type: none"> 3 lesion (2 × 1 cm and 1 × 1 cm) in the head and uncinate process. Another 1 × 0.8 cm lesion close to duodenum Pancreatico-duodenectomy was done
Pancreatic body	<ul style="list-style-type: none"> solitary lesion present in the proximal body 2 cm distal to the head lesion Intra-operative ultrasound revealed lesion in close proximity to the pancreatic duct not suitable for enucleation Proximal body of pancreas resected 	<ul style="list-style-type: none"> Normal
Pancreatic tail	<ul style="list-style-type: none"> Multiple small lesion in the tail Adherent to anterior surface of splenic vessel Distal pancreatectomy and splenectomy carried out 	<ul style="list-style-type: none"> 2 × 2 cm tail lesion present Spleen preserving distal pancreatectomy done
Adrenal gland	(R) adrenalectomy performed	Bilateral adrenalectomy performed
Remnant pancreas length	6 cm	8 cm
Reconstruction technique	Proximal end- pancreaticojejunostomy (Dunking technique) Distal end- Stapled transection	Proximal end- pancreaticojejunostomy (duct to mucosa technique) Distal end- Stapled transection
Post-operative course	Uneventful	Uneventful
Postoperative hospital stay	8 days	10 days
Histopathology	<ul style="list-style-type: none"> Pancreatic lesions- paraganglioma NOS. Resection margins-negative. 16 lymph nodes- negative of tumor. Adrenal gland- pheochromocytoma 	<ul style="list-style-type: none"> Acinar cell carcinoma with islet cell microadenoma in the head and tail of pancreas All lymph node free Adrenal gland- pheochromocytoma
Follow Up		
Duration	8 months	3 year
Long term complications	No exocrine insufficiency No worsening of diabetes	No exocrine and endocrine insufficiency
HbA1C	6.20%	5.70%
C peptide	0.590 ng/mL*	1.8 ng/mL
Insulin levels	2.8 microU/mL	3.8 microU/mL
Serum chromogranin	65 ng/mL	56 ng/mL
DOTATATE scan	No abnormal hypermetabolism	No abnormal hypermetabolism

*Though there was decrease in C-peptide levels there was no Clinical worsening of Diabetes

On imaging both had hyper-vascular lesion in the head and uncinate process of pancreas and similar lesion in the tail. One of them had similar nodule in the pancreatic body as well. Both had adrenal lesions suggestive of pheochromocytoma; one of the patients had bilateral disease. Both the patients underwent Middle Preserving Pancreatectomy and Adrenalectomy and both had an uneventful recovery (Figures 1 and 2).

Technique of Middle Preserving Pancreatectomy

After a rooftop incision, the peritoneal cavity was carefully explored and the pancreas was exposed. A standard Antrum preserving pylorus ring excision-pancreaticoduodenectomy was performed towards the head lesion. For the distal lesion, care was taken to preserve the dorsal pancreatic artery. A spleen-preserving distal pancreatectomy with careful dissection of the splenic vessels was done in one patients, while the other one with a large lesion impinging upon the splenic hilum, concomitant splenectomy was performed. In the patient where splenectomy was performed, the splenic vessels were ligated at the level of distal pancreatic transection. Both proximal and distal resection margins were confirmed free of malignancy on frozen section. The distal pancreatic stump was closed using a linear stapler. Care should be taken in leaving at least 5 cm of pancreatic remnant which was 6 and 8cm in the two index cases. The proximal end

of the pancreatic stump was anastomosed end-to-side to a Roux-en-Y jejunal loop. An end-to-side hepaticojejunostomy and gastrojejunostomy were performed in same order over a single jejunal loop. Figures 3 and 4 shows the end result of the surgical procedure.

Literature Search Strategy

A PubMed search was made using the key words Middle preserving pancreatectomy, Center preserving Pancreatectomy, Multicentric pancreatic lesions, Parenchyma preserving Pancreatectomy and the resultant articles dating between 1999 to December 2017 were scrutinized and 16 full text articles were systematically reviewed in the present analysis. Out of the 16 articles reviewed, four were case series and remaining 12 were single case reports.

Literature Analysis

In the present study a total of 28 patients data were retrieved and analysed (including two from present study). For patients operated after 2007, the complications such as pancreatic fistula, delayed gastric emptying and post pancreatectomy haemorrhage were classified in accordance with the ISGPS definitions [4]. The mean age of the study group was 56.85 years (19-83 years), female to male ratio was 1:1.07. In the present review the most common indication for Middle Preserving Pancreatectomy

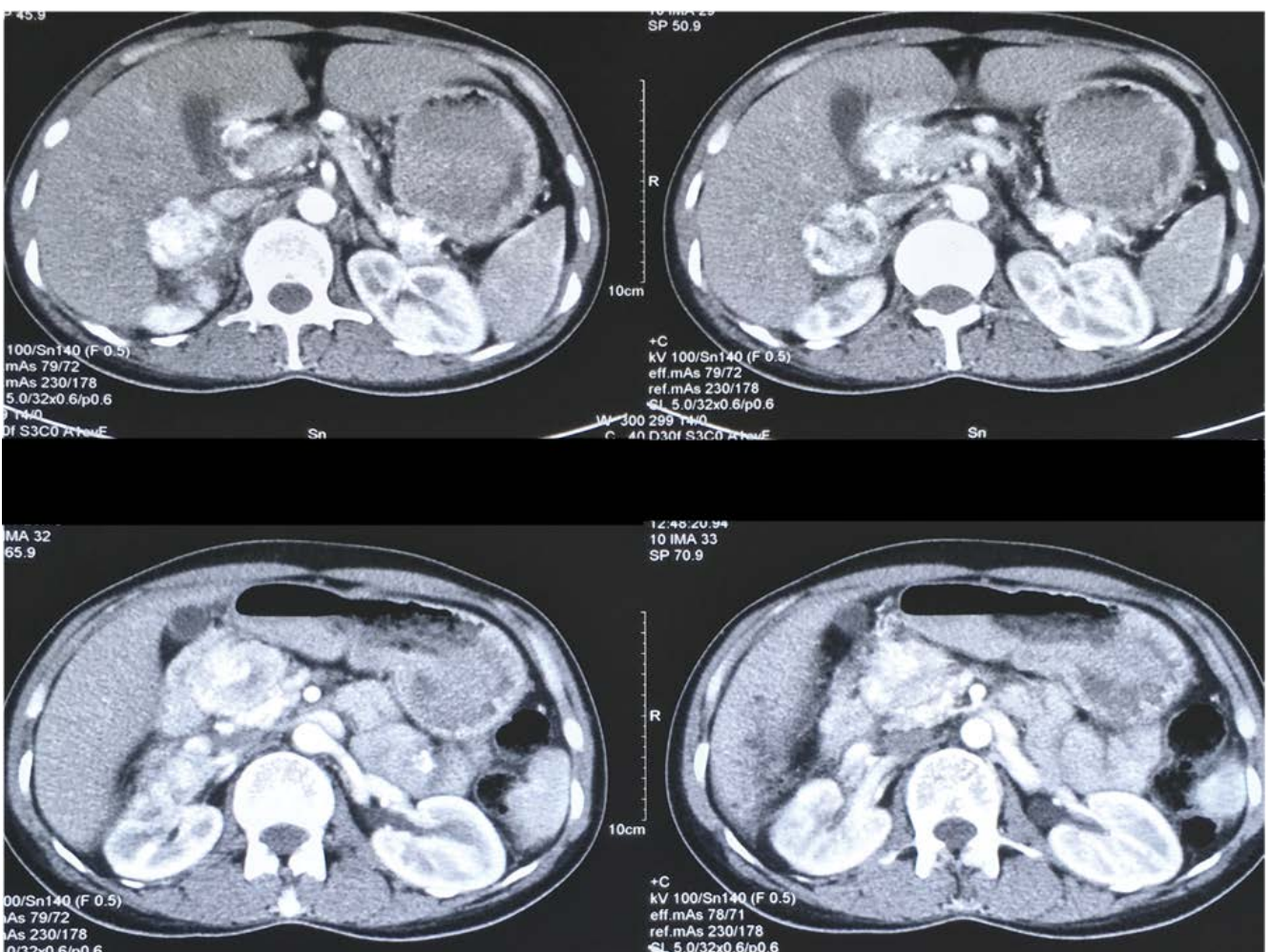


Figure 1. CECT with hyperenhancing lesion in the head and right adrenal gland (case #1)

was Intraductal Papillary Mucinous Neoplasm (10) and other indications were Pancreatic Endocrine tumors (4), Solid Pseudopapillary neoplasms(3), Metastatic Renal Cell carcinoma (3), chronic pancreatitis (3), pancreatic ductal adenocarcinoma (2), serous cystic neoplasm (1).

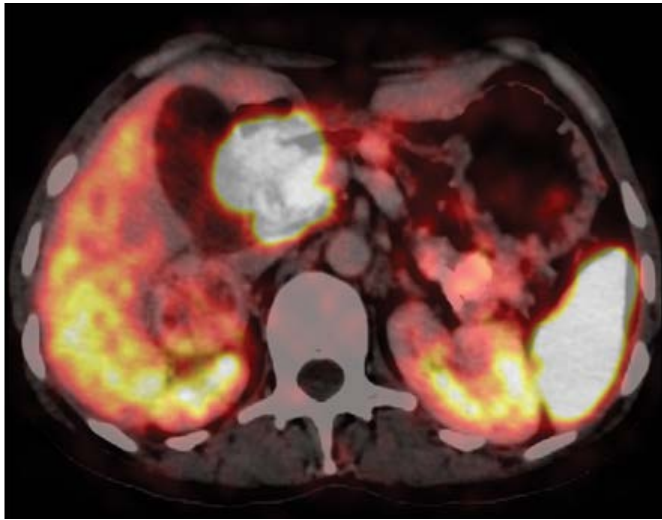


Figure 2. DOTA scan with tracer avid lesion in the head of pancreas (case #1)

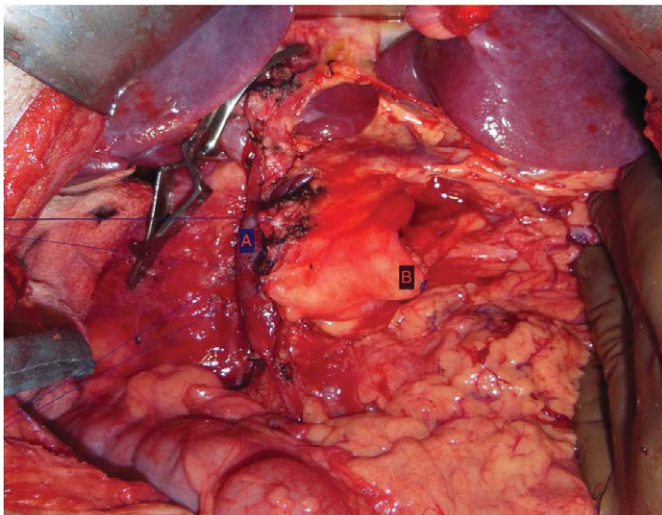


Figure 3. Intraoperative photograph of the pancreatic remnant (case #1). (a). Proximal end of pancreatic stump prepared for intestinal anastomosis. (b). Distal stapled end of pancreatic stump

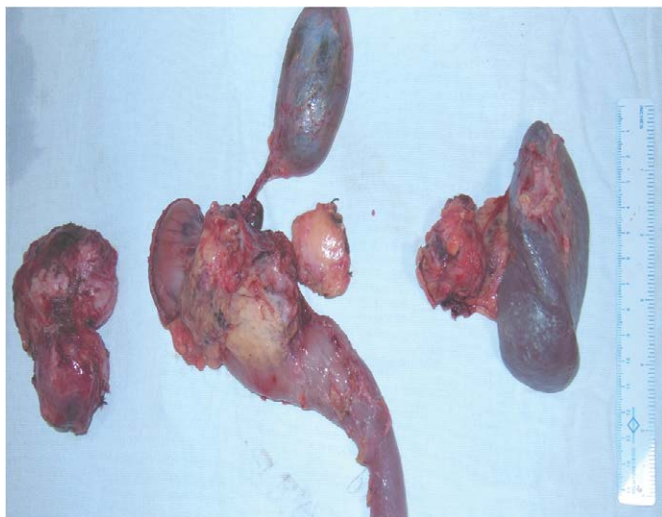

Figure 4. photograph of resected specimen (case #1)

22 patients underwent one stage Middle Preserving Pancreatectomy while the remaining six patients underwent the surgery in two stages. The mean length of pancreatic remnant to be 5.5 cm (2-8 cm). In the present analysis we found the overall morbidity to be 32.1% (9/28), Pancreatic fistula rate was 21.4% (6/28) of which 7.14% (2/28) were grade A and 14.2% (4/28) was grade B. One patient had grade A delayed gastric emptying, while 2 patients had postoperative haemorrhage which was managed by coil embolization of the splenic artery in one and surgical reexploration in another. There have been no reports of peri-operative mortality or necrosis of the remnant pancreas till now. We found the rate of endocrine and exocrine insufficiency to be 25% (7/28) and 17.8% (5/28) respectively (**Table 2**).

DISCUSSION

Siassi *et al.* in 1999 first described a two staged middle preserving pancreatectomy in a patient with metachronous pancreatic adenocarcinoma who previously underwent distal pancreatectomy [5]. In 2007 Miura *et al.* reported first single stage Middle Preserving Pancreatectomy with successful outcome [6]. Ever since only 26 cases have been reported [7, 8, 9, 10, 11, 12, 13, 14, 15].

Middle preserving pancreatectomy is a rare surgical procedure, mainly due to lack of suitable cases. Middle preserving pancreatectomy should be avoided in patient with pancreatic ductal adenocarcinoma due to inability to perform proper lymphadenectomy and compromise of resection margins [16]. Middle preserving pancreatectomy has been considered preferable in patients with benign, borderline or low grade malignancies with multicentricity. MPP should be converted to an oncologically appropriate operation if inadequate tumor resections are encountered intraoperatively (**Figure 5**).

Middle preserving pancreatectomy has two potential sources of pancreatic fistula - pancreato-intestinal anastomotic site and stapled distal end of pancreatic remnant. So, theoretically can be considered to be at a higher risk of pancreatic fistula and perioperative morbidity. Perioperative morbidity and mortality associated with pancreatoduodenectomy and distal pancreatectomy are 38-44%, 1-4% and 13-54%, 0-4% respectively [17, 18, 19, 20, 21] which is comparable to Middle Preserving Pancreatectomy. In a recent meta-analysis, total pancreatectomy was associated with an overall morbidity and mortality of 31.1-57.1% and 1.6-9.2% respectively with inevitable exocrine and endocrine insufficiency [22].

Dorsal pancreatic artery is the major supply to the pancreatic remnant and care should be exercised to preserve it [16]. This can be achieved by performing careful lymphadenectomy at the level of celiac and splenic artery. Both the patients in the present study had an uneventful recovery; this was probably due to the better preservation of blood supply of pancreatic remnant.

Table 2. Review and Analysis of all the patients included in the Study.

S no.	Author/year	One/ two stage	Age/ sex	Primary pathology and location	Surgery	Pancreatic remnant length (cm)	Morbidity	Mortality	Endocrine insufficiency	Exocrine insufficiency	Long term follow up (months)
1	Siassi <i>et al.</i> (1999) [5]	Two	62/F	Body/tail (PDAC/PDAC)	PPPD after previous DP	5	No	No	Yes	Yes	DF(12)
2	Llyod <i>et al.</i> (2003) [7]	Two	31/F	Head/body/tail (SPN/SPN/SPN)	PPPD/DP	2	Pseudocyst	No	No	No	DF(17)
3	Miura <i>et al.</i> (2007) [6]	Two	66/M	Head/tail (bIPMN/PDAC)	PD/DP	4	No	No	No	No	DF(20)
4	Miura <i>et al.</i> (2007)	Two	66/M	Head/tail (Ampullary carcinoma /IPMN)	PPPD/DP	5	No	No	No	No	DF(10)
5	Miura <i>et al.</i> (2007)	One	72/M	Head/tail (Ampullary carcinoma/bIPMN)	PPPD/DP	6	POPF(grade B)	No	No	No	DF(6)
6	Partelli <i>et al.</i> (2009) [8]	One	28/M	Head/tail (NF-PET/NF-PET)	PPPD/DP	NA	POPF (grade A)	No	No	Yes	DF (118)
7	Partelli <i>et al.</i> (2009)	One	32/M	Head/tail (NF-WDEC/NF-WDEC)	PPPD/DP	NA	No	No	No	No	DF(22)
8	Partelli <i>et al.</i> (2009)	One	70/M	Head/tail (bIPMN/bIPMN)	PPPD/DP	NA	No	No	Yes	Yes	DF(20)
9	Partelli <i>et al.</i> (2009)	One	35/F	Head/tail (bIPMN/CP)	PPPD/DP	NA	No	No	No	No	DF(18)
10	Partelli <i>et al.</i> (2009)	One	60/F	Head/tail (Retention cyst/CP)	PD/DP	NA	No	No	Yes	Yes	DF(14)
11	Chiang <i>et al.</i> (2009) [9]	One	72/M	Head/body/tail (mixIPMN/bIPMN/bIPMN)	Extended PD/DP	7	No	No	No	No	DF(36)
12	Sperti <i>et al.</i> (2010) [1]	one	59/M	Head/tail (mixIPMN/CP)	PPPD/ spleen preserving DP		Bleeding (splenic artery embolization)	No	yes	No	DF(11)
13	Ohzato <i>et al.</i> (2010) [9]	one	67/F	Head/body tail (metastatic RCC)	Extended PPPD/DP	NA	Bleeding (re-operation)	No	Yes	No	DF(30)
14	Kitasato <i>et al.</i> (2010) [11]	one	65/F	Head/body/tail (metastatic RCC)	IPHR/DP	40% volume	No	No	No	No	DF(31)
15	Chen <i>et al.</i> (2011) [2]	One	63/F	Head/tail (ampullary carcinoma/ SPN)	PD/DP	NA	No	No	No	No	DF(6)
16	Horiguchi <i>et al.</i> (2011) [12]	One	69/M	Head/tail (bIPMN/bIPMN)	IPHR/DP	NA	POPF(grade B)	No	No	No	Dead(16)
17	Horiguchi <i>et al.</i> (2011)	One	67/F	Head/tail (gastrinoma/ gastrinoma)	DPPHR/DP	5	POPF(grade B)	No	No	No	DF(77)
18	Horiguchi <i>et al.</i> (2011)	One	69/M	Head/tail (bIPMN/bIPMN)	IPHR/DP	NA	POPF(grade B)	No	Yes	No	DF(14)
19	Horiguchi <i>et al.</i> (2011)	One	83/F	Head tail (bile duct cancer/ bIPMN)	SSPPD/DP	7	No	No	No	No	DF(7)
20	Otani <i>et al.</i> (2011) [13]	one	77/M	Head/tail (bIPMN/mainIPMN)	PPPD/DP	6	No	No	No	No	DF(84)
21	Noda <i>et al.</i> (2011) [14]	One	NA	Head/tail(advanced colon cancer/PET)	NA	6	POPF(grade B)	No	No	No	DF(71)
22	Cheng <i>et al.</i> (2013) [3]	One	24/F	Head/tail (SPN/SPN)	PD/DP	6	NO	No	Yes	Yes	DF(36)
23	Cheng <i>et al.</i> (2013)	One	36/F	Head/tail(SCN/SCN)	PD/DP	5	DGE(grade A)	No	No	No	DF(6)
24	Takeshi <i>et al.</i> (2014) [15]	Two	61/M	Head/tail (metastatic RCC)	PD/DP	3	No	No	No	No	DF(24)
25	Nishi <i>et al.</i> (2014) [16]	one	76/M	Head/tail (mainIPMN/ mainIPMN)	SSPPD/DP	8	No	No	No	No	DF(9)
26	Yamada <i>et al.</i> (2017) [17]	Two	70/M	Head/tail (bIPMN/IPMN)	PD/DP	6	No	No	No	No	DF(36)

27	Present case	One	36/F	Head/body/tail (pancreatic paraganglioma)	PD/DP	6	No	No	No	No	DF(8)
28	Present case	One	19/F	Head/tail (acinar cell carcinoma)	PD/spleen preserving DP	8	No	No	No	No	DF(60)
22-one stage 6- two stage							Morbidity- 32.1%	Mortality- 0%	Endocrine insufficiency- 25%	Exocrine insufficiency- 17.8%	

bIPMN - branch duct intraductal papillary mucinous neoplasm; CP - chronic pancreatitis; DGE- delayed gastric emptying; DPPHR - duodenum preserving pancreatic head resection; IPHR - inferior pancreatic head resection; IPMN - intraductal papillary mucinous neoplasm; LP - left pancreatectomy; NA - not available; NF-PET - nonfunctioning pancreatic endocrine tumor; NF-WDEC - nonfunctioning well differentiated endocrine carcinoma; PD - pancreatoduodenectomy; PDAC Pancreatic ductal adenocarcinoma; POPF - post-operative pancreatic fistula; PPPD- pylorus preserving pancreatoduodenectomy; SCN - serous cystic neoplasm; SPN - solid pseudopapillary neoplasm; SSPPD - sub stomach preserving pancreatoduodenectomy

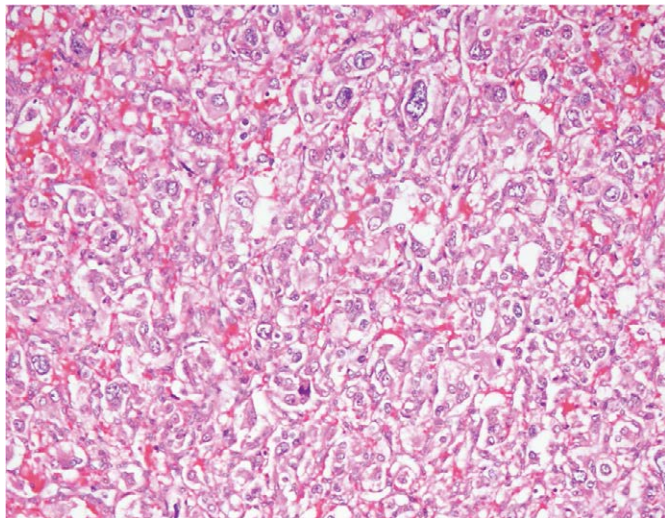


Figure 5. medium power photomicrograph of the tumour showing cells with monomorphic nuclei with finely stipple chromatin. The cells are dominantly arranged in trabeculae and cords, occasionally with acinar pattern separated by fine fibrovascular stroma. (H&E, x400) (case #1)

There are no consensus regarding the optimal length of pancreatic remnant to prevent pancreatic insufficiency. Clinically significant pancreatic insufficiency results from 80-90% loss of pancreatic parenchyma [23]. To prevent pancreatic insufficiency Miura et al. proposed preservation of at least 25% pancreatic parenchyma [6]. Yasuda *et al.* analyzed the volume of middle portion of pancreas to be 25% of the gland based on CT pancreatic volumetric [24]. Theoretically middle preserving pancreatectomy should preserve enough pancreas to preclude development of exocrine and endocrine insufficiency. The length of pancreatic remnant predicted to prevent exocrine and endocrine insufficiency has been estimated to be at least 5-6 cm, as this length approximates to about 35-40% of the gland. Moreover middle preserving pancreatectomy preserves glucagon secreting alpha cells located mainly in the body of pancreas and reduce risk of brittle diabetes [1]. In our analysis we found even the patient with small remnant pancreas (2 cm) did not develop pancreatic insufficiency at 17 months follow up.

Pancreatic pathology involving the head and tail definitely has the potential of involving the pancreatic body. There is a risk of residual or recurrent disease in the remnant pancreas. In order to avoid the recurrence in

the remnant pancreas after MPP, appropriate candidates should be selected through careful preoperative evaluation of malignant potential, and intraoperative frozen section analysis of the two resection margins. Furthermore, intraoperative ultrasound would be helpful to identify all of the lesions and to confirm that the remnant was disease free. There have been no reports of disease recurrence in the remnant pancreas after middle preserving pancreatectomy. However the patient should be kept on regular follow up to detect early recurrence.

CONCLUSION

Concluding, middle preserving pancreatectomy is a feasible, safe and effective alternative in carefully selected patients with benign or low grade multicentric pancreatic neoplasms. The procedure can be performed with acceptable morbidity and no mortality with a good long term functional outcome.

Conflicts of Interest

There are no conflicts of interest.

References

- Sperti C, Polizzi ML, Moro M, Beltrame V, Pedrazzoli S. Middle-preserving pancreatectomy: an interesting procedure for pancreas-sparing resection. *JOP* 2010; 11:258-61. [PMID: 20442523]
- Chen HW, Wang FJ, Lai EC, Lau WY. Middle-preserving pancreatectomy for synchronous ampullary carcinoma and solid-pseudopapillary tumor of distal pancreas. *Int J Surg Case Rep* 2011; 2:267-8. [PMID: 22096749]
- Cheng K, Shen BY, Peng CH, Na LM, Cheng DF. Middle-preserving pancreatectomy: report of two cases and review of the literature. *World J Surg Oncol* 2013; 11:106. [PMID: 23702284]
- Pratt WB, Maithel SK, Vanounou T, Huang ZS, Callery MP, Vollmer Jr CM. Clinical and economic validation of the International Study Group of Pancreatic Fistula (ISGPF) classification scheme. *Ann Surg* 2007; 245:443. [PMID: 17435552]
- Siassi M, Klein P, Hohenberger W. Organ-preserving surgery for multicentric carcinoma of the pancreas. *Eur J Surg Oncol* 1999; 25:548-550. [PMID: 10527608]
- Miura F, Takada T, Asano T, Kenmochi T, Ochiai T, Amano H, et al. Hemodynamic changes of splenogastric circulation after spleen-preserving pancreatectomy with excision of splenic artery and vein. *Surgery* 2005; 138:518-22. [PMID: 16213907]

7. Lloyd FP Jr, Kang J. Multifocal papillary-cystic neoplasm of the pancreas. *J Natl Med Assoc* 2003; 95:1204–1207. [PMID: 14717478]
8. Partelli S, Boninsegna L, Salvia R, Bassi C, Pederzoli P, Falconi M. Middle-preserving pancreatotomy for multicentric body-sparing lesions of the pancreas. *Am J Surg* 2009; 198:e49-53. [PMID: 19716880]
9. Chiang KC, Hsu JT, Chen HY, Jwo SC, Hwang TL, Jan YY, et al. Multifocalintraductal papillary mucinous neoplasm of the pancreas – a case report. *World J Gastroenterol* 2009; 15:628-632. [PMID: 19195068]
10. Ohzato H, Yamamoto T, Fukunaga M, Imamura H, Furukawa H. Middlepreserving pancreatotomy for multifocal metastatic renal cell carcinoma located in the head, body and tail of the pancreas. A case report. *JOP* 2010; 11:633–637. [PMID: 21068502]
11. Kitasato A, Tajima Y, Kuroki T, Tsutsumi R, Tsuneoka N, Adachi T, et al. Limited pancreatotomy for metastatic pancreatic tumors from renal cell carcinoma. *Hepatogastroenterology* 2010; 57:354–357. [PMID: 20583442]
12. Horiguchi A, Ishihara S, Ito M, Asano Y, Furusawa K, Yamamoto T, et al. Middle-segment-preserving pancreatotomy for biliary-pancreatic tumors. *Hepatogastroenterology* 2011; 58:1018–1021. [PMID: 21830434]
13. Otani T, Enami Y, Tanaka K, Kusano T, Maeshiro T, Umekita N, et al. Simultaneous pancreaticoduodenectomy and distal pancreatotomy for two IPMNs in the head and the tail. *Pancreas* 2011; 40:165–167. [PMID: 21160379]
14. Noda H, Kato T, Kamiyama H, Toyama N, Konishi F. Middle-preserving pancreatotomy for advanced transverse colon cancer invading the duodenum and non-functioning endocrine tumor in the pancreatic tail. *Clin J Gastroenterol* 2011; 4:24-7. [PMID: 26190617]
15. Takeshi A, Mitsuhiro I, Hiromitsu A, Naoyuki Y, Taiichiro S, Hiroki S, et al. Middle segment-preserving pancreatotomy for recurrent metastasis of renal cell carcinoma after pancreatoduodenectomy: a case report. *Case Rep Surg* 2014; 2014:648678. [PMID: 25061531]
16. Nishi M, Kawasaki H, Fujii M, Nagahashi M, Obatake M, Shirai M, et al. Middle-preserving pancreatotomy for multifocal intraductal papillary mucinous neoplasms of the pancreas: report of a case. *Clin J Gastroenterol* 2014; 7:251-4. [PMID: 24883129]
17. Yamada M, Sugiura T, Okamura Y, Ito T, Yamamoto Y, Ashida R, et al. Middle segment-preserving pancreatotomy for metachronous intraductal papillary mucinous neoplasm after pancreatoduodenectomy: a case report. *Surg Case Rep* 2017; 3:28. [PMID: 28197897]
18. Kawai M, Kondo S, Yamaue H, Wada K, Sano K, Motoi F, et al. Predictive risk factors for clinically relevant pancreatic fistula analyzed in 1,239 patients with pancreaticoduodenectomy: multicenter data collection as a project study of pancreatic surgery by the Japanese Society of Hepato-Biliary-Pancreatic Surgery. *J Hepatobiliary Pancreat Sci* 2011; 18:601-8. [PMID: 21491103]
19. Schmidt CM, Powell ES, Yiannoutsos CT, Howard TJ, Wiebke EA, Wiesenauer CA, et al. Pancreaticoduodenectomy: a 20-year experience in 516 patients. *Arch Surg* 2004; 139:718–25. [PMID: 15249403]
20. Knaebel HP, Diener MK, Wente MN, Büchler MW, Seiler CM. Systematic review and meta-analysis of technique for closure of the pancreatic remnant after distal pancreatotomy. *Br J Surg* 2005; 92:539–46. [PMID: 15852419]
21. Crippa S, Bassi C, Warshaw AL, Falconi M, Partelli S, Thayer SP, et al. Middle pancreatotomy: indications, short- and long-term operative outcomes. *Ann Surg* 2007; 246:69–76. [PMID: 17592293]
22. Del Chiaro M, Rangelova E, Segersvärd R, Arnelo U. Are there still indications for total pancreatotomy. *Updates Surg* 2016; 68:257-63. [PMID: 27605208]
23. Slezak LA, Andersen DK. Pancreatic resection: effects on glucose metabolism. *World J Surg* 2001; 25:452–460. [PMID: 11344398]
24. Yasuda H, Takada T, Toyota N, Amano H, Yoshida M, Takada Y, et al. Limited pancreatotomy: significance of postoperative maintenance of pancreatic exocrine function. *J Hepatobiliary Pancreat Surg* 2000; 7:466–472. [PMID: 11180872]