

Mechanical Prevention of Post-ERCP Pancreatitis by Pancreatic Stents: Results, Techniques, and Indications

Paul R Tarnasky

Digestive Health Associates of Texas. Dallas, Texas, USA

Summary

Impaired pancreatic drainage may be most important in the pathophysiology of post-ERCP pancreatitis. When there is a mechanical problem, there is often a mechanical solution.

Pancreatic stenting reduces the incidence and severity of post-ERCP pancreatitis in high-risk patients. Young patients with suspected sphincter of Oddi dysfunction or prior pancreatitis and those undergoing procedures with either a difficult cannulation, precut and/or pancreatic sphincterotomy should be strongly considered for pancreatic stenting. Stents should be removed within about one week or have the proximal flaps removed to allow early spontaneous distal migration. Pancreatic stent placement following biliary intervention can occasionally be difficult. In cases where the primary goal is pancreatic therapy, one should consider establishing pancreatic access before addressing the bile duct. A pancreatic stent can then serve as a guide for sphincterotomy, but most importantly, protect against post-ERCP pancreatitis.

Introduction

The importance of post-ERCP pancreatitis cannot be overstated. Prospective studies have reported overall pancreatitis rates of 5-15% after ERCP [1, 2, 3, 4, 5, 6, 7]. Endoscopists fear this complication because it occurs commonly and has potential for significant

morbidity and even mortality. The purpose of this paper is to provide an overview of pancreatic stenting for the reduction of post-ERCP pancreatitis.

Impaired pancreatic ductal drainage is an initiating factor for acute pancreatitis in both experimental and clinical settings. Some animal models for pancreatitis involve occluding the pancreatic duct. Clinically, pancreatic ductal obstruction has been implicated in pancreatitis due to gallstones, pancreas divisum, sphincter of Oddi dysfunction (SOD), and post-ERCP pancreatitis.

The pathophysiology of post-ERCP pancreatitis may involve patient and/or technique-related explanations for impaired pancreatic drainage. Prospective studies have defined specific risk factors for post-ERCP pancreatitis [3, 4, 5, 6, 7, 8]. Young patients with prior pancreatitis and/or those with suspected SOD are at the highest risk; historically, about 20% suffer from post-procedure pancreatitis. ERCP procedures with difficult cannulation, repeated pancreatic injections +/- acinarization, access (precut) sphincterotomy, or pancreatic sphincterotomy are also at increased risk.

Results from a retrospective study support the hypothesis that pancreatic drainage is impaired in patients with SOD because of increased pancreatic sphincter pressure [9]. Thirty-one percent of patients with pancreatic SOD developed post-ERCP versus only 3% of those with normal pancreatic manometry. Compared to patients with normal pancreatic manometry, patients with pancreatic SOD

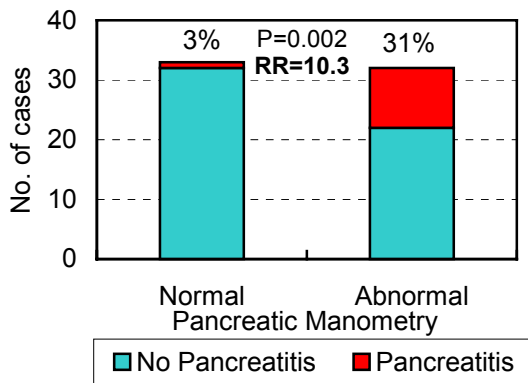


Figure 1. Risk of post-ERCP pancreatitis according to pancreatic manometry results [9].
RR: relative risk

were 10 times more likely to develop post-ERCP pancreatitis (Figure 1).

Results

A prospective, randomized controlled trial evaluated the effect of pancreatic stenting on post-ERCP pancreatitis in high-risk patients undergoing standard biliary sphincterotomy [10]. Among 80 patients with unexplained pancreatobiliary pain or pancreatitis, those with pancreatic SOD underwent biliary sphincterotomy and were randomized to stent or control groups. Pancreatic stenting significantly reduced the risk of pancreatitis (26% versus 7%; Figure 2). Only one (2.4%) of 41 patients with a pancreatic stent developed pancreatitis early after biliary sphincterotomy, and another two patients developed pancreatitis after subsequent endoscopy for stent removal; therefore, patients in the control group were 10.5 times more likely to develop post-ERCP pancreatitis immediately after sphincterotomy compared to those treated with pancreatic stents. Of additional interest was the observation that none of the patients from either group developed post-ERCP pancreatitis if the accessory papilla was obviously patent.

Another study randomized 74 high-risk patients (difficult cannulation and/or suspected SOD) to pancreatic stent or control groups [11]. Post-ERCP pancreatitis was significantly decreased in patients treated with pancreatic stents (34% versus 14%). All 5

cases of pancreatitis in the pancreatic stent group were graded as mild while 5 patients in the control group had moderate to severe pancreatitis.

An earlier study randomized 93 high-risk patients (suspected SOD and/or precut sphincterotomy) to pancreatic stent or control groups after biliary sphincterotomy [12]. Similar rates of post-ERCP pancreatitis were observed in the stent (14%) and control (18%) groups but severity of post-ERCP pancreatitis was decreased in the stent group. Patients in the stent group tended to have shorter hospital stays and none developed severe post-ERCP pancreatitis.

Retrospective analyses also suggest that augmenting pancreatic drainage reduces severity of post-ERCP pancreatitis. One study compared complications in SOD patients undergoing sphincterotomy from two time periods [13]. During the first interval, 28% of patients developed post-ERCP pancreatitis after biliary sphincterotomy alone without pancreatic stenting. Notably, 5% suffered from pancreatitis graded as severe. In the latter period, no cases of severe post-ERCP pancreatitis occurred in 84 patients with SOD who were treated with standard sphincterotomy (biliary +/- pancreatic) followed by pancreatic stenting. A multicenter study reported that severe post-ERCP pancreatitis developed in 2% of 239 suspected SOD patients, but only in patients not treated with a pancreatic stent [14]. There

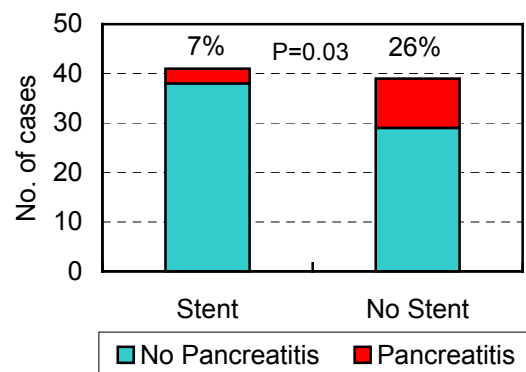


Figure 2. Risk of post-ERCP pancreatitis comparing pancreatic stent and control groups in patients with pancreatic SOD undergoing biliary sphincterotomy [10].

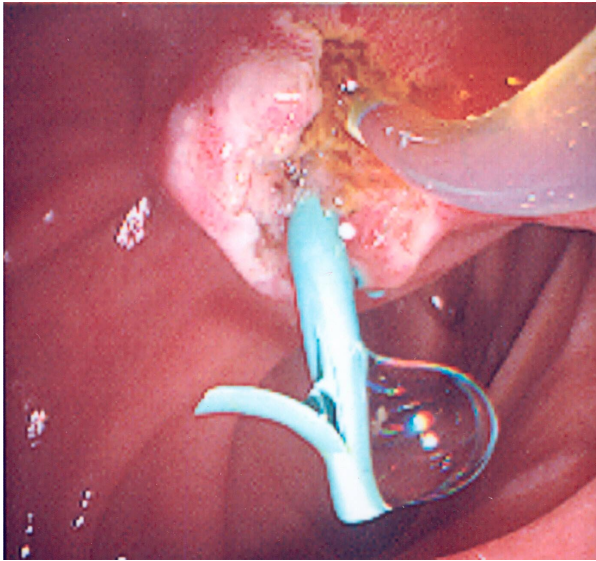


Figure 3. Obvious drainage from a pancreatic stent following precut biliary sphincterotomy.

is some evidence suggesting that even an adequate biliary sphincterotomy alone augments pancreatic drainage sufficiently to reduce severity of post-ERCP pancreatitis [15].

Precut sphincterotomy is a controversial technique, in part because of the varied utilization rates, different techniques, and wide range of reported success and complications. There are few data regarding the use pancreatic stenting in the setting of precut sphincterotomy. Needle-knife precut sphincterotomy is commonly performed using a pancreatic stent as a guide (Figure 3). The risk of pancreatitis is significantly decreased when a pancreatic stent is placed and then left in following a precut sphincterotomy [16]. Pancreatitis may occur less commonly when a precut sphincterotomy is started above the papilla away from the pancreatic orifice using either a needle knife [17], or the Erlangen-type pull papillotome [18]. Pancreatic stenting does not appear necessary when a precut is done in otherwise low-risk patients such as for bile duct stones or malignant biliary obstruction [18, 19].

There is great deal of clinical experience with pancreatic sphincterotomy of the main and minor papillae but a paucity of controlled data. Techniques have evolved without comparative analyses regarding potential

complications such as post-ERCP pancreatitis. Recommendations from experts are available in the form of technical reviews [20, 21]. Pancreatic stenting is widely employed after pancreatic sphincterotomy with goals of reducing both early restenosis and post-ERCP pancreatitis. One study reported that pancreatic drainage with a stent or nasopancreatic drain was associated with significantly less pancreatitis after pancreatic sphincterotomy [22]. A preliminary report suggested that pancreatic stenting reduces the incidence and severity of post-ERCP pancreatitis in patients with a prior biliary sphincterotomy undergoing pancreatic

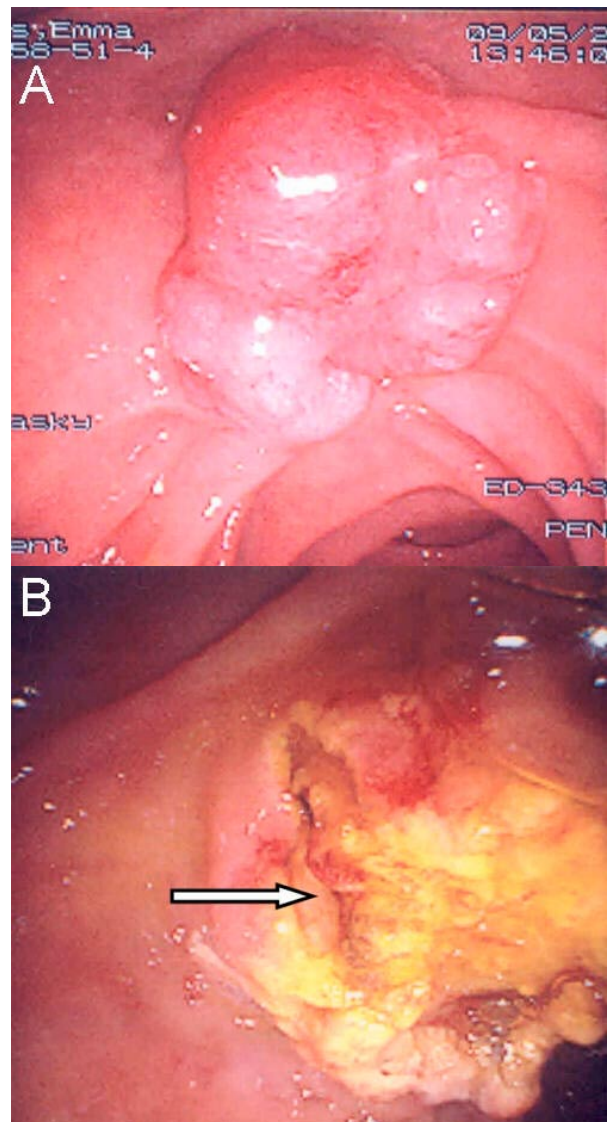


Figure 4. Benign ampullary neoplasm (Figure 4a). Widely patent biliary and pancreatic (arrow) duct orifices are visible following ampullectomy (Figure 4b).

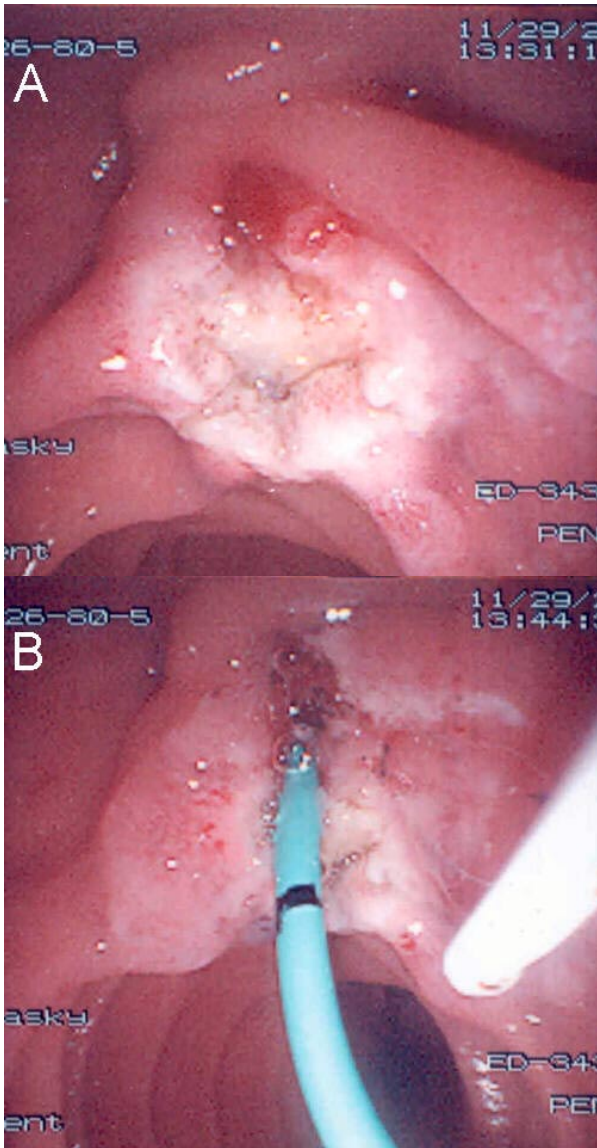


Figure 5. Pancreatic orifice is not obvious after ampullectomy (Figure 5a) so a pancreatic stent (Figure 5b) is placed to ensure drainage.

sphincterotomy [23]. Pancreatic sphincterotomy without stenting appears to be safe in the setting of chronic pancreatitis [24]. Endoscopic ampullary snare resection (ampullectomy) is an uncommon procedure that also has potential for post-procedure pancreatitis. Theoretically, the pancreatic orifice should be patent when a complete ampullectomy is performed (Figure 4). Some advocate pancreatic stent placement on a routine basis [25]. Others place pancreatic stents only when pancreatic drainage is considered to be compromised following ampullectomy (Figure 5) [26, 27].

Techniques

The first step is selective cannulation of the pancreatic duct. Pancreatic cannulation is usually easy at the main papilla because the angle is more perpendicular to the duodenal lumen. After injection of the bile or pancreatic duct, it can sometimes be difficult to cannulate the other. If the bile duct is accessed first, the septum may push down on the pancreatic orifice making it then difficult to cannulate. In patients at high risk for post-ERCP pancreatitis, it may be prudent to first attempt access to the pancreatic duct, particularly if the indication for ERCP is pancreatic, e.g. pancreatitis or pancreatic type pain thought due to SOD. Pancreatic sphincterotomy can then be done with a papillotome (over a guidewire then followed by stent placement) or with a needle knife (following placement of a pancreatic stent). After establishing pancreatic drainage with a stent, biliary cannulation and therapy (if needed) can be done using standard techniques or after a precut sphincterotomy. If a biliary sphincterotomy is performed first, pancreatic cannulation at the main papilla can be more difficult, particularly in patients with SOD. The orifice is toward the right side of

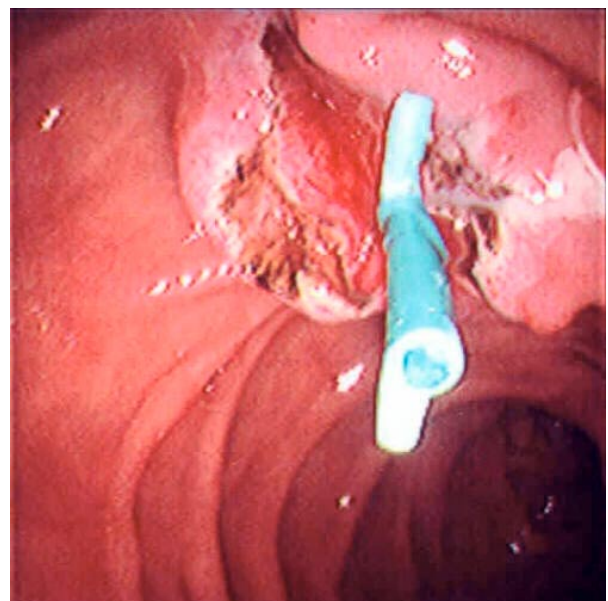


Figure 6. Pancreatic orifice is low toward the base of the sphincterotomy if the common channel is short.

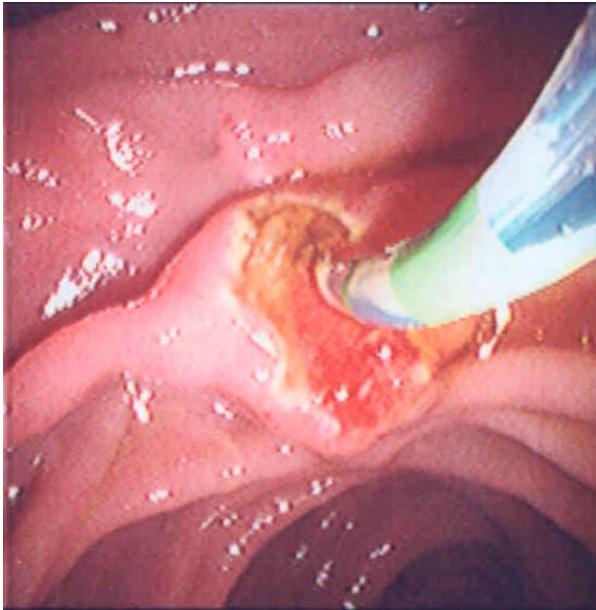


Figure 7. Pancreatic orifice is higher toward the apex of the sphincterotomy if the common channel is longer.

the cut but is not usually obvious, can be stenotic, and may be partially obscured by oozing blood. Location of the orifice after biliary sphincterotomy depends of the length of the common channel. If there is no common channel, or it is short, the pancreatic orifice is lower toward the base of the sphincterotomy (Figure 6). In patients with a longer common channel, the orifice is higher toward the apex of the cut (Figure 7). The pancreatic orifice should be probed for gently in order to prevent false channels and retroperitoneal perforation.

Cannulation of the accessory papilla typically requires smaller catheter tips and guidewires. Tapered (3 F) or needle tip catheters and smaller (0.018 to 0.021-inch diameter) guidewires are usually required. Technical descriptions regarding accessory papilla therapy are not the focus of this paper. If necessary, the orifice (at accessory or main papillae) can be made more obvious after secretin injection.

If pancreatic cannulation attempts fail, it may be necessary to perform a precut pancreatic sphincterotomy. This can be done for either the main papilla or accessory papilla (Figure 8). Experts will only attempt such techniques after carefully considering the potential risk and benefit.

A guidewire should be advanced deep into the pancreatic duct before placing a stent. A multi-lumen catheter allows concomitant contrast injection and guidewire manipulation. As the catheter is advanced or withdrawn along the wire, the duct is outlined with small amounts of contrast injected in the area of interest. When a single lumen catheter is used, the guidewire must be removed before contrast is injected. This leaves a column of air in the catheter ahead of the injected contrast and undoubtedly increases ductal and interstitial pressure. Guidewires with a floppy hydrophilic tip are easy to maneuver and perhaps less traumatic. Flexible guidewire tips can bounce off the duct wall while being gently advanced along the duct

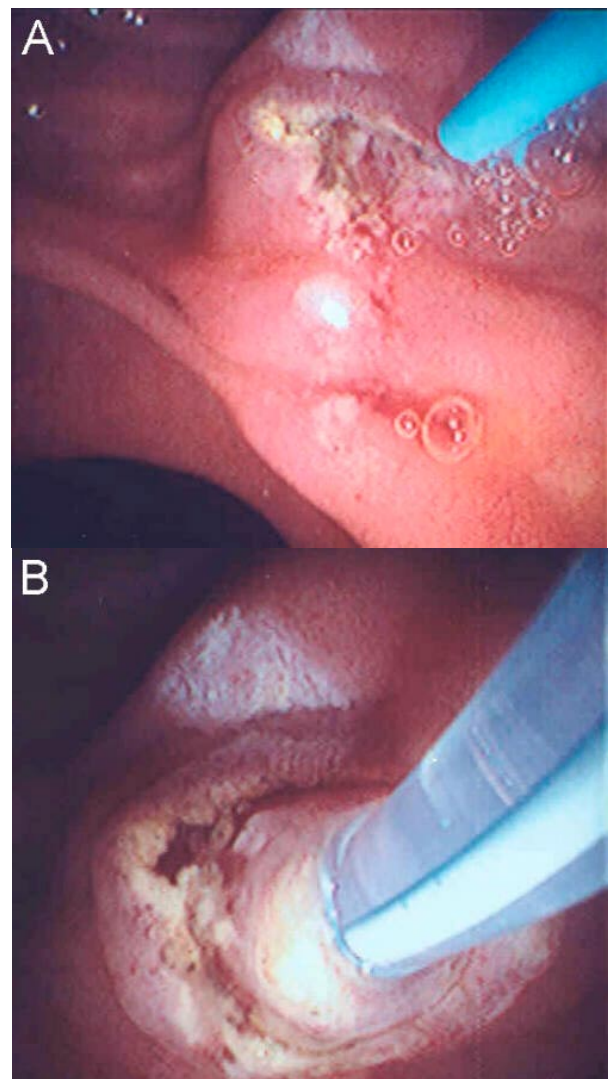


Figure 8. Needle knife precut accessory papillotomy (Figure 8a) followed by deep cannulation with a 5 F catheter (Figure 8b).

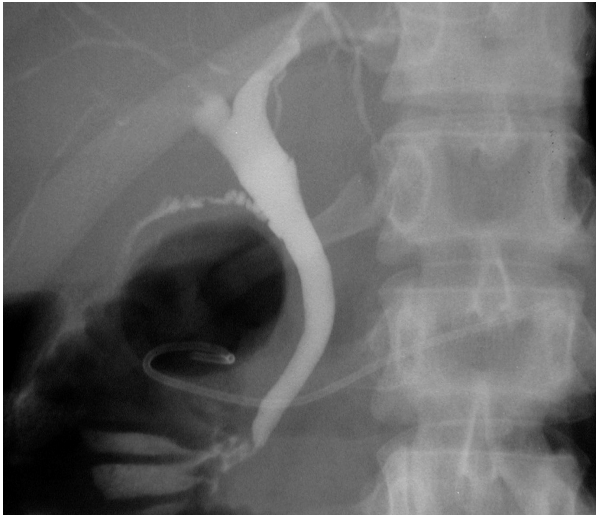


Figure 9. Dorsal duct stent in patient with pancreas divisum.

lumen. If the guidewire tip enters a ductal side branch, excessive force should be avoided in order to prevent duct disruption. With short tapping pushes, the guidewire may bend back on itself so that the leading elbow is advanced along the main duct.

Some catheter designs allow the endoscopist control the guidewire. Otherwise, it is imperative that an experienced assistant is available for guidewire manipulations. Standard 0.035-inch diameter guidewires are seen easily on fluoroscopy. Smaller (0.018, 0.021, or 0.025-inch) guidewires are more challenging to work with; they are less well seen, more difficult to grasp, more likely to enter ductal side branches, and do not transmit a similar tactile sense to the operator. Pancreatic stents vary by diameter, length, and shape. Stent diameter should be less than that of the duct; 5 F stents are typically used. Short stents (1-3 cm) are generally preferred in order to avoid stenting across the neck portion of the pancreatic duct. However, longer stents should be considered when the pancreatic duct is angulated in the head of the pancreas such that a short stent would not align itself properly with the duct axis. For example, longer stents may be more suitable in pancreas divisum patients that have an angulated distal dorsal duct (Figure 9). Stents may be straight or have a single pigtail or partial curl in the duodenum to prevent

proximal migration. It makes sense to place curved stents after pancreatic sphincterotomy. Short stents without proximal flaps facilitate early spontaneous migration within a week. Established drainage is not assured when using stents without proximal flaps because of the potential for very early stent migration. Stents with flaps require endoscopic removal at a later date. Another option is to place longer (>7 cm) stents of small diameter (3 or 4 F) that have no proximal flaps (Figure 10). This practice has the potential advantages of less ductal trauma and allows spontaneous distal migration so that repeat endoscopy is not necessary. Long stents without a proximal flap typically migrate after a delay of several days to weeks. The main disadvantage is that a smaller diameter guidewire must be used as opposed to the standard 0.035-inch diameter wire. Nasopancreatic drains are an option for pancreatic drainage but are more challenging to place and perhaps less tolerable for the patient.

Firm guidelines pertaining to duration of pancreatic stenting do not exist. Clinical factors and practical issues should be considered with the former being most important. Clinical factors include procedure

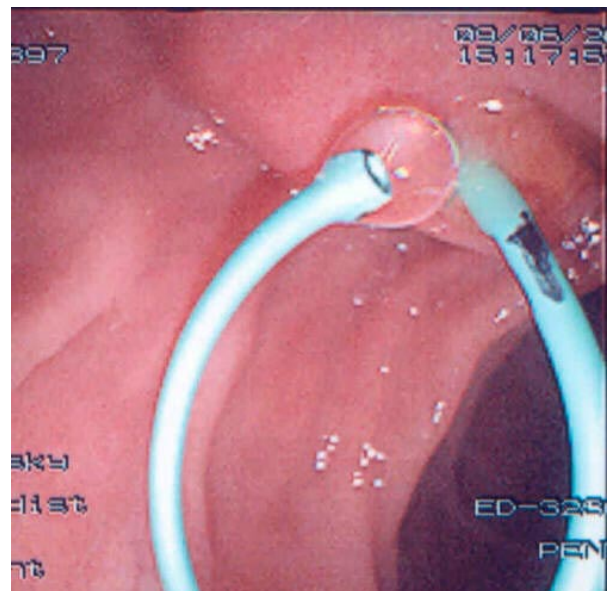


Figure 10. Obvious drainage is observed from a 12 cm long 4 F single pigtail pancreatic stent placed in a patient following normal sphincter of Oddi manometry. The stent does not have proximal flaps to facilitate spontaneous distal migration.

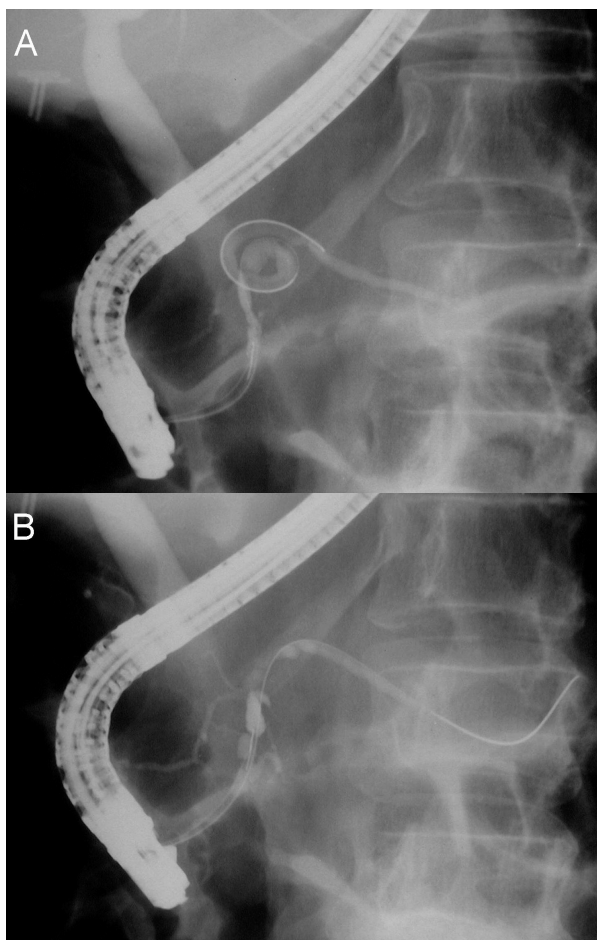


Figure 11. Looping of the pancreatic duct (Figure 11a) straightened after deep guidewire cannulation (Figure 11b).

indication, difficulty of cannulation, diagnosis, type of therapy, and observed patency of the main and accessory pancreatic orifices. Practical issues may also be relevant. For example, it may be reasonable to place a stent without proximal flaps in patients that require general anesthesia for endoscopy or when they must travel great distances to visit an endoscopist.

There are potential problems with pancreatic stenting. As mentioned, stent placement following biliary interventions can be difficult. In prospective studies, failure rates range from 5 to 10% [10, 12, 28]. Failure usually occurs because either the pancreatic orifice cannot be identified or a guidewire cannot be advanced deeply into the duct. Deep pancreatic cannulation can be difficult or impossible when there is looping (Figure 11) or tight angulations (Figure 12) of the distal pancreatic duct. We do not yet have

ideal stent designs. Current pancreatic stents are prone to stent occlusion and cause ductal abnormalities. An additional endoscopy is often needed for stent removal.

When endoscopic stent removal is required, it should be accomplished atraumatically. Use of a duodenoscope allows a better field of view so that the stent can be carefully grasped with a snare or forceps. By advancing the endoscope down the duodenum and tipping away (similar to removing a stone from the bile duct with a balloon or basket), the stent is gently removed along the axis of the duct. A plain radiograph may be done before sedating the patient to make sure the stent has not already migrated.

Indications

In general, pancreatic stenting during ERCP should be carefully considered in any patient with SOD and/or prior pancreatitis. Even patients with normal sphincter of Oddi manometry who do not undergo sphincterotomy have a substantial risk for post-ERCP pancreatitis [10, 13]. Thus, it is reasonable to consider augmenting pancreatic drainage in all patients with suspected SOD who undergo ERCP. Additionally, procedures involving a difficult cannulation, precut sphincterotomy, pancreatic sphincterotomy, or ampullectomy might benefit from pancreatic stenting

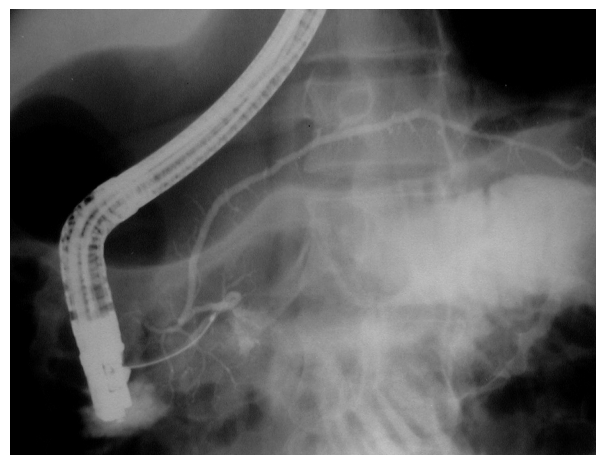


Figure 12. Deep guidewire cannulation could not be achieved because of a sharply angulated pancreatic duct.

Table 1. Situations where pancreatic stenting is not generally required.

| |
|---|
| Biliary cannulation/intervention achieved without pancreatic duct injection |
| Biliary sphincterotomy for SOD with normal pancreatic manometry |
| Older patients (e.g. >60 yr) |
| <u>Pancreatic orifice is visibly patent after ampullectomy</u> |

depending on factors such as patient age, procedure indication, pancreatic ductal patency, and adequacy of sphincterotomy. Pancreatic stenting does not appear necessary in some otherwise high-risk situations such as those listed in Table 1.

It is prudent to place standard stents with proximal flaps when established pancreatic drainage is desired for a specified period, e.g., high-risk patients undergoing pancreatic sphincterotomy. Stents should be removed within a week if the patient is able to eat and has no clinical evidence of pancreatitis. In situations where at least transient pancreatic drainage is desired, e.g., patients being evaluated for possible SOD who do not undergo sphincterotomy, it seems reasonable to place a nasopancreatic drain or a pancreatic stent without proximal flaps. Examples of situations where it is reasonable to maintain established pancreatic drainage (until stent removal) or accept transient (allow spontaneous stent migration) drainage after ERCP are listed in Tables 2 and 3, respectively. Pancreatic stents may be removed at the completion of an ERCP when pancreatic drainage is not needed, e.g. after a needle-knife precut for bile duct stones or malignant biliary obstruction.

Keywords Acute Disease;
Cholangiopancreatography, Endoscopic
Retrograde; Drainage; Endoscopy; Pancreas;
Pancreatitis, Acute Necrotizing;
Sphincterotomy, Endoscopic; Primary
Prevention; Stents

Table 2. Situations where pancreatic drainage is maintained until stent removal.

| |
|---|
| Pancreatic SOD |
| Pancreatic sphincterotomy |
| Pancreas divisum |
| <u>No obvious pancreatic orifice after ampullectomy</u> |

Abbreviations F: French Gauge; SOD: sphincter of Oddi dysfunction

Correspondence

Paul R Tarnasky
Digestive Health Associates of Texas
221 West Colorado Blvd.
Pavilion II, Suite 630
Dallas
Texas 75208
USA
Phone: +1-214- 941.6891
Fax: +1-214-943.5871
E-mail address: paultarn@aol.com

References

1. Chen YK, Foliente RL, Santoro MJ, Walter MH, Colleen MJ. Endoscopic sphincterotomy-induced pancreatitis: increased risk associated with nondilated bile ducts and sphincter of Oddi dysfunction. *Am J Gastroenterol* 1994; 89:327-33. [AN 94168165]
2. Johnson GK, Geenen JE, Bedford RA, Johanson J, Cass O, Sherman S, et al. A comparison of nonionic versus ionic contrast media: results of a prospective, multicenter study. *Gastrointest Endosc* 1995; 42:312-6. [AN 96121321]

Table 3. Situations where at least transient pancreatic drainage is reasonable.

| |
|---|
| Biliary sphincterotomy for SOD with pancreatic duct injection |
| Difficult cannulation ± precut sphincterotomy |
| Sphincter of Oddi manometry and no sphincterotomy |
| <u>Prior pancreatitis including post-ERCP pancreatitis</u> |

3. Freeman ML, Nelson DB, Sherman S, Haber GB, Herman ME, Dorsher PJ, et al. Complications of endoscopic biliary sphincterotomy. *N Engl J Med* 1996; 335:909-18. [AN 96365275]
4. Deviere J, Le Moine O, van Laethem JL, Eisendrath P, Ghilain A, Severs N, Cohard M. Interleukin-10 reduces the incidence of pancreatitis after therapeutic endoscopic retrograde cholangiopancreatography. *Gastroenterology* 2001; 120:498-505. [AN 21100083]
5. Manolakopoulos S, Avgerinos A, Vlachogiannakos J, Armonis A, Viazis N, Papadimitriou N, et al. Octreotide versus hydrocortisone versus placebo in the prevention of post-ERCP pancreatitis: a multicenter randomized controlled trial. *Gastrointest Endosc* 2002; 55:470-5. [AN 21920674]
6. Andriulli A, Clemente R, Solmi L, Terruzzi V, Suriani R, Sigillito A, et al. Gabexate or somatostatin administration before ERCP in patients at high-risk for post-ERCP pancreatitis: a multicenter, placebo-controlled, randomized clinical trial. *Gastrointest Endosc* 2002; 56:488-95. [AN 22233811]
7. Vandervoort J, Soetikno RM, Tham TC, Wong RC, Ferrari AP Jr, Montes H, et al. Risk factors for complications after performance of ERCP. *Gastrointest Endosc* 2002; 56:652-6. [AN 22283811]
8. Masci E, Toti G, Mariani A, Curioni S, Lomazzi A, Dinelli M, et al. Complications of diagnostic and therapeutic ERCP: a prospective multicenter study. *Am J Gastroenterol* 2001; 96:417-23. [AN 21122345]
9. Tarnasky P, Cunningham J, Cotton P, Hoffman B, Palesch Y, Freeman J, et al. Pancreatic sphincter hypertension increases the risk of post-ERCP pancreatitis. *Endoscopy* 1997; 29:252-7. [AN 97399400]
10. Tarnasky PR, Palesch YY, Cunningham JT, Mauldin PD, Cotton PB, Hawes RH. Pancreatic stenting prevents pancreatitis after biliary sphincterotomy in patients with sphincter of Oddi dysfunction. *Gastroenterology* 1998; 115:1518-24. [AN 99055594]
11. Meyerson SM, Geenen JE, Johnson GK, Catalano MF, Gennen DJ, Schmalz MJ, et al. Pancreatic duct stenting decreases the incidence of post-ERCP pancreatitis: a prospective randomized study. *Gastroenterology* 1998; 114:G1967.
12. Smithline A, Silverman W, Rogers D, Nisi R, Wiersema M, Jamidar P, et al. Effect of prophylactic main pancreatic duct stenting on the incidence of biliary endoscopic sphincterotomy-induced pancreatitis in high-risk patients. *Gastrointest Endosc* 1993; 39:652-7. [AN 94040541]
13. Fogel EL, Eversman D, Jamidar P, Sherman S, Lehman GA. Sphincter of Oddi dysfunction: pancreaticobiliary sphincterotomy with pancreatic stent placement has a lower rate of pancreatitis than biliary sphincterotomy alone. *Endoscopy* 2002; 34:280-5. [AN 21929640]
14. Freeman ML, DiSario JA, Nelson DB, Fennerty MB, Lee JG, Bjorkman DJ, et al. Risk factors for post-ERCP pancreatitis: a prospective, multicenter study. *Gastrointest Endosc* 2001; 54:425-34. [AN 21460528]
15. Akashi R, Kiyozumi T, Tanaka T, Sakurai K, Oda Y, Sagara K. Mechanism of pancreatitis caused by ERCP. *Gastrointest Endosc* 2002; 55:50-4. [AN 21629113]
16. Sherman S, Earle D, Bucksot L, Esber E, Pezzi J, Gottlieb K, et al. Does leaving a main pancreatic duct stent in place reduce the incidence of precut biliary sphincterotomy-induced pancreatitis?: randomized prospective study. *Am J Gastroenterol* 1995; 90:1614.
17. Kasmin FE, Cohen D, Batra S, Cohen SA, Siegel JH. Needle-knife sphincterotomy in a tertiary referral center: efficacy and complications. *Gastrointest Endosc* 1996; 44:48-53. [AN 96433736]
18. Binmoeller KF, Seifert H, Gerke H, Seitz U, Portis M, Soehendra N. Papillary roof incision using the Erlangen-type precut papillatome to achieve selective bile duct cannulation. *Gastrointest Endosc* 1996; 44:689-95. [AN 97133664]
19. Bruin Slot W, Schoeman MN, DiSario JA, Wolters F, Tytgat GNJ, Huibregtse K. Needle-knife sphincterotomy as a precut procedure: a retrospective evaluation of efficacy and complications. *Endoscopy* 1996; 28:334-9. [AN 96408491]
20. Sherman S, Lehman GA. Endoscopic pancreatic sphincterotomy: techniques and complications. *Gastrointest Endosc Clin N Am* 1998; 8:115-24. [AN 98070871]
21. Carr-Locke DL, Conn MI, Faigel DO, Laing K, Leung JW, Mills MR, et al. Technology status evaluation: endoscopic pancreatic therapy update. *Gastrointest Endosc* 1998; 48:723-6. [AN 99069209]
22. Elton E, Howell DA, Parsons WG, Qaseem T, Hanson BL. Endoscopic pancreatic sphincterotomy: indications, outcome, and a safe stentless technique. *Gastrointest Endosc* 1998; 47:240-9. [AN 98199944]
23. Patel R, Tarnasky PR, Hennessy WS, Hawes RH, Payne KM, Nelles SE, et al. Does stenting after pancreatic sphincterotomy reduce post-ERCP pancreatitis in patients with prior biliary sphincterotomy?: preliminary results of a prospective randomized trial. *Gastrointest Endosc* 1999; 49:AB80.
24. Ell C, Rabenstein T, Schneider HT, Ruppert T, Nicklas M, Bulling D. Safety and efficacy of pancreatic sphincterotomy in chronic pancreatitis. *Gastrointest Endosc* 1998; 48:244-9. [AN 98415847]

25. Desilets DJ, Dy RM, Ku PM, Hanson BL, Elton E, Mattia A, et al. Endoscopic management of tumors of the major duodenal papilla: refined techniques to improve outcome and avoid complications. *Gastrointest Endosc* 2001; 54:202-8. [AN 21367701]

26. Norton ID, Geller A, Petersen BT, Sorbi D, Gostout CJ. Endoscopic surveillance and ablative therapy for periampullary adenomas. *Am J Gastroenterol* 2001; 96:101-6. [AN 21039868]

27. Binmoeller KF, Boaventrua S, Ramsperger K, Soehendra N. Endoscopic snare excision of benign adenomas of the papilla of vater. *Gastrointest Endosc* 1993; 39:127-31. [AN 93266079]

28. Aizawa T, Ueno N. Stent placement in the pancreatic duct prevents pancreatitis after endoscopic sphincter dilation for removal of bile duct stones. *Gastrointest Endosc* 2002; 54:209-13. [AN 21367702]