

## MULTIMEDIA ARTICLE - Slide Show

# Management of Skin Toxicities of Anti-EGFR Agents in Patients with Pancreatic Cancer and Other GI Tumors by Using Electronic Communication: Effective and Convenient

Muhammad Wasif Saif, Kristin Kaley, Lynne Lamb, Jennifer Pecерillo, Susan Hotchkiss, Lisa Steven, Marianne Brennan, Robin Penney, Carolyn Gillespie, Walid Shaib

Yale University School of Medicine. New Haven, CT, USA

### Summary

Erlotinib has been FDA approved to be used in combination with gemcitabine as the first line treatment in advanced pancreatic cancer patients. Skin rash has been documented as one of the commonest adverse reactions in patients receiving erlotinib and other EGFR inhibitors. Draw back to this reaction leads to: 1) drug discontinuation or dose reduction; 2) impairs quality of life; and 3) Puts patients at risk of superinfection. Monitoring patients closely and initiating immediate skin care is recommended. However, patients forget how the rash started and when. No standard treatments exist secondary to the diversity of symptoms, variability and intermittent occurrence in relation to the cancer therapy. In addition, there is slow improvement with medical treatment. Also, patients need to make extra visits to doctor's office for skin management when in needed in addition to chemotherapy appointments. Late presentation for medical attention leading to complications, such as sepsis. We here experience a novel way of assessing and managing the skin rash using the electronic media. We suggest that electronic communication is of crucial importance to detect early, diagnose and treat anti-EGFR related skin rash in order to continue the benefit of anti-EGFR.

### Introduction

- Erlotinib has been FDA approved to be used in combination with gemcitabine as the first line treatment in advanced pancreatic cancer patients [1].
- Skin rash has been documented as one of the commonest adverse reactions in patients receiving erlotinib and other EGFR inhibitors.
- Draw back to this reaction leads to:
  - 1- Drug discontinuation or dose reduction,
  - 2- Impairs quality of life, and
  - 3- Puts patients at risk of superinfection [1]
- Monitoring patients closely and initiating immediate skin care based on general guidelines is highly recommended.

[1] Li J, et al. JOP. J Pancreas (Online) 2009; 10:338-40.  
[2] Agiero AL, et al. J Am Acad Dermatol 2006; 55:657-70.  
[3] Moore MJ, et al. J Clin Oncol 2007; 25:1963-6.

[4] Boeck S, et al. Anticancer Drugs 2007; 18:1109-11.  
[5] Saif MW. JOP. J Pancreas (Online) 2006; 7:337-48.  
[6] Guzzner R, et al. Hautarzt 2006; 57:509-13.

Secondary adverse reactions seen with anti-EGFR therapy include xerosis, pruritus, paronychia, hair abnormality, and mucositis [2].

A phase III randomized controlled trial by National Cancer Institute of Canada Clinical Trials Group (NCIC-CTG) has shown a statistically significant survival benefit of gemcitabine plus erlotinib compared with gemcitabine alone. The combined treatment arm demonstrated an 18% reduction in the risk of death or an overall 22% improvement in survival than the gemcitabine alone arm, and it was statistically superior in 1-year survival (23.8% vs. 19.4%; P=0.028) and in median survival (6.4 vs. 6.0 months) [3].

The rash develops as early as three days after commencement of erlotinib therapy, with median onset of eight days [4].

Erlotinib, a small-molecule epidermal growth factor receptor (EGFR) tyrosine kinase inhibitor has been approved by FDA for patients with pancreatic cancer and non-small cell lung cancer [1].

Skin toxicity may lead to drug discontinuation or dose reduction, impair patients' activities and exposes the skin to bacterial infections. Preservation of quality of life in these patients is crucial [1].

Toxicity is seen in at least 79% patients treated with erlotinib [5].

Grade 3-4 rash was documented in 9% of erlotinib treated patients, requiring dose reduction in 6% and discontinuation in 1% of patients [6].

Received January 14<sup>th</sup>, 2010 - Accepted January 24<sup>th</sup>, 2010

**Key words** cetuximab; Drug Therapy; Epidermal Growth Factor; erlotinib; Pancreatic Neoplasms; panitumumab; Protein Kinase Inhibitors; Receptor, Epidermal Growth Factor

**Abbreviations** EGFR: Epidermal Growth Factor Receptor, NCI-CTCAE: National Cancer Institute: Common Terminology Criteria for Adverse Events; FDA: Food and Drug Administration

**Correspondence** Muhammad Wasif Saif  
Section of Medical Oncology, Yale University School of Medicine,  
333 Cedar Street; FMP: 116, New Haven, CT 06520, USA  
Phone: +1-203.737.1568; Fax:+1-203.785.3788  
E-mail: wasif.saif@yale.edu

**Document URL** <http://www.joplink.net/prev/201003/05.html>

### Skin Cutaneous Toxicities : Overview

- P.A.3 trial: rash was among the most common side effects reported [7]
- Typically, rash develops about 8-10 days after start of treatment [7]
- Poor performance status was inversely correlated to skin toxicity incidence. Response rate was higher in patients with at least 50% of body surface area with skin toxicity [7]
- In general, rash may appear between 1 and 113 days [7]
- Erlotinib-related rash was generally mild to moderate and is generally manageable [8]
- Occurrence of rash may be intermittent [8]
- Although rash is commonly referred to as “acneiform”, it is not acne and should not be treated as acne [8]

[7] Giovannini M, et al. J Oncol 2009; 849051:1-8  
 [8] Pérez-Soler R, et al. Oncologist 2005; 10:345-56.  
 [9] Soulières D, et al. J Clin Oncol 2004; 22:77-85

Key point: skin rash can be managed with appropriate intervention.

Skin rash occurred in 71% (grade 1-2: 66%; grade 3: 3%; grade 4: 2%); median time of onset was 10 days (range: 1-44 days) [9].

### Different Manifestations of Cutaneous Toxicities [7]

Adverse event	Frequency	Description
Rash	60–80%	Monomorphic erythematous maculopapular, follicular, or pustular lesions which may be associated with pruritus/tenderness
Paronychia and fissuring	6–12%	Painful periungual granulation-type or friable pyogenic granuloma-like changes, associated with erythema, swelling, and fissuring of lateral nailfolds and/or distal finger tufts
Hair changes	5–6%	Alopecia and curlier, finer and more brittle hair on scalp and extremities; trichomegalia and curling of eyebrows and hypertrichosis of the face
Dry skin	4–35%	Diffuse fine scaling
Mucositis	2–36%	Mild to moderate mucositis, stomatitis, and aphthous ulcers
Hypersensitivity reactions	2–3%	Flushing, urticaria, and anaphylaxis

[7] Giovannini M, et al. J Oncol 2009; 849051:1-8

### Pathogenesis of Cutaneous Toxicities

- Unknown mechanism
- Proposed pathogenesis: antibodies against EGFR in the epidermis, sebaceous glands and hair follicles
- Inflammatory response leading to folliculitis and perifolliculitis, decreasing keratinocyte maturation and proliferation. There is a diffuse neutrophilic infiltrate in the dermis. This results in an acneiform rash and dry skin

[10] Tan AR, et al. Ann Oncol 2008; 19:185-90

The dermatologic reactions from anti-EGFR agents, which include antibodies against the extracellular ligand-binding domain of the receptor and small molecules that inhibit activation of the EGFR-tyrosine kinase are commonly found in sites where EGFR is expressed, such as the basal epidermal keratinocytes of epidermis, sebaceous glands, and hair follicles. Histopathological findings of the skin lesion reveal folliculitis and perifolliculitis with a diffuse neutrophilic infiltrate in the dermis. It has been

speculated that cutaneous toxicity from anti-EGFR therapy may be a result of an inflammatory response secondary to EGFR inhibition and/or decreased keratinocyte proliferation/maturation. Markers in the epidermal growth factor receptor pathway and skin toxicity during erlotinib treatment [10].

### Characteristics of Cutaneous Toxicities

National Cancer Institute: Common Terminology Criteria for Adverse Events (NCI-CTCAE) version 3.0: categories relevant to EGFR-associated rash [11]

#### Grade Rash characteristics

- 1 Macular or papular eruption or erythema without associated symptoms
- 2 Macular or papular eruption or erythema with pruritus or other associated symptoms; localized desquamation or other lesions covering less than 50% of body surface area
- 3 Severe, generalized erythroderma or macular, papular or vesicular eruption; desquamation covering more than 50% of body surface area
- 4 Generalized exfoliative, ulcerative, or bullous dermatitis
- 5 Death

[11] National Cancer Institute. CTCP. Cancer Therapy Evaluation Program. Publish date August 9.

### Clinical Grades of Erlotinib-Induced Rash [12]

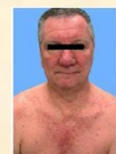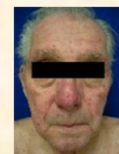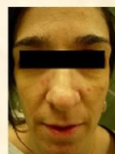#### Toxicity Description

- Mild** Generally localized papulopustular reaction that is minimally symptomatic, with no sign of superinfection, and no impact on daily activities
- Moderate** Generalized papulopustular reaction, accompanied by mild pruritus or tenderness, with minimal impact upon daily activities and no signs of superinfection
- Severe** Generalized papulopustular reaction, accompanied by severe pruritus or tenderness, that has a significant impact upon daily activity and has the potential for or has become superinfected

[12] Saif MW, et al. JOP. J Pancreas (Online) 2008; 9:267-74

### Grading Rash: A Potential Algorithm [13]

Mild	Moderate	Severe
➤ Generally localized	➤ Generalized	➤ Generalized
➤ Minimally symptomatic	➤ Mild symptoms (eg, pruritus, tenderness)	➤ Severe symptoms (eg, pruritus, tenderness)
➤ No impact on activities of daily living	➤ Minimal impact on activities of daily living	➤ Significant impact on activities of daily living
➤ No sign of superinfection	➤ No sign of superinfection	➤ Potential for superinfection



[13] Lynch TJ Jr, et al. Oncologist 2007; 12:610-21

[14] Genentech, Inc. Tarceva®. Highlights of Prescribing Information

This slide shows mild, moderate, and severe rash in patients treated with erlotinib. This grading system should not be construed as per Genentech, Inc. (South San Francisco, CA, USA) or OSI Pharmaceuticals, Inc. (Long Island, NY, USA) recommendations [13, 14]. It was developed by medical advisors at the “Skin Toxicity Forum” held in Chicago, Illinois, during October 2006 [13]. These medical advisors were paid by Genentech, Inc., OSI Pharmaceuticals, Inc., and F.



Hoffmann-La Roche AG (Basel, Switzerland), to participate in the forum. Other medical experts may have a different approach to managing rash.

Rash typically appears on the face and/or upper body in varying degrees and tolerability. For some, severe rash was tolerable; for others, mild rash was intolerable. The rash associated with erlotinib treatment is not acne, though its appearance is similar to acne. Rash varies in presentation and degree. An interactive discussion regarding grading is encouraged to demonstrate the subjective nature of EGFR rash grading currently used in clinical practice.

### General Principles in Management

- Important to treat rash in order to continue treatment
- No standard treatments or guidelines
- Skin care and hygiene: Avoid sunbathing, direct sunlight, high heat or humidity
- Makeup coverage of rash is not contraindicated and should be removed with hypoallergic liquid cleansers
- Emollients to prevent xerosis

### Management [15]

- Topical antibiotics if pustules are present or about to develop
- Topical steroids are controversial with secondary side effects
- No clinical data for topical immunomodulatory agents
- Topical retinoids are used for follicular eruptions but not recommended secondary to skin dryness and peeling [16]
- Acne medications are not as effective as steroids/antibiotics [17]
- Systemic: For severe grade 3-4 lesions
  - Steroids: No data with concern of interaction with anti-EGFR [8]
  - Antibiotics: Tetracycline plays an anti-inflammatory role [18]

[8] Pérez-Soler R, et al. Oncologist 2005; 10:345-56. [17] Sipples R. Semin Oncol Nurs 2006; 22(Suppl 1):28-34.  
 [15] Saf MW, Kim R. Expert Opin Drug Saf 2007; 6:175-82. [18] Sapadin AN, Fleishmajer R. J Am Acad Dermatol 2006; 54:258-65.  
 [16] Van Doorn R, et al. Br J Dermatol 2002; 147:598-601.

### Nonpharmacologic Interventions

- Employ a proactive approach in managing skin reactions
- Suggest patients use:
  - Thick, alcohol-free emollient cream on dry area
  - Sunscreen of sun protection factor (SPF) 15 or higher, preferably containing zinc oxide or titanium dioxide
- If patient presents with a rash:
  - Verify appropriate administration
    - ✓ Erlotinib should be taken at least 1 hour before or 2 hours after the ingestion of food
  - Treat per the provided potential treatment algorithms or your institution's guidelines

Key points: i) skin rash can be managed with appropriate intervention; ii) erlotinib should be taken at least one hour before or two hours after the ingestion of food.

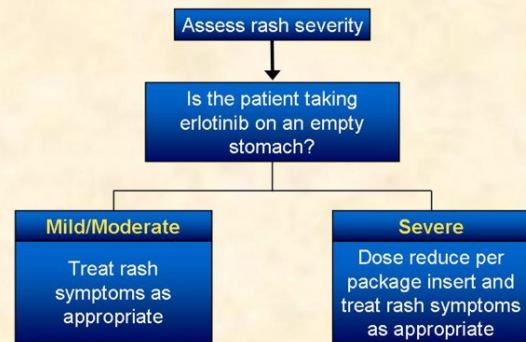
### Proposed Management <sup>a</sup> [12]

Grade	Erlotinib	Treatment	Follow-up
Mild	Continue erlotinib at current dose and monitor for change in severity	Topical hydrocortisone 1% or 2.5% cream <sup>b</sup> and/or clindamycin 1% gel	Reassess in 2 weeks; if no improvement, treat as moderate grade
Moderate	Continue erlotinib at current dose and monitor for change in severity; continue treatment of rash	Hydrocortisone 2.5% cream <sup>b</sup> or clindamycin 1% gel or pimecrolimus 1% cream plus doxycycline 100 mg bid or minocycline 100 mg bid	Reassess in 2 weeks; if no improvement, treat as severe grade
Severe	Reduce erlotinib dose per drug insert and monitor for change in severity; continue treatment of rash	Treat as above in moderate grade, and may consider adding methylprednisolone dose pack	Reassess in 2 weeks; if worsens, consider dose interruption or discontinuation

<sup>a</sup> This approach is based on institutional experience and not based on a prospective study. Also, note that the use of these medications for the management of rash may be outside of the FDA-labeled indications for these products. Therefore, we recommend physicians to read the complete information regarding the safety and use of these medications.  
<sup>b</sup> The use of topical steroids should be employed in a pulse manner based on your institution's guidelines.

[12] Saf MW, et al. JOP. J Pancreas (Online) 2008; 9:267-74.

### Rash Assessment and Management Algorithm [13]



[13] Lynch TJ Jr, et al. Oncologist 2007; 12:610-21.

Key point: erlotinib should be taken at least one hour before or two hours after the ingestion of food. This slide is designed to open a dialogue among attendees on how they manage rash in their practice. Measures: they take upfront, such as patient education initiatives and prophylactic measures, should be discussed. Management options, once a patient develops a rash while on erlotinib, should be discussed as well.

- Do they dose reduce erlotinib? Why?
- Do they discontinue erlotinib?
- Do they modify the erlotinib regimen?
- Do they maintain erlotinib at the current dose and treat the rash, and if so, how?

### Pre-Emptive Skin Toxicity Treatment With Panitumumab for CRC (STEPP) [19]

- Skin therapy consisting of:
  - Moisturizers
  - Sunscreen (PABA-free, SPF ≥ 15, UVA/UVB protection)
  - Topical 1% hydrocortisone cream
  - Doxycycline 100 mg bid
- 95 patients randomized to pre-emptive (24 hr prior to 1<sup>st</sup> dose) or reactive (after skin toxicity developed)

6-week evaluation	Pre-emptive	Reactive
Incidence of ≥ grade 2 skin toxicity (95% CI)	23% (11-35%)	40% (26-54%)
Incidence of grade 3 skin toxicity (95% CI)	6% (0-13%)	21% (10-33%)

[19] Lacouture ME, et al. J Clin Oncol 2010 Feb 8.



### Anti-EGFR Agents [15, 20]

- *Gefitinib (Iressa™, AstraZeneca Pharmaceuticals, Wilmington, DE, USA)*
- *Cetuximab (Erbitux®, ImClone Systems Inc., New York, NY, USA; Bristol-Myers Squibb Co., Princeton, NJ, USA)*
- *Erlotinib HCl (Tarceva™, Genentech, South San Francisco, CA, USA)*
- *Lapatinib (GW-572016; Tykerb®/Tykerb®, GlaxoSmithKline (GSK), London, United Kingdom)*
- *Panitumumab (ABX-EGF; Abgenix®, Amgen, Thousand Oaks, CA, USA)*
- *EMD 72000 HER1/EGFR*
- *EKB-569 HER1/EGFR*
- *Canertinib (Pfizer, New York, NY, USA)*

[ 2] Agero AL, et al. J Am Acad Dermatol 2006; 55:657-70 [20] Saif MW, Cohenuram M. Clin Colorectal Cancer 2006; 6:118-24  
 [15] Saif MW, Kim R. Expert Opin Drug Saf 2007; 6:175-82 [21] Boland WK, Bebb G. Expert Opin Biol Ther 2009; 9:1199-206

Nimotuzumab, a humanized murine mAb created in Cuba, has demonstrated antitumor activity similar to that of other anti-EGFR mAbs and shows promise as a single agent and as an adjunct to radiation in Phase I and II clinical trials. Surprisingly, the typical severe dermatological toxicities thus far associated with anti-EGFR therapy have not been described with nimotuzumab [21].

Cetuximab, erlotinib, and gefitinib have been approved for patients with colorectal and non-small cell lung cancer refractory or intolerant to chemotherapy. The most commonly encountered adverse effect was a mild skin toxicity characterized by a sterile follicular and pustular rash that may be treated empirically and usually does not require treatment modification. Although the precise mechanism for development of rash is not well defined, it is related to inhibition of EGFR-signaling pathways in the skin, and may serve as visible markers of anti-tumor activity and therapeutic efficacy [2].

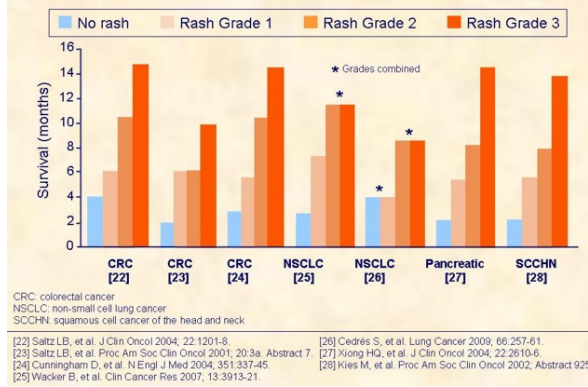
### EGFR Targeted Agents [7]

Agent	Class	Indication	Dose
Erlotinib	TKI	- Locally advanced or metastatic NSCLC after at least one prior chemotherapy regimen - Locally advanced or metastatic pancreatic cancer in combination with gemcitabine	100–150 mg/day cancer
Gefitinib	TKI	- As single agent Locally advanced or metastatic NSCLC after at least platinum based and docetaxel chemotherapy regimen (only in the USA)	250 mg/day
Cetuximab	mAb	- Locally or regionally advanced squamous cell carcinoma of head and neck in combination with radiotherapy - As single agent for recurrent or metastatic squamous cell carcinoma of head and neck after failure of platinum-based chemotherapy - As single agent in EGFR-expressing metastatic colorectal carcinoma in case of intolerance to irinotecan-based chemotherapy - In combination with irinotecan in EGFR-expressing metastatic colorectal carcinoma in patients refractory to irinotecan-based chemotherapy	400 mg/m <sup>2</sup> initial dose followed by 250 mg/m <sup>2</sup> weekly
Panitumumab	mAb	- In EGFR-expressing metastatic colorectal carcinoma in patients in progression on or following fluoropyrimidine-, oxaliplatin-, and irinotecan-based chemotherapy	6 mg/kg iv every 14 days
Bevacizumab	mAb	- Advanced colorectal cancer patients receiving first- and second-line intravenous 5-FU-based chemotherapy for the treatment - In combination with carboplatin and paclitaxel, for first-line treatment of patients with unresectable, locally advanced, recurrent or metastatic nonsquamous, nonsmall cell lung cancer - In combination with paclitaxel for the treatment of patients who have not received chemotherapy for metastatic HER2-negative breast cancer.	5–15 mg/kg/2 weeks

[7] Giovannini M, et al. J Oncol 2009; 849051:1-8

### Impact of Rash on Outcome

### EGFR Inhibitor Outcomes in a Variety of Cancers Correlate with Rash



All of the above are retrospective. All are with cetuximab except Wacker *et al.* [25] and Cedrés *et al.* [26] are with erlotinib. There are similar analyses that did not find the correlation. Should be interpreted with caution due to potential bias that exists because patients with a naturally longer life expectancy would be on the EGFR inhibitor longer and therefore be more likely to develop the rash.

### Challenges in Managing Cutaneous Toxicities [15]

- *Patients forget how the rash started and when*
- *No standard treatments secondary to the diversity of symptoms, variability and intermittent occurrence in relation to the cancer therapy*
- *Infrequent involvement of dermatologists*
- *No data in the literature for topical applications*
- *Slow improvement with medical treatment*
- *Access to healthcare provider*
- *Late presentation for medical attention leading to complications*

[15] Saif MW, Kim R. Expert Opin Drug Saf 2007; 6:175-82

### Electronic Communication: A Novel Idea

- *Providing quality health care depends on the clinician's ability to adequately communicate*
- *Written and verbal (face-to-face and telephone) communications have traditionally been the primary mechanisms*
- *The use of e-mail allows for follow-up patient care and clarification of advice provided*
- *Inexpensive mechanism for communication*
- *Allows written follow-up instructions, test results and dissemination of educational materials for patients, as well as, a means for patients to easily reach their physician*
- *Issues of privacy, confidentiality and security must be addressed to ensure the efficacy and effectiveness*

New communication technologies must never replace the crucial interpersonal contacts that are the very basis of the patient-physician relationship. Rather, electronic mail and other forms of Internet communication should be used to enhance such contacts.



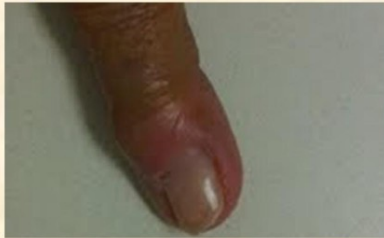### Communication Guide Lines by American Medical Association [29]

- Establish turnaround time for messages
- Inform patient about privacy issues
- Patients should know who besides addressee processes messages
- Retain electronic and/or paper copies of e-mails communications with patients
- Establish types of transactions and sensitivity of subject matter
- Instruct patients to put the category of transaction in the subject line of the message for filtering
- Request that patients put their name and patient identification number in the body of the message
- Develop archival and retrieval mechanisms
- Maintain a mailing list of patients, but do not send group mailings
- Concise messages
- Notify patients to come in to discuss or call them if long e-mails

[29] Kane B, Sands DZ. J Am Med Inform Assoc 1998; 5:104-11.

#### Case #1

A 67-years-old white female treated with gemcitabine and erlotinib called the nurse with new development of nail infection. Patient was advised to come and see us. Due to transport, she could not come. Therefore, she was requested to take a picture with her cell phone and email to us.

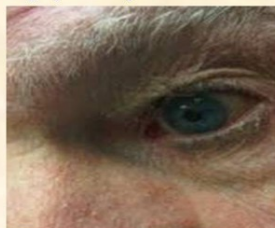

#### Case #1: How Was the Patient Managed?

- Based on the picture, diagnosis of paronychia was made
- Patient was directed to stop erlotinib, and oral minocycline was started
- Patient called back after three days and told about dramatic improvement

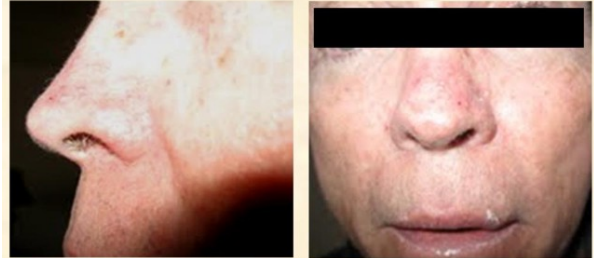#### Case #2

A Caucasian 68-year-old male with pancreatic cancer on erlotinib called the nurse with irritation in eyes, blurred vision and mild redness. Patient could not come to see due to a snow storm. He was directed to send a picture of his eyes if possible. Based on the picture, a diagnosis of trichomegaly was made. He was told to get his eyelashes trimmed and use artificial tears. His symptoms improved within 24 hours after the above management.



#### Case #3

A Caucasian 54-year-old male with gallbladder cancer was treated with erlotinib. Patient was living in Florida and one day called my office with rash on the face. Patient e-mailed the nurse few pictures of the rash that led to its proper grading and management

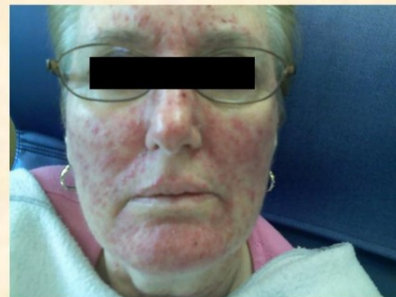

#### Case #4 [1]

A 56-year-old white female with pancreatic adenocarcinoma stated erlotinib at 100 mg daily. The patient returned to clinic with a papulopustular acneiform rash on face, neck, back, predominantly on face (Figure). The rash was erythematous associated with dryness, pruritus and tenderness. The scalp, arms and lower body were uninvolved. Clindamycin 3% gel and oral minocycline at 100 mg daily were given for treating the rash. Meanwhile, erlotinib dose was reduced to 100 mg every other day; however, the rash continued to get worse despite of dose reduction of erlotinib. Therefore, erlotinib was completely discontinued after a total of 11 days of use. A week after discontinuation of erlotinib, the patient developed shaking chills with rigors. Her temperature is only 36.8°C, with heart rate of 114/min, and respiration rate of 20/min; clinically, she was highly suspicious for systemic infection. A complete blood count revealed leukocytosis with total white cell count of 12,200  $\mu\text{L}^{-1}$  (reference range: 4,000-10,000  $\mu\text{L}^{-1}$ ) with neutrophils of 77% (reference range: 38-81%). Pan-culture was performed from peripheral line and double-lumen port-a-cath. The patient was admitted to hospital and treated with intravenous antibiotics for broad-coverage with vancomycin and Zosyn® (Wyeth, Madison, NJ, USA; piperacillin and tazobactam) initially, then narrowed to vancomycin after 5 out of 6 bottles grew penicillin and clindamycin resistant but vancomycin-sensitive *Staphylococcus aureus*. Port-a-cath was removed during that hospitalization, and temporary peripherally inserted central catheter line was inserted for antibiotics administration. Port-a-cath tip culture grew out mixed gram positive flora of 3 varieties consistent with skin flora. She was treated with intravenous vancomycin for a total of 10 days. Repeated peripheral blood culture and culture from the newly inserted peripherally inserted central catheter in two days and five days were all negative. Her skin rash gradually subsided after we discontinued erlotinib, and eventually disappeared after two weeks of skin care with topical clindamycin gel.

[1] Li J, et al. JOP. J Pancreas 2009, 10:338-40.

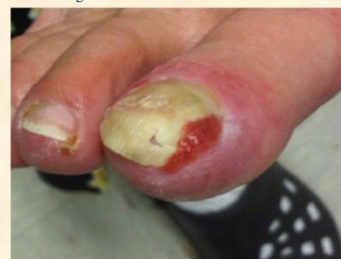#### Case #4 [1]



[1] Li J, et al. JOP. J Pancreas 2009, 10:338-40.

#### Case #5

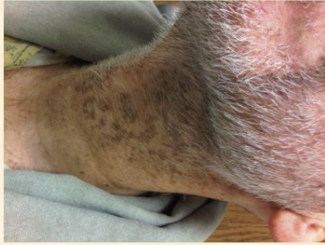This is a Caucasian 64-year old female with pancreatic cancer who was receiving erlotinib and capecitabine after failing gemcitabine. She called for a possibility of in gown nail-like problem. She sent us a picture. Diagnosis of paronychia was made and patient was referred to a podiatrist as well as started on "per os" minocycline. She recovered with in 10-12 days.



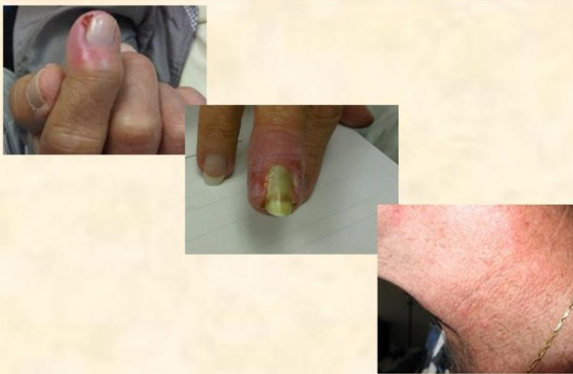

### Case #6

➤ A 72-year-old Caucasian male with pancreatic cancer called in with a rash on the neck and nose, described as dark pigmentation. There was no acne-like rash but only pigmentation was seen. Patient improved his rash on topical clindamycin. The pigmentation totally resolved after he stopped erlotinib (more than 4 weeks later).



### Case #6: Few More Examples



### Discussion

- Using electronic media which is readily available (cameras, phones, internet)
- Grading of the rash is important to determine management, including dose reduction or interruption
- It is helpful in diagnosing and starting early treatment to prevent complications
- Limitations in using electronic communication is the subjectivity and adherence to use it
- Confidentiality and security of the data has to be kept
- Consent form to use electronic communication was used
- Password protected screen savers were used
- Termination of information after treatment/diagnosis

### Conclusions

- Anti-EGFR-induced skin rash should be managed as intensively as possible
- Early treatment prevents non-adherence to anti-EGFR and complications of rash
- Electronic communication is of crucial importance to detect early, diagnose and treat anti-EGFR related skin rash in order to continue the benefit of anti-EGFR

**Conflict of interest** The authors have no potential conflicts of interest

### References

1. Li J, Peccerillo J, Kaley K, Saif MW. Staphylococcus aureus bacteremia related with erlotinib skin toxicity in a patient with pancreatic cancer. JOP. J Pancreas (Online) 2009; 10:338-40. [PMID 19454833]
2. Agero AL, Dusza SW, Benvenuto-Andrade C, Busam KJ, Myskowski P, Halpern AC. Dermatologic side effects associated with the epidermal growth factor receptor inhibitors. J Am Acad Dermatol 2006; 55:657-70. [PMID 17010747]
3. Moore MJ, Goldstein D, Hamm J, Figer A, Hecht JR, Gallinger S, et al. Erlotinib plus gemcitabine compared with gemcitabine alone in patients with advanced pancreatic cancer: a phase III trial of the National Cancer Institute of Canada Clinical Trials Group. J Clin Oncol 2007; 25:1960-6. [PMID 17452677]
4. Boeck S, Hausmann A, Reibke R, Schulz C, Heinemann V. Severe lung and skin toxicity during treatment with gemcitabine and erlotinib for metastatic pancreatic cancer. Anticancer Drugs 2007; 18:1109-11. [PMID 17704662]
5. Saif MW. Pancreatic cancer: highlights from the 42nd annual meeting of the American Society of Clinical Oncology, 2006. JOP. J Pancreas (Online) 2006; 7:337-48. [PMID 16832131]
6. Gutzmer R, Werfel T, Kapp A, Elsner J. Cutaneous side effects of EGF-receptor inhibition and their management. Hautarzt 2006; 57:509-13. [PMID 16205868]
7. Giovannini M, Gregorc V, Belli C, Roca E, Lazzari C, Viganò MG, et al. Clinical significance of skin toxicity due to EGFR-targeted therapies. J Oncol 2009; 849051:1-8. [PMID 19584908]
8. Pérez-Soler R, Delord JP, Halpern A, Kelly K, Krueger J, Sureda BM, et al. HER1/EGFR inhibitor-associated rash: future directions for management and investigation outcomes from the HER1/EGFR inhibitor rash management forum. Oncologist 2005; 10:345-56. [PMID 15851793]
9. Soulieres D, Senzer NN, Vokes EE, Hidalgo M, Agarwala SS, Siu LL. Multicenter phase II study of erlotinib, an oral epidermal growth factor receptor tyrosine kinase inhibitor, in patients with recurrent or metastatic squamous cell cancer of the head and neck. J Clin Oncol 2004; 22:77-85. [PMID 14701768]
10. Tan AR, Steinberg SM, Parr AL, Nguyen D, Yang SX. Markers in the epidermal growth factor receptor pathway and skin toxicity during erlotinib treatment. Ann Oncol 2008; 19:185-90. [PMID 17878175]
11. National Cancer Institute. Common Terminology Criteria for Adverse Events v3.0 (CTCAE). CTEP: Cancer Therapy Evaluation Program. Publish date August 9, 2006 Accessed January 14, 2008.
12. Saif MW, Merikas I, Tsimboukis S, Syrigos K. Erlotinib-induced skin rash. Pathogenesis, clinical significance and management in pancreatic cancer patients. JOP. J Pancreas (Online) 2008; 9:267-74. [PMID 18469438]
13. Lynch TJ Jr, Kim ES, Eaby B, Garey J, West DP, Lacouture ME. Epidermal growth factor receptor inhibitor-associated cutaneous toxicities: an evolving paradigm in clinical management. Oncologist 2007; 12:610-21. [PMID 17522250]
14. Genentech. Inc. Tarceva®. Highlights of Prescribing Information. Accessed February 19, 2007.
15. Saif MW, Kim R. Incidence and management of cutaneous toxicities associated with cetuximab. Expert Opin Drug Saf 2007; 6:175-82. [PMID 17367263]
16. Van Doorn R, Kirtschig G, Scheffer E, Stoof TJ, Giaccone G. Follicular and epidermal alterations in patients treated with ZD1839 (Iressa), an inhibitor of the epidermal growth factor receptor. Br J Dermatol 2002; 147:598-601. [PMID 12207609]
17. Sipples R. Common side effects of anti-EGFR therapy: acneiform rash. Semin Oncol Nurs 2006; 22(Suppl 1):28-34. [PMID 16616284]

18. Sapadin AN, Fleischmajer R. Tetracyclines: nonantibiotic properties and their clinical implications. *J Am Acad Dermatol* 2006; 54:258-65. [PMID 16443056]
  19. Lacouture ME, Mitchell EP, Piperdi B, Pillai MV, Shearer H, Iannotti N, et al. Skin toxicity evaluation protocol with panitumumab (STEPP), a phase II, open-label, randomized trial evaluating the impact of a pre-emptive skin treatment regimen on skin toxicities and quality of life in patients with metastatic colorectal cancer. *J Clin Oncol* 2010 Feb 8. [PMID 20142600]
  20. Saif MW, Cohenuram M. Role of panitumumab in the management of metastatic colorectal cancer. *Clin Colorectal Cancer* 2006; 6:118-24. [PMID 16945167]
  21. Boland WK, Bebb G. Nimotuzumab: a novel anti-EGFR monoclonal antibody that retains anti-EGFR activity while minimizing skin toxicity. *Expert Opin Biol Ther* 2009; 9:1199-206. [PMID 19624281]
  22. Saltz LB, Meropol NJ, Loehrer PJ Sr, Needle MN, Kopit J, Mayer RJ. Phase II trial of cetuximab in patients with refractory colorectal cancer that expresses the epidermal growth factor receptor. *J Clin Oncol* 2004; 22:1201-8. [PMID 14993230]
  23. Saltz LB, Rubin M, Hochster H, et al. Cetuximab (IMC-225) plus irinotecan (CPT-11) is active in CPT-11-refractory colorectal cancer (CRC) that expresses epidermal growth factor receptor (EGFR). *Proc Am Soc Clin Oncol* 2001; 20:3a. Abstract 7.
  24. Cunningham D, Humblet Y, Siena S, Khayat D, Bleiberg H, Santoro A, et al. Cetuximab monotherapy and cetuximab plus irinotecan in irinotecan-refractory metastatic colorectal cancer. *N Engl J Med* 2004; 351:337-45. [PMID 15269313]
  25. Wacker B, Nagrani T, Weinberg J, Witt K, Clark G, Cagnoni PJ. Correlation between development of rash and efficacy in patients treated with the epidermal growth factor receptor tyrosine kinase inhibitor erlotinib in two large phase III studies. *Clin Cancer Res* 2007;13:3913-21. [PMID 17606725]
  26. Cedrés S, Prat A, Martínez P, Pallisa E, Sala G, Andreu J, et al. Clinical surrogate markers of survival in advanced non-small cell lung cancer (NSCLC) patients treated with second-third line erlotinib. *Lung Cancer* 2009; 66:257-61. [PMID 19231023]
  27. Xiong HQ, Rosenberg A, LoBuglio A, Schmidt W, Wolff RA, Deutsch J, et al. Cetuximab, a monoclonal antibody targeting the epidermal growth factor receptor, in combination with gemcitabine for advanced pancreatic cancer: a multicenter phase II trial. *J Clin Oncol* 2004; 22:2610-6. [PMID 15226328]
  28. Kies M, Arquette MA, Nabell L, et al. Final report of the efficacy and safety of the anti-epidermal growth factor antibody Cetuximab (IMC-C225), in combination with cisplatin in patients with recurrent squamous cell carcinoma of the head and neck (SCCHN) refractory to cisplatin containing chemotherapy. *Proc Am Soc Clin Oncol* 2002; Abstract 925.
  29. Kane B, Sands DZ. White paper: guidelines for the clinical use of electronic mail with patients. *J Am Med Inform Assoc* 1998; 5:104-11. [PMID 9452989]
-