

## REVIEW ARTICLE

# Low-Dose Metronomic Capecitabine (Xeloda) for Treatment of Metastatic Cholangiocarcinoma : Case Reports and Review of the Literature

Bergthor Björnsson<sup>1</sup>, Maria Albertsson<sup>2</sup>, Per Sandström<sup>1</sup>

Division of <sup>1</sup>Surgery and Division of <sup>2</sup>Oncology, Department of Clinical and Experimental Medicine, faculty of Health Sciences, County Council of Östergötland, University of Linköping, 581 85 Linköping, Sweden

### ABSTRACT

**Background** Metastatic Cholangiocarcinoma is a disease with a dismal prognosis. Treatment options are few, survival short and the side effects of treatments are burdensome. Metronomic chemotherapy can offer tumour regression and palliation. In this study we explore the responses of three patients to this treatment method in cases where conventional chemotherapy treatment has failed. **Methods** Three patients diagnosed with metastatic cholangiocarcinoma are described. All patients have been treated with metronomic Xeloda (500 mg x 2). The available literature for metronomic treatment is reviewed. **Results** Tumour regression or stable diseases for long periods were seen in all three cases. Toxicity noticed was Grade I or II. **Conclusions** Metronomic chemotherapy can be a therapeutic alternative in selected cases of metastatic cholangiocarcinoma, especially where toxicity limits treatment alternatives for highly motivated patients.

### INTRODUCTION

Today, cancer is a public health issue, it is believed that of the coming generation, half will suffer from cancer [1]. Gastrointestinal cancers are, after breast and prostate cancer, the most common form of cancer and among these is cholangiocarcinoma. This is a particularly difficult but rare form of cancer with a yearly incidence about 2/100.000 in Sweden. The curative treatment is surgery but in many cases where the disease is locally advanced or metastasised, palliative chemotherapy is the only treatment to offer. This is often a treatment with serious side-effects and thus the palliative effect can be questioned. The median survival of patients with cholangiocarcinoma that are not amendable to surgical treatment is around half year. Even extremely motivated patient may choose to refrain from treatment due to these severe side-effects. In these cases, efforts are made to find a chemotherapy treatment that will slow or reduce the progress of the disease in order to buy the patient some time with a maintained quality of life [2].

Unfortunately, QoL is often severely impaired by conventional chemotherapy. Nausea, vomiting, hair loss and noticeably neurotoxicity are some of the commonly experienced side effects that impair the patients QoL [3].

Metronomic chemotherapy is a low-dose continuous anti-cancer treatment that is a relatively new concept of treating cancer that is emerging as a promising alternative to the traditional regimens. By administering drugs in this way higher tolerability and less drug resistance may be anticipated [4]. Metronomic chemotherapy has primarily been reported for cancer of the breasts while its value in gastrointestinal cancer is much less explored [5, 6].

### Metronomic Chemotherapy

If the treatment of cancer is to be improved it is of paramount importance to explore new drug targets as well as unconventional treatment strategies. Unfortunately, drug resistance and toxicity are commonly seen effects of classical chemotherapy [4]. The classical way of administering chemotherapeutic agents is using combinations of cytotoxic drugs given at doses near or even at the maximum tolerated dose (MTD). As this will result in severe side effects the patient is allowed to recover from these and the drugs are administered in cycles (e.g. every third week) [7]. A commonly seen effect of this traditional way of drug administration is tumor regression or stabilization. Unfortunately this effect is often not sustained, while the treatment may be costly in terms of reduced QoL [8]. The concept of MTD-based chemotherapy has been considered more effective for primary tumors than for metastasis although sound evidence is lacking. Unfortunately, conventional chemotherapy for metastatic upper GI cancer can only offer palliative effects, regardless if several cytotoxic drugs are combined [9].

The term metronomic chemotherapy was established in 2000 by Hanahan *et al.* [8]. This concept refers to

Received May 18th, 2016-Accepted August 31st, 2016

**Keywords** Capecitabine; Cholangiocarcinoma; Metronomic chemotherapy; Quality of life

**Correspondence** Bergthor Björnsson

Department of Surgery  
Linköping University Hospital  
Linköping, Sweden

**Phone** ++46 10 10 30000

**Fax** +46 10 10 23570

**E-mail** bergthor.bjornsson@liu.se

continuous drug administration of chemotherapeutic agents (e.g. daily), at doses low compared to conventional chemotherapy and without long drug-free intervals commonly used with classical treatments [10]. Metronomic treatment leads to a sustained plasma concentration of the drug that differs from the conventional chemotherapy where rise and fall of the drug concentration are the effective features. This difference is thought to explain the reduced probability of adverse events seen with metronomic treatment [7]. Available clinical trials have demonstrated rare or non-existing high-grade toxicity in the settings of metronomic chemotherapy [11]. Moreover, a continuous low-dose approach also seems to be more cost-effective than conventional chemotherapy since it offers a higher preference for inexpensive oral drugs and less expenses are placed on adverse events [12].

A relevant consideration in the use of metronomic chemotherapy is that many important aspects of the treatment regimen are purely empirical. These include the choice of cytostatic drug, the right dose, the optimal dosing interval and the right patient selection [6, 13, 14]. It has to be kept in mind that in clinical practice, metronomic chemotherapy is emerging as an attractive experimental treatment option for patient not found to be fit for conventional chemotherapy, but still motivated for active treatment [13]. Metronomic chemotherapy may not only be suitable within curative settings but also in the palliative settings when the goal is to prevent disease progression without unnecessary reduction in QoL [5]. We present three cases of oncological treatment including metronomic chemotherapy in the setting of palliative treatment of cholangiocarcinoma.

### Case #1

A Sixty-seven-year-old man with insulin dependent diabetes mellitus who presented with silent jaundice in the autumn of 2010. Examination revealed a 15 mm cholangiocarcinoma in the bile duct in the pancreatic head with small lung metastases (Figure 1). The jaundice was relieved by ERCP and a 52 mm covered metal stent in September 2010 (Figure 2). In the

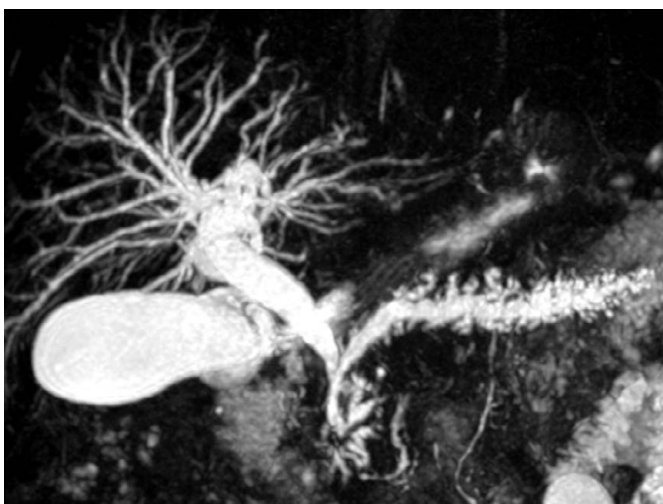


Figure 1. MRCP indicating double duct sign, and by fine needle aspiration diagnosed as distal bile duct cancer.

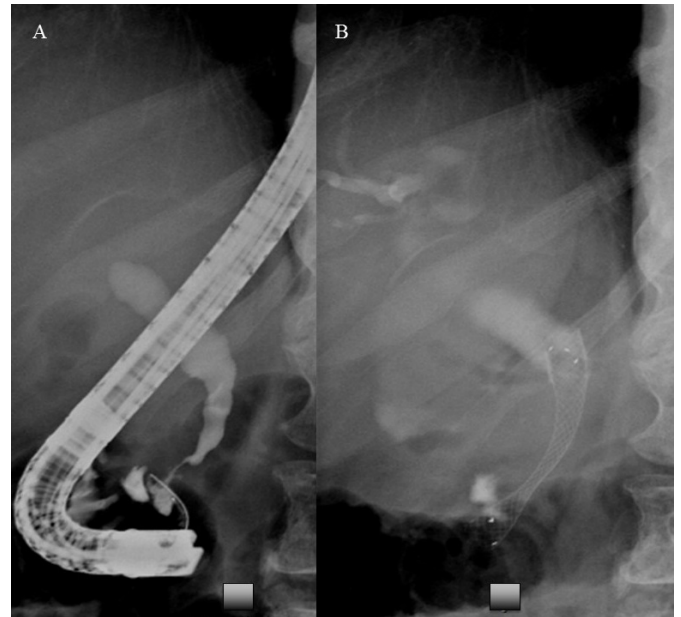


Figure 2. ERCP with 52 mm covered metal stent.

presence of lung metastases surgical removal with pancreaticoduodenectomy was not found appropriate. The patient began treatment with Capecitabine intermittently in October 2010. Due to experiencing serious cutaneous and gastrointestinal side-effects, treatment was switched to continuous Xeloda 500 mg x 2, beginning in January 2011. This treatment continued until November 2011. Progress in the lungs was shown by CT scan and therapy was changed to Gemzar/Oxaliplatin. Neurotoxicity led to the discontinuation of Oxaliplatin and intermittent treatment with Gemzar continued, with active treatment interspersed with long breaks in treatment. In June 2012 the patient had the first episode of cholangitis and stent dysfunction and a new ERCP with placement of a plastic stent inside the metal stent relieved the condition. A second episode of cholangitis in October 2013 where a new 80 mm metal stent was placed inside the originally placed stent. In April 2015 the patient had pyloric compression due to the tumour and received an uncovered duodenal metal stent, relieving the obstructive symptoms. The patient was an active golfer, travelling abroad a good deal. His strategy was not to allow the treatment to affect him or his day-to-day life and he continued to lead a very active existence with a high quality of life and very few symptoms until the spring of 2015, when his condition deteriorated relatively quickly and he died as a result of his disease in June 2015. The patient lived with his chronic cancer for 5 years, enjoying excellent quality of life until his final months.

### Case #2

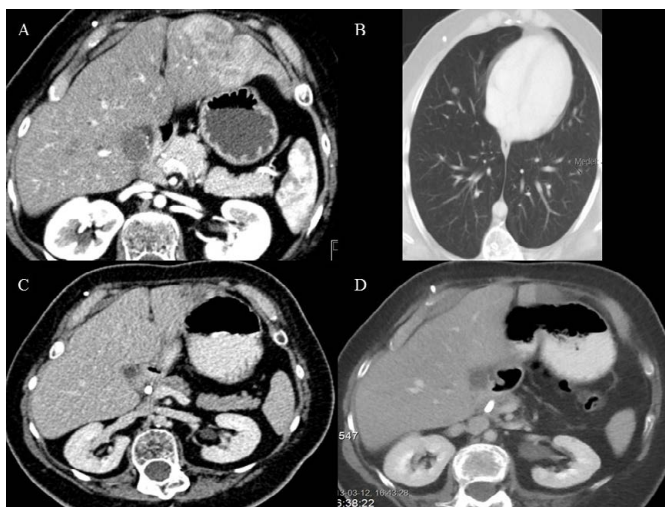
A Thirty-three-year-old man diagnosed with childhood ependymoma at the age of two. He was treated at the time until remission but relapsed at the age of ten, when he was treated with surgery and radiotherapy. This left him paraplegic and wheelchair-bound. In autumn 2010 he fell ill with silent jaundice and was diagnosed with a 70 mm intrahepatic cholangiocarcinoma in segment 3, and lymph node metastasis in the hepatoduodenal ligament

as well as 4 suspected lung metastases (**Figure 3a, b**). Surgery was considered but a limited resection of a lung metastasis confirmed a spread of the disease and he was therefore referred to Oncology for chemotherapy. The patient enjoyed good general health, working full-time as a school caretaker. He was extremely committed to treatment and highly motivated. Intermittent Capecitabine treatment was initiated in November 2010 but this was discontinued due to serious gastrointestinal and cutaneous side-effects. An attempt was made at treatment with continuous Xeloda 500 mg x 2 mg. In response to this treatment the patient showed tumour regression and the treatment was continued for a number of years (**Figure 3c**). He also underwent RFA treatment in April 2012 for the primary tumor in segment 3.21 mm in size at that time, and in November 2013 retreated due to local recurrence, resulting in prolonged tumour remissions (according to RECIST criteria) and was able to live for long periods completely without tumour-specific treatment, with only active monitoring and regular clinical testing (**Figure 3d**).

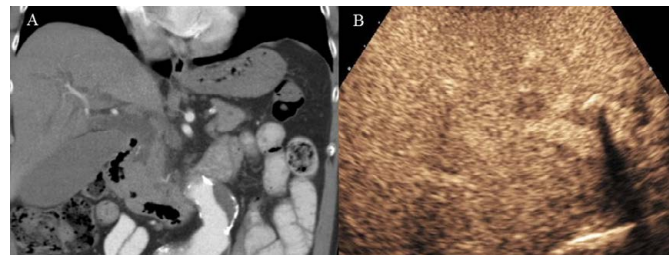
During the spring 2015 the patient's condition deteriorated, the final tumour-specific treatment being administered in June 2015, and the patient died in his sleep at home in September 2015. He survived for 5 years despite his cancer and was largely unaffected by the disease for 4.5 years.

### Case #3

A Seventy-five-year-old man who presented with silent jaundice in the summer of 2010. Examination revealed papillary of Vateri carcinoma with a liver metastasis in segment 5 (**Figure 4a, b**). The patient were diagnosed with Ultrasound guided biopsy of the liver metastasis and via ERCP biopsied and stented with a 7F 9 cm plastic stent, and the jaundice was relieved. The patient had no further episode of jaundice or cholangitis and the stent was never changed. The patient was a man of enormous vitality and was intent on maintaining a high level of social activity



**Figure 3. (a).** Tumour in segment 2 and 3 together with bile duct obstruction due to a tumour at the pancreatic head, **(b).** 8 mm metastasis in the right lung, **(c).** 1 year after diagnosis, tumor reduction in the liver and the tumor in the pancreatic head is not possible to detect and **(d).** Necrosis in segment 2/3 after radiofrequency ablation.



**Figure 4. (a).** CT scan of the abdomen showing distal obstruction of the bile duct due to a adenocarcinoma of the papilla of Vateri and **(b).** Ultrasound showing a 15 mm metastasis in the liver segment 4.

with the minimum of effect on quality of life. He began treatment with intermittent Xeloda. Follow-up computed tomography showed tumour regression according to RECIST criteria and a pause in treatment was taken at the patient's insistence and because of cardiovascular side-effects. When the tumour progressed the patient was placed on continuous Xeloda 500 mg x 2 mg. The patient suffered generally from vascular disease and also suffered a minor cerebral infarction which he made a good recovery from. Tumour-specific treatment ceased in April 2013 and the patient passed away peacefully at home in July 2013.

### DISCUSSION

As indicated by the above cases, patients with metastasising cholangiocarcinoma may react poorly to chemotherapy. All three patients began with intermittent Xeloda but were relatively quickly forced to discontinue treatment due to serious side-effects including diarrhoea and hand-foot syndrome. Patients who were initially highly treatment-motivated considered refraining from tumour-specific treatment as they experienced such difficulty with side-effects. On changing to continuous per oral treatment, side-effects were markedly reduced. Two patients experienced no side-effects at all while the third suffered grade 1-2 hand-foot syndrome. The third patient, with general vascular disease, who had suffered a heart attack and stroke while undergoing continual Xeloda treatment, also tolerated the treatment well and our medical judgement to continue the patient's Capecitabine treatment despite the stroke proved to be fruitful (**Table 1**).

In cases of incurable disease, it is important that the patient is able to enjoy the highest possible quality of life. In all three of these cases, the patients on the whole lived normal lives for several years with no great restrictions. Travel, work and social activities continued largely as normal.

These cases also illustrate that even in relation to these illnesses it is possible to use a Stop-and-Go approach, a generally accepted concept in the treatment of colorectal cancer but considerably less researched with other gastrointestinal cancers. Despite the intensive development on the therapy side, 5-FU still forms the basis for treatments of gastrointestinal cancer. However, continuous 5-FU treatment is unexplored in relation to cholangiocarcinoma in the palliative phase.

From an oncological perspective, cholangiocarcinoma is considered difficult to treat with the only possible

cure being radical surgery. When the disease has metastasised, the prognosis is considered pessimistic. In Sweden the median survival with oncological treatment only is about 6 months [15]. Unfortunately the number of active chemotherapy substances to choose from are limited.

Patients with unresectable and/or metastatic tumors have only chemotherapy as treatment option but when the response to treatment is missing, palliative intention is the only remaining alternative. In the settings of palliative chemotherapy the main goal is to prevent tumor progression as well as decrease symptoms with minimal reduction in QoL. In this setting continuous low-dose treatment may have advantages compared to the golden standard, conventional chemotherapy. Tumor control rates and good safety profile has been shown in phase II studies as the main clinical benefits of metronomic chemotherapy [13, 14].

Low dose treatment is a treatment concept that has previously been tested on breast cancer and prostate cancer but in the case of gastrointestinal cancer there is less experience. Since its discovery in 1956, 5-FU has been the cornerstone of treatments for gastrointestinal cancer and there are a number of different treatment schedules in which it is used in continuous infusion, intermittent bolus long-term transfusion over anything from 48 hours to 120 hours [6, 16, 17]. There are a variety of theoretical rationales and in clinical use it has not been possible with the different dose schemes to show any definite differences in various non-inferiority studies [18].

The introduction of the per oral substance Capecitabine created opportunities to further vary the administration of 5-FU. It was noted that toxicity varied, depending on whether the substance was administered per orally or intravenously. However, no difference could be observed in effect [20, 21, 22].

Previous publications have shown effects on colorectal cancer, oesophageal cancer, gastric cancer, liver cancer and lung cancer [5, 11, 23, 24]. Our units indications for metronomic treatment and experience with other diagnosis has previously been published [25].

One noticeable case report described a patient with transverse colon mucinous adenocarcinoma as well as 3 liver metastases [11]. Primary surgery was not found to be possible and the neoadjuvant chemotherapy regimen with oxaliplatin and fluorouracil failed due to infectious complications. The patient was therefore

referred to palliative care and treatment with metronomic Capecitabine with Avastin every other week was initiated. Four months into the treatment, radiology showed tumor regression and radical surgery was performed. At control, 9 months postoperatively, no recurrence was found. This case is of special interest as mucinous adenocarcinomas have previously been shown to have poor response to oncological treatment compared to non-mucinous adenocarcinomas [26, 27].

It seems likely that the mechanism of action of metronomic chemotherapy is different from that of classical chemotherapy. The usual treatment strategy with classical chemotherapeutic regimens is to administrate the cytostatic drugs intravenously and the dose used is usually close to the MTD. With this strategy, cancer is treated by inhibiting or killing cancer cells that divide rapidly. In order to inhibit mitosis and cause damage to DNA traditional chemotherapeutic agents commonly act as alkylators, inhibitors of enzymes or false metabolites [28]. The mechanisms involved in the effect of metronomic oncological treatment are not fully known. Initially this treatment was believed to control cancer growth by reduction of tumor angiogenesis, with recent studies it seems however that the mechanisms of action may be more complex than this [4].

*In vivo* and *in vitro* studies have shown anti-angiogenic effect of low-dose chemotherapy [8, 9, 10]. The mechanisms involved seem to include selective endothelial cell inhibition in regards to proliferation and migration as well as reduced levels of endothelial progenitor cells derived from the bone marrow and, in addition angiogenesis may be inhibited by increased thrombospondin-1 [29]. In other studies the immune system has been shown to induce tumor dormancy as a response to metronomic chemotherapy [7, 11]. This effect may be mediated through inhibition of T regulatory cells as well as through activation of dendritic cells. Apoptosis of cancer cells, immune-surveillance and suppression of angiogenesis represent 3 known pathways for the effect of metronomic chemotherapy [4]. It seems likely that the sparing of healthy tissue compared to cytotoxic treatment given at dose close to the MTD explains the relative paucity of side-effects. As treatment with continuous low dose cytostatic agents allows for tablet use and therefore does not necessitate hospital admission, this treatment strategy is favored by patients as well as physicians [23, 30]. Oral formulations have the advantage of lower cost and easier administration in addition to reduced need for hospitalization. Therefore it is possible

**Table 1:** Survival data from diagnosis in each patients.

| Patient                 | 1               | 2               | 3               |
|-------------------------|-----------------|-----------------|-----------------|
| Age / gender            | 67 years / male | 33 years / male | 75 years / male |
| Length of conv. chemo   | 3 months        | 2.5 months      | 18 months       |
| Side effects            | Cutaneous/GI    | Cutaneous/GI    | Cardiovascular  |
| Length of metron. chemo | 4.5 years       | 4.5 years       | 1.2 years       |
| Survival                | 4.7 years       | 5 years         | 3 years         |

that metronomic chemotherapy is cost effective compared to the conventional strategy [12].

Metronomic treatment of cholangiocarcinoma with cyclophosphamide has been previously reported, with results similar to the current cases [31]. Metronomic treatment with capecitabine is astonishingly free of side-effects, cost-effective and patients can be treated on an outpatient basis over long periods while maintaining quality of life and the ability to work. Despite the limited experience presented in this study this treatment alternative should be considered for patients with disseminated cholangiocarcinoma experiencing troublesome side effects of conventional chemotherapy. These three cases also indicate that survival may be prolonged compared to what is expected for this patient group. Furthermore, it seems that prospective studies are warranted to explore this alternative to conventional chemotherapy.

## Conflict of Interest

The authors declare that there is no conflict of interests regarding the publication of this paper.

## Reference

1. Ferlay J, Soerjomataram I, Dikshit R, Eser S, Mathers C, Rebelo M, Parkin DM, et al., Cancer incidence and mortality worldwide: sources, methods and major patterns in GLOBOCAN 2012. *International journal of cancer*. Int J Cancer 2015; 136:E359-86. [PMID: 25220842]
2. Archer VR, Billingham LJ, Cullen MH. Palliative chemotherapy: no longer a contradiction in terms. *Oncologist* 1999; 4:470-7. [PMID: 10631691]
3. Ringborg U, Dalianis T, Henriksson R, Onkologi. Liber Stockholm (2nd edn) 2008.
4. Maiti R. Metronomic chemotherapy. *J Pharmacol Pharmacother* 2014; 5:186-92. [PMID: 25210398]
5. Miger J, Holmqvist A, Sun XF, Albertsson M. Low-dose capecitabine (Xeloda) for treatment for gastrointestinal cancer. *Med Oncol* 2014; 31:870. [PMID: 24510794]
6. Mross K, Steinbild S. Metronomic anti-cancer therapy - An ongoing treatment option for advanced cancer patients. *J Cancer Ther Res* 2012; 1:32.
7. Bahl A, Bakhshi S. Metronomic chemotherapy in progressive pediatric malignancies: old drugs in new package. *Indian J Pediatr* 2012; 79:1617-22. [PMID: 22544675]
8. Hanahan D, Bergers G, Bergsland E. Less is more, regularly: metronomic dosing of cytotoxic drugs can target tumor angiogenesis in mice. *J Clin Invest* 2000; 105:1045-7. [PMID: 10772648]
9. Gasparini G. Metronomic scheduling: the future of chemotherapy? *Lancet Oncol* 2001; 2:733-40. [PMID: 1902515]
10. Kerbel RS, Kamen BA. The anti-angiogenic basis of metronomic chemotherapy. *Nature reviews. Cancer* 2004; 4:423-436. [PMID: 15170445]
11. Vernmark K, Albertsson M, Björnsson B, Gasslander T, Sandström P, Sun XF, Holmqvist A. From palliative to curative treatment - stage IV mucinous adenocarcinoma, successfully treated with metronomic capecitabine in combination with Bevacizumab and surgery- a case report. *BMC Cancer* 2015; 15:884. [PMID: 26555668]
12. Bocci G, Tuccori M, Emmenegger U, Liguori V, Falcone A, Kerbel RS, Del Tacca M. Cyclophosphamide-methotrexate 'metronomic' chemotherapy for the palliative treatment of metastatic breast cancer. A comparative pharmacoeconomic evaluation. *Ann Oncol* 2005; 16:1243-52. [PMID: 15905308]
13. Lien K, Georgsdottir S, Sivanathan L, Chan K, Emmenegger U. Low-dose metronomic chemotherapy: a systematic literature analysis. *Eur J Cancer* 2013; 49:3387-95. [PMID: 23880474]
14. Pasquier E, Kavallaris M, André N. Metronomic chemotherapy: new rationale for new directions. *Nat Rev Clin Oncol* 2010; 7:455-65. [PMID: 20531380]
15. väst RC. [Liver- and biliary cancer: National quality report for 2013]. Swedish 2014.
16. Wagstaff AJ, Ibbotson T, Goa KL. Capecitabine: a review of its pharmacology and therapeutic efficacy in the management of advanced breast cancer. *Drugs* 2003; 63:217-236. [PMID: 12515569]
17. Shi H, Jiang J, Ji J, Shi M, Cai Q, Chen X, Yu Y, et al., Anti-angiogenesis participates in antitumor effects of metronomic capecitabine on colon cancer. *Cancer lett* 2014; 349:128-135. [PMID: 24746899]
18. Longley DB, Harkin DP, Johnston PG. Johnston, 5-fluorouracil: mechanisms of action and clinical strategies. *Nat Rev Cancer* 2003; 3:330-8. [PMID: 12724731]
19. Hofheinz RD, Wenz F, Post S, Matzdorf A, Laechelt S, Hartmann JT, Müller L, et al. Chemoradiotherapy with capecitabine versus fluorouracil for locally advanced rectal cancer: a randomised, multicentre, non-inferiority, phase 3 trial. *Lancet Oncol* 2012; 13:579-88. [PMID: 22503032]
20. Walko CM1, Lindley C. Capecitabine: a review. *Clinical therapeutics* 2005; 27:23-44. [PMID: 15763604]
21. He S, Shen J, Hong L, Niu L, Niu D. Capecitabine "metronomic" chemotherapy for palliative treatment of elderly patients with advanced gastric cancer after fluoropyrimidine-based chemotherapy. *Med Oncol* 2012; 29:100-106. [PMID: 21264547]
22. Miwa M, Ura M, Nishida M, Sawada N, Ishikawa T, Mori K, Shimma N, et al., Design of a novel oral fluoropyrimidine carbamate, capecitabine, which generates 5-fluorouracil selectively in tumours by enzymes concentrated in human liver and cancer tissue. *Eur J Cancer* 1998; 34:1274-1281. [PMID: 9849491]
23. Fedele P, Marino A, Orlando L, Schiavone P, Nacci A, Sponziello F, Rizzo P, et al., Efficacy and safety of low-dose metronomic chemotherapy with capecitabine in heavily pretreated patients with metastatic breast cancer. *Eur J Cancer* 2012; 48:24-9. [PMID: 21775129]
24. Carstens H, Albertsson M. Successful treatment with low-dose capecitabine for disseminated esophageal adenocarcinoma. *Acta Oncol* 2007; 46:866-868. [PMID: 7653915]
25. Genfors D, Albertsson M. Low-dose Metronomic Capecitabine (Xeloda) for Treatment of Metastatic Gastrointestinal Cancer: A Clinical Study. *Arch Canc Resea* 2016; 4:51.
26. Shin US1, Yu CS, Kim JH, Kim TW, Lim SB, Yoon SN, Yoon YS, ET AL. Mucinous rectal cancer: effectiveness of preoperative chemoradiotherapy and prognosis. *Ann Surg Oncol* 2011; 18: 2232-2239. [PMID: 21347780]
27. Lupinacci RM, Mello ES, Coelho FE, Kruger JA, Perini MV, Pinheiro RS, Fonseca GM, et al., Prognostic implication of mucinous histology in resected colorectal cancer liver metastases. *Surgery* 2014; 155:1062-1068. [PMID: 24856126]
28. Malhotra V, Perry MC. Classical chemotherapy: mechanisms, toxicities and the therapeutic window. *Cancer boil ther* 2003; 2:S2-4. [PMID: 14508075]
29. Pietrantonio F, Biondani P, Pellegrinelli A, Marchianò A, Dotti KF, Buzzoni R, Di Bartolomeo M. Hepatic colorectal cancer metastases showing a distinctive pattern of pathological response after metronomic capecitabine and bevacizumab. *Med Oncol* 2012; 29:2838-2841. [PMID: 22271433]
30. Finek J, Holubec L Jr, Svoboda T, Sefrhansova L, Pavlikova I, Votavova M, Sediva M, et al. A phase II trial of oral vinorelbine and capecitabine in anthracycline pretreated patients with metastatic breast cancer. *Anticancer Res* 2009; 29:667-670. [PMID: 19331218]
31. Banavali SD, Patil NR, Nirabhawane VS, Bhosale BB, Desai SB. Can combination metronomic therapy overcome chemoresistance in cholangiocarcinoma? A literature review. *Indian J Cancer* 2013; 50:149-53. [PMID: 23979207]