

DOI: 10.21767/2471-8165.1000038

# Intra-Peritoneal Leiomyoma of the Round Ligament in a Patient with Mayer-Rokitansky-Kuster-Hauser (MRKH) Syndrome

**Salem Wehbe G<sup>1</sup>, Bitar R<sup>2</sup>, Zreik T<sup>2</sup>, Walter C<sup>3</sup> and Sleiman Z<sup>1\*</sup>**<sup>1</sup>Lebanese University School of Medicine, Lebanon<sup>2</sup>Lebanese American University School of Medicine, Lebanon<sup>3</sup>Geneva University, Switzerland

\*Corresponding author: Sleiman Z, The European Academy for Gynecological Surgery, Lebanese American University School of Medicine, Lebanon, Tel: +32(0)16629629; E-mail: zakinexus@hotmail.com

Received date: 28 September, 2016; Accepted date: 15 December, 2016; Published date: 19 December, 2016

Citation: Salem Wehbe G, Bitar R, Zreik T, et al. Intra-Peritoneal Leiomyoma of the Round Ligament in a Patient with Mayer-Rokitansky-Kuster-Hauser (MRKH) Syndrome, Gynecol Obstet Case Rep. 2016, 2:3.

## Abstract

**Background:** The occurrence of an extra-uterine leiomyoma, arising from the intra-peritoneal portion of the round ligament in a lady with Müllerian agenesis diagnosed at the age of forty is extremely rare. We report a case of this rare combination in a Middle Eastern woman.

**Case:** A 40 years old lady, primarily amenorrheic, presented to our clinic for an infertility consultation. The work-up showed features suggestive of Mayer-Rokitansky-Küster-Hauser (MRKH) syndrome with a leiomyoma arising from the intra-peritoneal part of the round ligament.

## Introduction

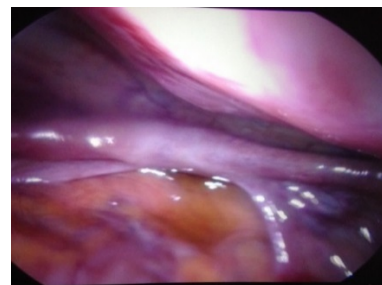
The Mayer-Rokitansky-Küster-Hauser (MRKH) syndrome or Müllerian agenesis is characterized by the congenital absence of the upper vagina, cervix and uterus. Its incidence is 1:4,500 female births [1]. It is the second most common cause of primary amenorrhea following ovarian failure [2]. Girls with Müllerian agenesis have normal childhood and they usually do not seek professional advice until puberty when the syndrome presents as primary amenorrhea, otherwise they have normal development of secondary sexual characteristics, normal external genitalia, functional ovaries, and a normal karyotype of 46, XX [1].

In this case report, we present a case of intra-peritoneal leiomyoma of the round ligament in a patient diagnosed, for the first time at age of forty, to have the Mayer-Rokitansky-Küster-Hauser (MRKH) syndrome.

## Case Description

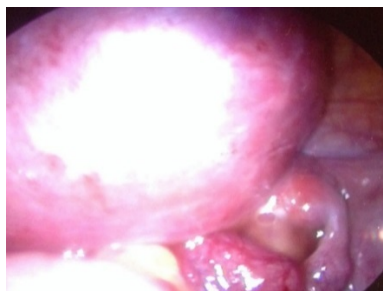
A 40 years old Iraqi lady consulted our private gynecology clinic 3 months after marriage for infertility problem. Upon

primary clinical assessment, she reported primary amenorrhea for which has never been evaluated. Otherwise, her previous medical and surgical histories were normal. Pubarche started at 10 years of age, and thelarche at 12 years. Her family history was negative. Physical examination showed a normal stature lady with normal breasts, axillary and pubic hair development. No hirsutism, acne or galactorrhoea. Inspection of genital area showed normal external genitalia and a blind vaginal pouch. The pelvic examination revealed a palpable mobile firm mass. Office trans-abdominal pelvic ultrasound showed eight centimeters hypoechoic well delineated pelvic mass containing few calcifications. Ovaries were normal, but the uterus couldn't be identified. Laboratory work-up including full endocrine assessment and tumor markers was normal. Mayer-Rokitansky-Küster-Hauser (MRKH) syndrome was then suspected. An abdominal ultrasound showed both normally located kidneys. A pelvic MRI was suggested in order to prove the diagnosis and characterize the pelvic mass, but the lady refused because of financial limitation. She asked to skip to a definitive diagnostic procedure. She was scheduled for a diagnostic laparoscopy as being part of primary amenorrhea work up and for the pelvic mass assessment.



**Figure 1** Laparoscopic view showing the Müllerian agenesis

Diagnostic laparoscopy showed normal ovaries and fallopian tubes, the total absence of the uterus (**Figure 1**) and a solid pelvic mass arising from the right-sided intra-peritoneal part of the round ligament (**Figure 2**).



**Figure 2** Laparoscopic view showing the right round ligament leiomyoma

In the absence of a written consent of the patient to perform the mass removal, the patient was rescheduled for a laparotomy. In fact, with the doubt of the mass type, and the fear of the presence of leiomyosarcoma, we did not suggest a laparoscopic myomectomy with the use of power morcellator. We counselled the patient concerning the possibility of vaginoplasty and the fertility potential with the help of a surrogate mother. Laparotomy was performed in another clinic one month later and the pathology report revealed a leiomyoma with some epithelioid features, moderate myxoid and hyalinized changes.

## Discussion

Mayer-Rokitansky-Küster-Hauser syndrome leading to Müllerian remnant leiomyomas is uncommon but should be suspected in women in whom a pelvic mass develops after the confirmation of the Müllerian defect. Authors reported few cases of this rare combination [3-7].

Tumours affecting the round ligament are rare. The most commonly found tumors are leiomyomas. Other tumors have been reported such as endometrioma, mesothelial cysts, secondary adenocarcinomas, sarcoma [8]. One-half to two-thirds of round ligament leiomyomas occur in the extra-peritoneal portion of the round ligament [9].

The uterine round ligaments originates from the embryonic female gubernaculum [10]. Thus, they are in place in Müllerian agenesis. However, the combination of the occurrence of an extra-uterine leiomyoma, arising from the intra-peritoneal portion of the uterine round ligament in a lady with Müllerian agenesis diagnosed at age of forty is extremely rare. Only one case report of leiomyoma arising from the round ligament in a patient with (MRKH) syndrome has been reported. In contrast to our case, the mass was located in the left inguinal canal mimicking an incarcerated inguinal hernia or inguinal adenopathy [11].

In many cultures, infertile ladies suffer discrimination and experience stigmatization and ostracism in their relationships with in-laws and community members [12]. A woman to be socially acceptable should have at least one biological child [13]. In the Middle East, infertility affects the marital dynamics: it leads to instability, divorce or polygamous

remarriage [12]. Thus, it is not surprising to find a woman seeking medical advice for her primary amenorrhea at the age of forty in order to hide her fertility problem, and being diagnosed to have MRKH syndrome after her marriage.

Imaging plays a crucial role in the non-invasive and accurate initial diagnosis of MRKH syndrome. It is useful in depicting potential associated abnormalities. Radiologists are important elements of the multidisciplinary team taking care of patients with MRKH syndrome. Trans-abdominal ultrasonography can initially suggest the diagnosis of Müllerian agenesis, and evaluate associated renal anomalies. The trans-vaginal imaging is often impossible in this group of patients. The three-dimensional (3D) ultrasound is of limited value in MRKH syndrome since there are no structures to reformat. MRI is the most accurate technique and is recommended to provide more detailed and objective information. It allows specialists to postpone laparoscopic intervention until constructive surgery is required or when the diagnosis remains doubtful [14].

The role of routine diagnostic laparoscopy as part of the initial work up for patients suspected to have MRKH syndrome is of limited value when compared to MRI, but still necessary in some situations [14]. Dragusin performed a diagnostic laparoscopy in a case of MRKH because imaging couldn't identify the ovaries. In fact, both ovaries were found in an ectopic high position, in the right and left superior quadrants, with adjacent small fallopian tubes [15]. In our case, it was the presence of a pelvic mass and the non-availability of MRI that lead us to perform the diagnostic laparoscopy.

Laparoscopy allows excellent analysis of a solid pelvic tumor in a patient with MRKH syndrome [16]. After adequate characterization of the lesion, laparoscopy offers the surgical access for its removal. Tsin et al. were the first team reporting a successful laparoscopic management of an 8.5 cm size leiomyoma arising from vestigial Müllerian duct in a patient with MRKH syndrome [17]. We are the first team to report the diagnosis of an 8 cm size leiomyoma arising from the intra-peritoneal portion of the round ligament. Because of the older age of the patient (40 years old) and the lack of enough imaging features of the non-malignancy of the mass at the time of laparoscopy, the removal was done by laparotomy.

## Conclusion

The presence of leiomyoma is a diagnosis to consider in patients with MRKH syndrome. Leiomyoma can originate from the Müllerian remnants but also from the non-Müllerian structures.

## References

1. Morcel K, Camborieux L (2007) Research program on müllerian aplasia, warrior D. Mayer-Rokitansky-Küster-Hauser (MRKH) syndrome. *Orphanet J Rare Dis* 2: 13.
2. Reindollar RH, Byrd JR, McDonough PG (1981) Delayed sexual development: A study of 252 patients. *Am J Obstet Gynecol* 140: 371-380.

3. Fletcher HM, Campbell-Simpson K, Walcott D, Harriott J (2012) Müllerian remnant leiomyomas in women with Mayer-Rokitansky-Küster-Hauser syndrome. *Obstet Gynecol* 119: 483-485.
4. Farber M, Stein A, Adaghi E (1978) Rokitanski-Küster-Hauser syndrome and leiomyoma uteri. *Obstet Gynecol* 51: 70-73.
5. Deligeoroglou E, Kontoravdis A, Makrakis E, Christopoulos P, Kountoris A, et al. (2004) Development of leiomyomas on the uterine remnants of two women with Mayer-Rokitansky-Küster-Hauser syndrome. *Fertil Steril* 81: 1385-1387.
6. Yan CM, Mok KM (2002) Uterine fibroids and adenomyosis in a woman with Mayer-Rokitansky-Küster-Hauser syndrome. *J Obstet Gynaecol* 22: 561-562.
7. Rawat KS, Buxi T, Yadav A, Ghuman SS, Dhawan S (2013) Large leiomyoma in a woman with Mayer-Rokitansky-Küster-Hauser syndrome. *J Radiol Case Rep* 3: 39-46.
8. Breen JL, Neubecker RD (1962) Tumors of the round ligament: A review of literature and a report of 25 cases. *Obstet Gynecol* 19: 771-780.
9. David MW, Stanley RM (1999) Leiomyoma of extraperitoneal round ligament: CT demonstration. *Clin Imaging* 23: 375-376.
10. Acién P, Sánchez del Campo F, Mayol MJ, Acién M (2011) The female gubernaculum: Role in the embryology and development of the genital tract and in the possible genesis of malformations. *Eur J Obstet Gynecol Reprod Biol* 159: 426-432.
11. Rhee CS, Kim JS, Woo SK, Suh S (1999) MRI of round ligament leiomyoma associated with Mayer-Rokitansky-Kuster-Hauser syndrome. *J Abdom Imaging* 24: 202-204.
12. Inhorn MC (2003) Global infertility and the globalization of new reproductive technologies: Illustrations from Egypt. *Soc Sci Med* 56: 1837-1851.
13. Cui W (2010) Mother or nothing: the agony of infertility. *Bull World Health Organ*. 88: 881-882.
14. Rousset P, Raudrant D, Peyron N, Buy JN, Valette PJ, et al. (2013) Ultrasonography and MRI features of the Mayer-Rokitansky-Küster-Hauser syndrome. *Clin Radiol* 68: 945-952.
15. Dragusin R, Tudorace S, Surlin V (2014) Importance of laparoscopic assessment of the uterine adnexa in a Mayer-Rokitansky-Kuster-Hauser syndrome type II case. *Curr Health Sci J* 1: 144-147.
16. Lanowska M, Favero G, Schneider A, Köhler C (2009) Laparoscopy for differential diagnosis of a pelvic mass in a patient with Mayer-Rokitanski-Küster-Hauser (MRKH) syndrome. *Fertil Steril* 91: 931.e17-18.
17. Tsin DA, Waters TK, Granato RC (2000) Laparoscopic myomectomy in a patient with Mayer-Rokitansky-Kuster-Hauser syndrome. *J Am Assoc Gynecol Laparosc* 7: 411-413.