

DOI: 10.36648/2471-8157.7.6.133

Intermediate-term Outcome Following Plain Balloon Angioplasty of Discrete Near-total or Total Occlusion of Aortic Coarctation

Bhosale KH* and Ranjit Kumar Nath RK

Department of Cardiology, Ram Manohar Lohia Hospital, New Delhi, India

***Corresponding author:**
Bhosale KH

✉ kkbhosale19@gmail.com

Tel: 8826429101

Department of Cardiology, Ram Manohar Lohia Hospital, New Delhi, India

Citation: Bhosale KH, Ranjit Kumar Nath RK (2021) Intermediate-term Outcome Following Plain Balloon Angioplasty of Discrete Near-total or Total Occlusion of Aortic Coarctation. *Interv Cardiol J* Vol.7 No.6:133

Abstract

Objective: Surgical repair or stenting has been the standard treatment for patients with discrete near-total or total occlusion of aortic Coarctation (CoA) in both adolescents and adults. The role of plain Balloon Angioplasty (BA) as definitive therapy has not been well established in these patients due to the reported higher rates of complication and re-coarctation. The purpose was to evaluate intermediate-term outcome following BA of such patients by using different techniques in those patients where surgery or stenting was not possible.

Materials and Methods: The data of 9 patients of such CoA treated with BA from January 2014 to December 2018 was analyzed. The approach for BA was retrograde in 4 patients and ante grade in 5 patients. Different stiff coronary hardware was used in some cases to cross the occluded segments and make the procedure successful. They were evaluated at a mean interval of 43 months (range 14-72 months). The assessment included clinical examination, echocardiography, and cardiac catheterization as and when required.

Results: The mean age of studied patients was 27.88 year (range 14–52 years). Immediate success was obtained in all patients with no early mortality or major complications. Peak systolic pressure gradient reduced from 79.11 19mmHg to 10.89 7.11mmHg immediately. On follow-up, out of the 5 patients who had Doppler peak gradient of more than 20 mmHg, none had significant peak systolic gradient on catheterization. There was no mortality or serious complications on follow-up. Hypertension was completely relieved in 45% (4/9) and improved in 55% (5/9) patients.

Conclusion: Balloon angioplasty of discrete near-total or total occlusion of native CoA by different method is safe and effective on the intermediate follow-up and can be considered in patients who are not candidates for surgery or stenting.

Keywords: Coarctation of aorta; Balloon angioplasty; Chylothorax; Subclavian

Received: April 05, 2021; **Accepted:** April 19, 2021; **Published:** April 26, 2021

Introduction

Coarctation of Aorta (CoA) is the congenital narrowing of the descending aorta, which typically involves the area around the insertion of the ducts arteriosus, just distal to the left sub-clavian artery. The incidence of CoA is 6-8% of all the congenital heart diseases. In severe cases of CoA there may be a complete loss

of luminal continuity between the arch and descending aorta. Because of the close anatomic resemblance, the differential diagnosis of totally occluded CoA from interrupted aortic arch should be made before determining the treatment strategy [1]. CoA patients without correction have reduced life expectancy because of several complications such as hypertension, stroke,

aortic dissection, accelerated coronary heart disease and heart failure [2].

Surgical repair is the standard treatment for patients with totally occluded CoA, but there have been reports of treatment with percutaneous intervention. In 1982, the balloon dilatation of CoA was used for the first time. Later in 1991 the first stent implantation was introduced. Stenting is presently the preferred method for treatment of CoA in adults if surgery is either declined or the patient is unfit [3]. The clinical presentation and response to treatment of patients with isolated totally occluded CoA is similar to that of the patients with isolated CoA.

Surgery was recommended to all our study patients, but some of them were not fit and the others declined surgery due to the associated risk [4]. Surgery has its own disadvantages like increased risk of bleeding complications, a small risk of recurrent laryngeal nerve injury, phrenic nerve injury, Chylothorax, wound infection, post-coarctectomy syndrome, aortic dissection, paraplegia, and paradoxical hypertension. Currently, endovascular procedures have been proposed as an alternative treatment for totally occluded CoA. They are preferred to surgical approach because of their less invasive nature and rapid recovery period with high success rates [5-9]. Techniques used include radiofrequency perforation, coronary chronic total occlusion technique, and perforation using the stiff end of a guide wire. A case using the Brocken brought needle technique has also been reported. Cowley et al. found the same outcome of relief of obstruction and an equivalent need for repeat intervention for both surgery and BA, but the risk of aneurysm formation was higher with BA.

Patients in our study were from the resource-constrained segment of society and had neither medical insurance cover nor Medicare cover for stenting. Different coronary hardware was used for some cases to cross the occluded segments and make the procedure successful. BA with graded dilatation may give lasting results with good outcomes in these patients. So, it was decided to perform percutaneous treatment of the near-total or totally occluded CoA with graded dilatation balloon angioplasty [10].

Methods

Study population

Between 2014 and 2018, 9 adolescent and adult patients with native total or near-total occlusion of CoA were seen at our institution. The indication for BA included angiographic evidence of significant discrete aortic co-arctation with co-arctation peak systolic gradient more than 20mmHg at cardiac catheterization along with proximal uncontrolled hypertension and/or heart failure [11]. Those who are having gradient less than 20 mm Hg but with LV dysfunction or significant collaterals were also included. The demographic, clinical, imaging, and catheterization data of these patients was reviewed. All the patients were given antihypertensive treatment with a combination. However, the Blood Pressure (BP) was not controlled-with-medical-management alone [12]. After informed consent and prior discussion with the cardiovascular surgeon, we moved ahead with the balloon angioplasty.

Definition

Diagnosis of CoA was suspected in all patients clinically after upper limb hypertension and weak femoral pulses. Discrete co-arctation of the aorta was defined as shelf-like morphology in angiographic images [13-17]. Total CoA was defined when there was no detectable flow across co-arctation on both retrograde and ante grade injection of iodinated contrast. Near-total CoA was defined when there was nearly 99% occlusion or faint opacification of the distal aorta through a defect in the ante grade injection of contrast. Successful outcome after BA was defined as a peak systolic gradient of ≤ 20 mmHg in catheter pullback after the final BA without any complication. Aneurysm was defined as an area of dilatation which was 150% of the aortic diameter at the level of the diaphragm or a discrete secular dilatation at the site of CoA that was not present before the intervention. Re-coarctation was defined as residual gradient >20 mm Hg at rest on follow-up catheterization.

Balloon angioplasty technique

Right Femoral Artery (FA) access, under local anesthesia, was established using anatomical landmarks with appropriately sized sheath in all the patients [18]. After systemic heparinization (60 IU/kg), multipurpose catheter 5F or 6F was introduced in descending aorta up to the point of occlusion of CoA. The hand injection of contrast showed a blind loop of the aorta in some of the patients (**Figure 1**).

Initially, in all patients we tried both soft and hard end of 0.035" straight tip hydrophilic Radio focus (Terumo Corporation, Japan) guide wire to cross the coarcted segment. In two of the patients, with some effort, the coarcted segment was crossed with the soft end of the straight Radio focus guide wire in a retrograde approach. In the remaining patients, the hard end of Radio focus guide wire was tried for some more time with careful maneuver, and it was successful in two of the patients, one with near-total coarctation and the other with total coarctation. For the remaining patients, aortic arch was accessed antero gradely through the right radial artery [19].

(RA) in three patients and left radial artery in two patients with a 4F or 5F right coronary diagnostic catheter (Judkins Right) [20,21]. After making sure that the distal ends of the two catheters were well aligned in two orthogonal views (antero-posterior and lateral) simultaneous arch angiogram and descending aorta angiogram were performed with contrast injection in the antero-posterior and lateral projections. Among three patients with right RA approach, one of the coarcted segments was crossed with the hard end of straight 0.035" Radifocus guidewire, second with the soft end of straight 0.035" Radifocus guide wire and the third with GAIA Third coronary angioplasty guide wire (GAIA third, Asahi Intec, Japan). In the remaining two patients, left RA access was taken. The crossing of coarctation was again tried with 0.035" Radifocus and GAIA Third guide wire but it was unsuccessful, so it was subsequently exchanged with a tapered-tip stiff guide wire i.e. Conquest Pro12 (Conquest Pro, Asahi Intec, Japan) (**Figure 2**).

In the three patients in whom coronary wire was used, it was first dilated with a coronary non-compliant balloon, after exchanging the Judkins right coronary diagnostic catheter with a

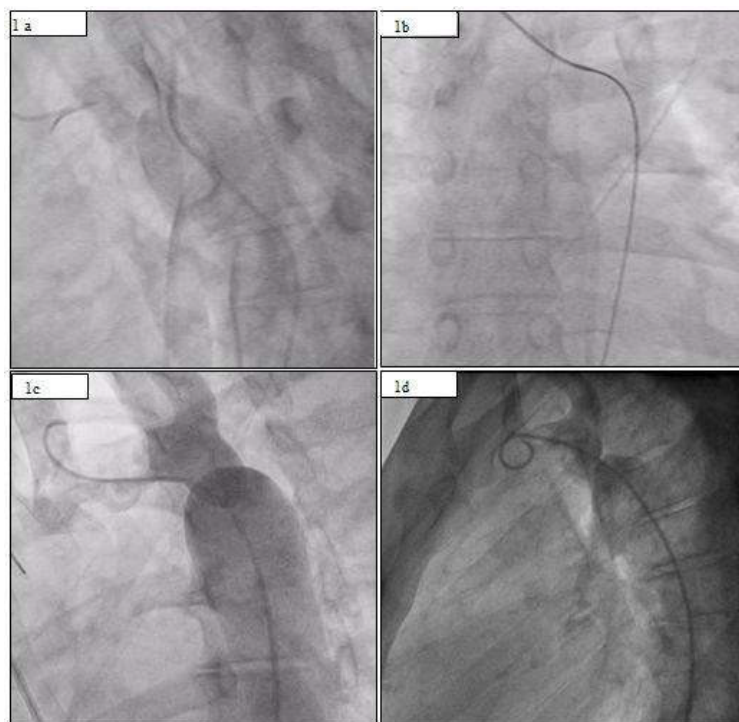


Figure 1 a) Pre-dilatation aorta gram showing total occlusion of coarctation in lateral view.
b) Crossing of coarctation segment from right RA approach with hard end of the 0.035" Radio focus guide wire.
c) Immediate post- dilatation aorta gram in lateral view.
d) Follow up aorta gram in lateral view at 2 year.

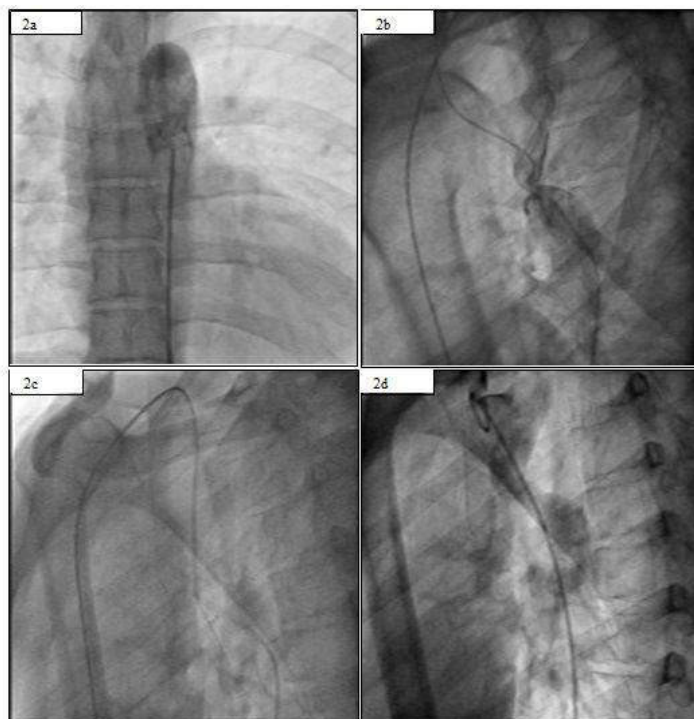


Figure 2 a) Pre-dilatation aorta gram showing total occlusion of coarctation in Antero-posterior view.
b) Pre- dilatation simultaneous anterograde and retrograde aorta gram in lateral view showing total CoA.
c) Crossing of coarcted segment from left RA by use of Conquest Pro 12 guide wire.
d) Immediate post- dilatation aorta gram in lateral view.

Judkins right 5F coronary guide catheter. Subsequently, the guide catheter was advanced across the lesion over the guide wire and balloon assembly was exchanged with Amplatz super-stiff guide wire (St. Jude Medical Inc., MN, and USA). In the case of ante grade crossing, Amplatz super-stiff wire was snared out through the femoral sheath using a goose-neck snare and all subsequent procedures were performed through femoral approach keeping the other end of the wire near the radial sheath. Over these guide wires over-the-wire balloon dilatation catheters (OTW), starting with size 12 mm and then gradually increasing, were advanced across the lesion with the final balloon size 1 to 2 mm less or equal to the size of the aorta at diaphragm depending upon the result and residual gradient. The balloon was inflated till the waist had easily disappeared without exerting excess force. After balloon dilatation, the pressure gradient was measured with over the wire pull back multi track catheter or 5F Judkins right

coronary guide without losing the guide wire access in case of requirement for further dilatation. A check angiogram was taken with a pigtail catheter in the end for evaluation of the final result. In the end, angiography showed almost complete establishment of a lumen in the coarcted segment of the aorta. All the patients were discharged after a 48 hour observation period.

Follow-up evaluation

The follow-up was done in the cardiology clinic after 1 month, 3 months, and thereafter 6 monthly. Their follow-up was accomplished by assessment of peripheral pulse, BP measurement in both arms and legs and echocardiography. Those who had Doppler peak gradient of > 20 mmHg after 6 months of the index procedure, underwent repeat catheterization and aortography with pressure measurement across the coarctation segment and if necessary, repeat dilatation (**Figure 3**).

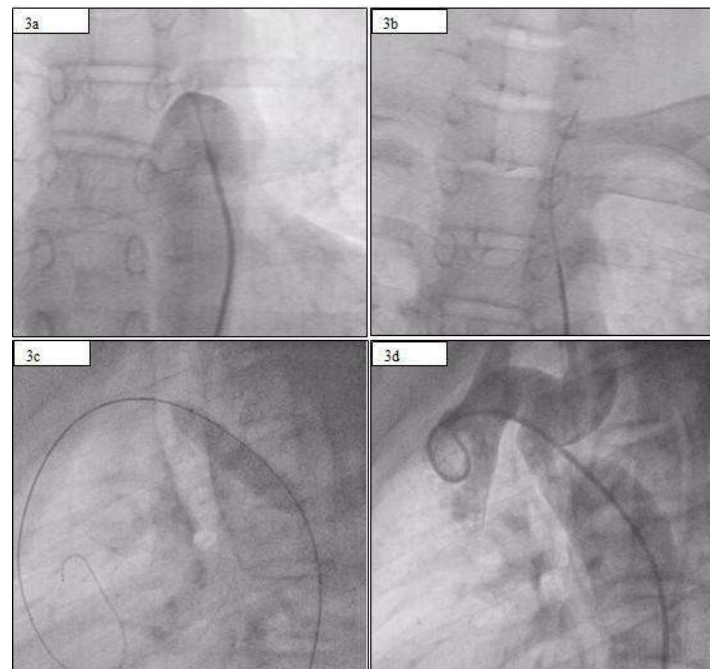


Figure 3 a) Pre-dilatation aorta gram showing total occlusion of CoA in Antero-posterior view.
b) Crossing of coarcted segment with hard end of 0.035" Radio focus guide wire.
c) Balloon dilatation of CoA in lateral view.
d) Immediate post-dilatation aorta gram in lateral view.

Table 1: Follow-up clinical and imaging data of study patients.

Serial no.	Follow up duration (months)	Blood pressure in Upper limb (mmHg)	Doppler gradient on last follow-up (mmHg)	Peak systolic gradient on Catheter ization (mmHg)	Complic ations on follow up
1	72	130/76	24	4	No
2	68	138/94	26	6	No
3	64	142/96	12	-	-
4	48	136/78	22	16	No
5	44	122/88	14	-	-
6	36	150/88	28	18	No
7	22	138/78	30	14	No
8	20	132/86	12	-	-
9	14	118/72	14	-	-

Results

Study subjects

A total of nine adolescent and adult patients (3 females) underwent BA for native discrete near-total or total occlusion of CoA during this 5-year period. Their age ranged from 14 to 52 (Mean age 27.88) years. Two of the patients had a bicuspid aortic valve without significant gradient or regurgitation across the valves. All the patients were hypertensive (Systolic BP 150-198 mmHg). The mean systolic blood pressure gradient in the upper limb and the lower limb was 68 mmHg. The mean of peak Doppler gradient across coarctation was 68.88 mmHg (range 32-88 mmHg).

Immediate results

The mean peak systolic catheter gradient across coarctation was 79.11 mmHg (range 59 to 98 mmHg) which decreased to 16.67 mmHg (range 12-22 mmHg) after BA. Doppler peak gradient was reduced from 68.88 to 20 mmHg. There were no immediate deaths, dissection of the aorta, or thrombosis of the femoral artery.

Intermediate follow-up

Follow up was ranged from 14 to 72 months (mean 43 months). The peak Doppler gradient across the coarctation site decreased from 58 mmHg before angioplasty to 20.00 mmHg after angioplasty. Follow-up catheterization and angiography was performed in five patients who had peak Doppler gradient of >20 mmHg across coarctation. All the 5 patients had < 20 mmHg peak systolic gradient across coarctation in the catheterization laboratory. There was no re-coarctation and aneurysm formation. The BP was normal (< 140/90 mm Hg) without medication in 4 patients. There maining 5 patients were on regular antihypertensive treatment in reduced doses than before the intervention (**Table 1**).

Discussion

This study has demonstrated excellent intermediate-term results of BA of discrete near-total and total occlusion of native aortic coarctation, and we propose that it can be used as one of the initial options for the treatment of discrete coarctation in patients with resource constraint situation. Pressure gradient drops across the coarctation segment were immediately significant in all cases and proved durable in all the cases of coarctation. Persistent hypertension was improved or even completely relieved in the majority of patients.

The balloon dilatation method can result in serious complications such as the formation of an aneurysm, aortic dissection, or aortic rupture. Previously, investigators had demonstrated that the outcome with BA was not significantly different from stent implantation. Various studies have shown that stent implantation is associated with lower complication rates when compared to balloon angioplasty alone and surgery. But in our study, all the patients were from resource-constrained situations and without any medical insurance facility for the treatment. As stenting is associated with prohibitive costs, we went ahead with only BA after discussion with patients or relatives and after having

discussed with the cardiac surgery team for necessary back-up, if required.

The presence of cystic medial necrosis was the proposed mechanism for the development of aneurysm that may provide a pathologic basis for the development of aneurysms associated with native coarctation, after BA and stent implantation. Although in our study no one developed aneurysm, early studies have reported a high incidence of aneurysm formation after BA; with the incidence varying between 1.8% and 15% [18,19]. Oversized balloon and use of very high pressure for dilatation might be the possible causes which were deliberately avoided. Close follow-up is required for patients with or without aneurysm, and MRI is a valuable non-invasive imaging modality for patients who have undergone coarctation angioplasty without stenting.

Blood pressure was reverted to normal without medication in 45% (4/9) of patients. (30%), we encountered a higher number of patients requiring medication i.e. 55% (5/9) to control hypertension after angioplasty. Hypertension in the absence of residual coarctation appears to be related to the duration of pre- angioplasty hypertension and insufficient resetting of the baroreceptors after BA. However, all patients treated with BA should be monitored closely for recurrence of hypertension for longer follow- up periods. In our study, on a mean follow up of 3.5 years no patient developed re- coarctation. Previous studies have reported the re-coarctation rate varying from 0% to 9% in adults.

Our case series has two unique features. The first is the use of BA only for the treatment of near-total or totally occluded aortic coarctation. The second is the utilization of the techniques used in the standard treatment of the coronary artery Chronic Total Occlusions (CTO) angioplasty. Our approach was successful in the treatment of total occluded CoA using the coronary CTO technique for recanalization. The present case series suggests that BA alone can also be efficient in the treatment of near-total or total occlusion of CoA.

Conclusion

This study demonstrated safety and efficacy of BA for native discrete near-total and total occlusion of CoA at intermediate-term (average 3.5 years) follow-up in adolescent and adult patients. Accordingly, we recommend that BA can be considered as an alternative option for the treatment of discrete near-total and totally occluded CoA in adolescent and adult patients in a resource-constrained situation or if surgery is not possible.

References

1. Jie H, Kaplan S (2002) The incidence of congenital heart disease. *J Am Coll Cardiol* 39: 1890-1900.
2. Kaneda T, Miyake S, Kudo T (2003) Obstructed coarctation in a right aortic arch in an adult female. *Thorac Cardio Vasc Surg* 51: 350-352.
3. Vriend JW, Lam J, Mulder BJ (2004) Complete aortic arch obstruction: interruption or aortic coarctation?. *J In Cardio vasc Imaging* 20: 393-396.
4. Yazici HU, Ulus T, Temel K (2012) Percutaneous treatment of totally occluded the coarctation of the aorta with angioplasty and stenting. *Eur Rev Med Pharma Col Sci* 16: 96-99.

5. Singer MI, Rowen M, Dorsey TJ (1982) Transluminal aortic balloon angioplasty for coarctation of the aorta in the newborn. *Am Heart J* 103: 131-132.
6. Laughlin MP, Perry SB, Lock JE, Mullins CE (1991) Use of endovascular stents in congenital heart disease. *Circulation* 83: 1923-1939.
7. Holzer R, Qureshi S, Ghasemi A (2010) Stenting of the coarctation of the aorta: acute, intermediate, and long-term results of a prospective multi-institutional registry Congenital Cardiovascular Interventional Study Consortium (CCISC). *Catheter Cardio Vasc Interv* 76: 553-563.
8. Joseph G, Mandalay A, Rajendiran G (2001) Percutaneous recanalization and balloon angioplasty of congenital isolated local atresia of the aortic isthmus in adults. *Catheter Cardio Vasc Interv* 53: 535-41.
9. Bozzani A, Arici V, Ragni F (2013) Thoracic aorta coarctation in the adults: open surgery is still the gold standard. *Vasc Endovascular Surg* 47: 216-218.
10. Anagnostopoulos TA (2007) Management of aortic coarctation in adults: endovascular versus surgical therapy. *Hellenic J Cardiol* 48: 290-295.
11. Goel PK, Syal SK (2008) Percutaneous reconstruction of aortic isthmus atresia using coronary total occlusion technique. *J Cardiol Cases* 10: 121-125.
12. Lenk K, Dähnert I, Schuler G (2008) Complete occlusion of the aortic isthmus. *Eur Heart J* 2: 29-30.
13. Cowley CG, Orsmond GS, Feola P (2005) Long-term, randomized comparison of balloon angioplasty and surgery for native coarctation of the aorta in childhood. *Circulation* 111:3453-6.
14. Beekman RH, Rocchini AP, Dick M (1987) Percutaneous balloon angioplasty for native coarctation of the aorta. *J Am Coll Cardiol* 10: 1078-84.
15. Zabal C, Attie F, Rosas M (2003) The adult patient with native coarctation of the aorta balloon angioplasty or primary stenting. *Heart* 89: 77-83.
16. Chessa M, Carrozza M, Butera G (2005) Results and mid-long-term follow-up of stent implantation for native and recurrent coarctation of the aorta. *Eur Heart J* 26: 2728-2732.
17. Mendelsohn AM, Lloyd TR, Crowley DC (1994) Late follow-up of balloon angioplasty in children with a native coarctation of the aorta. *Am J Cardiol* 74: 696-700.
18. Fawzy ME, Sivanandam V, Galal O (1997) One to ten-year follow-up results of balloon angioplasty of native coarctation of the aorta in adolescents and adults. *J Am Coll Cardiol* 30: 1542-6.
19. Walhout RJ, Lekkerker JE, Ernst SP (2002) Angioplasty for coarctation in different aged patients. *Am Heart J* 144: 180-6.
20. Fletcher SE, Nihill MR, Grifka RG (1995) Balloon angioplasty of native coarctation of the aorta: midterm follow-up and prognostic factors. *J Am Coll Cardiol* 25: 730-734.
21. Giovanni JV, Lip GYH, Osman K (1996) Percutaneous balloon dilatation of aortic coarctation in adults. *Am J Cardiol* 77: 455-459.