

# Impact on PET Texture Features of Imaging Biomarkers for Predicting Survival of Patients with Uterine Sarcoma-Preliminary Results

Makoto Yamamoto<sup>1</sup>, Tetsuya Tsujikawa<sup>2</sup>, Hidehiko Okazawa<sup>2</sup> and Yoshio Yoshida<sup>1</sup>

<sup>1</sup>Department of Obstetrics and Gynecology, University of Fukui, 23-3 Matsuoka-shimoaijuki, Eiheiji-cho, Yoshida-gun, Fukui 910-1193, Japan

<sup>2</sup>Biomedical Imaging Research Center, Faculty of Medical Sciences, University of Fukui, Fukui, Japan

**Corresponding author:** Yoshio Yoshida, Department of Obstetrics and Gynecology, University of Fukui, 23-3 Matsuoka-shimoaijuki, , Eiheiji-cho, Yoshida-gun, Fukui 910-1193, Japan, Email: yyoshida@u-fukui.ac.jp; y2432yoshida@gmail.com

**Received date:** March 10, 2016; **Accepted date:** March 20, 2016; **Published date:** March 27, 2016

**Citation:** Yamamoto M, Tsujikawa T, Okazawa H, et al. Impact on PET Texture Features of Imaging Biomarkers for Predicting Survival of Patients with Uterine Sarcoma-Preliminary Results. *Biomark J.* 2016, 2:1

## Purpose

Uterine sarcoma is a relatively rare malignancy that accounts for approximately 3% - 7% of malignant uterine tumors [1], and that is associated with a poor prognosis. There have been many attempts to identify predictors of outcomes for patients with uterine sarcoma. However, the rarity of uterine sarcoma makes it challenging to study. It is essential to establish for new prognostic tool for effective treatment development. In the case of uterine sarcomas, the level of tumor 18F - fluorodeoxyglucose (FDG) uptake is reflective of tumor grade or aggressiveness determined by standard histopathology. However, there is more information in the spatial and quantitative data generated in the standard clinical FDG - Positron emission tomography (PET) image. We hypothesized that heterogeneity in tumor metabolism recorded by new image-analysis statistical tool, texture analysis, designed to report tumor heterogeneity in FDG uptake is reflective of tumor biologic heterogeneity and could be used as a biomarker to predict patient outcome.

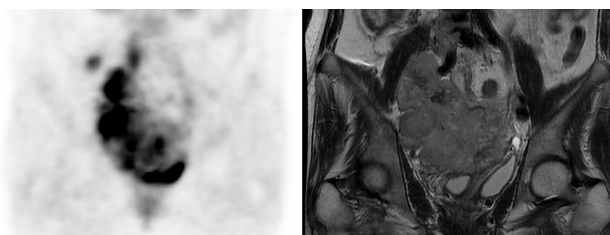
## Method

We compared with FDG - PET images from 2 patients with uterine leiomyosarcoma and progression-free survival (PFS) retrospectively. We used Radiomics analysis indicating new heterogeneity - analysis algorithm applied to FDG PET images of tumors, which aims to understand the complex biological phenomena transitioning between cells or time [2]. Texture analysis, one of the Radiomics analyses, is an analysis method which quantifies the information of general texture features such as coarseness or smoothness. Contrast, one of second-order texture feature, was computed in addition to first-order texture features indicating metabolic tumor burden in terms of total lesion glycolysis (TLG) and the maximum standardized uptake value (SUVmax). These indicators were analyzed with clinical stage, tumor diameter and lactate dehydrogenase (LDH), and compared for their performance in predicting PFS.

## Results

### Case 1

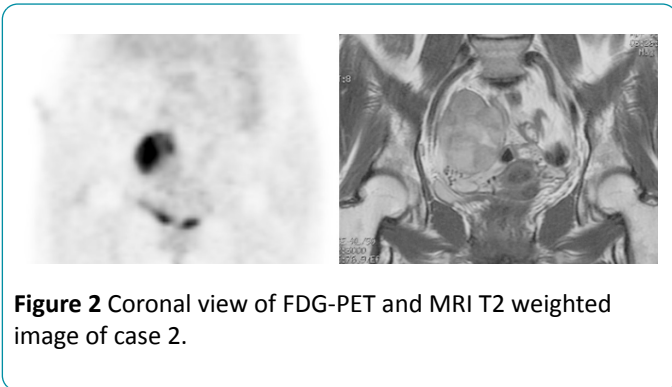
A 43 year old woman diagnosed with uterine leiomyosarcoma in 2010. Although, cytoreductive surgery and concurrent radiochemotherapy were performed, the tumor regressed 15 months later and she died 20 months later. In the FDG PET / CT (Figure 1) before the initiation of treatment, TLG was 2127 and SUVmax was 15.83. The contrast was 150572.



**Figure 1** Coronal view of FDG-PET and MRI T2 weighted image of case 1.

### Case 2

A 51 year old woman diagnosed with uterine leiomyosarcoma in 2007. Hysterectomy and bilateral salpingo - oophorectomy and adjuvant chemotherapy was performed. There was no recurrence more than 5 years later. In the FDG PET / CT (Figure 2) before the initiation of treatment, TLG was 352.64 and SUVmax was 7.53. The contrast was 19152. The levels of TLG and SUVmax in both patients were high. Only the contrast analysis was quite difference between the two patients.



## Conclusion

The new image - analysis statistical tool, texture analysis, may be validated for ability to predict outcome in a clinical

population of patients with sarcoma. This method could be used as a biomarker for the ability to predict the outcome.

## Reference

1. Gadducci A (2011) Prognostic factors in uterine sarcoma. *Best Pract Res Clin Obstet Gynaecol* 25: 783-795.
2. Yan J, Chu - Shern JL, Loi HY, Khor LK, Sinha AK, et al. (2015) Impact of image reconstruction settings on texture features in 18F - FDG PET. *J Nucl Med* 56: 1667-1673.