

## CASE REPORT

---

# Epigastric Mass Due to a Hydatid Cyst of the Pancreas. A Case Report and Review of the Literature

Seyed Reza Moosavi, Houman Khajouei Kermany

Department of General and Vascular Surgery, Shohada-e Tajrish Medical Center,  
Shahid Beheshti University of Medical Sciences. Tehran, Iran

### ABSTRACT

**Context** Primary hydatid disease of the pancreas is very rare.

**Case report** We report the case of a 30-year-old man who presented with abdominal pain and an epigastric mass. A diagnosis of a pancreatic cyst was established by ultrasonography and CT scan before surgery. The treatment consisted of the resection of the protruding dome with a cystogastrostomy. The recovery was uneventful and the patient has remained symptom free so far.

**Conclusions** Hydatid disease should be considered in the differential diagnosis of all cystic masses in the pancreas, especially in the geographical regions where the disease is endemic.

---

### INTRODUCTION

Pancreatic location of hydatid disease is extraordinarily rare, with an incidence of less than 1% as compared to the other sites of hydatid disease [1, 2]. Establishing a precise diagnosis may be difficult because the presenting symptoms and the findings of clinical investigations may be similar to other more commonly encountered cystic lesions of the pancreas [3]. Clinical presentation varies

according to the anatomic location of the cyst. Abdominal pain, discomfort and vomiting are the main clinical symptoms. The patient may present with obstructive jaundice, weight loss, an epigastric mass, and/or recurrent acute pancreatitis [4, 5]. The diagnosis is based on an enzyme-linked immunoadsorbent assay (ELISA) test for echinococcal antigens, which is positive in over 85% of infected patients [6]. Ultrasonography will typically demonstrate a cyst with a wall of varying thickness. Computed tomographic findings, such as rounded cystic lesions with curvilinear calcification may allow the diagnosis to be made in the appropriate clinical setting [7]. A definitive diagnosis of hydatid disease of the pancreas can be made only at surgery and, during surgical treatment of hydatid cysts, extreme caution must be taken to avoid rupture of the cysts which would release protoscolices into the peritoneal cavity. Multiple surgical procedures, such as proper evacuation, pericystectomy and omentoplasty, are possible. A hydatid cyst in the tail of the pancreas can be successfully treated with a distal pancreatectomy [8, 9].

In this article, we present the case of a patient with an isolated hydatid cyst of the pancreas.

### CASE REPORT

The patient was a 30-year-old man who presented in January 2006 to our hospital with epigastric pain, occasional vomiting, and an

epigastric mass of 3 month duration. On physical examination, the vital signs were normal. The only positive sign besides a hard epigastric mass was mild tenderness. Ultrasonography and CT scan showed a cyst at the head of the pancreas, 6x8 cm in diameter (Figure 1). The hydatid cyst was recognized before surgery on the basis of the epidemiological data and the existence of a calcified shell. The indirect hemagglutination test was positive. The patient underwent midline transperitoneal laparotomy and an isolated hydatid cyst of the pancreas was found without communication to the pancreatic duct. The content of the cyst was removed without any spillage and a cystogastrostomy was performed. The patient was started on 800 mg/day albendazole after surgery. Recovery was uneventful and the patient has remained symptom free so far.

## DISCUSSION

We emphasize the low incidence of hydatid disease in a pancreatic site (0.2-2% in the literature) [1, 2, 10]. The most common differential diagnosis between a hydatid cyst and pancreatic cystic tumors is the presence of a serous cyst adenoma. Though very rare, pancreatic hydatidosis should be considered in the differential diagnosis of cystic lesions of the pancreas in the appropriate epidemiological setting. In the literature, the surgical treatment of pancreatic hydatid disease is complete excision of the cyst, but this has the potential risk of spillage or of damaging the pancreatic tissue, however, it seems that when we have a large cyst with extensive adherence to the surrounding pancreatic parenchyma, a cystogastrostomy may be a satisfactory treatment. When there is a lack of surgical radicality, we should consider adjuvant medical therapy with benzoimidazoles (e.g, albendazole).

Received January 8<sup>th</sup>, 2007 - Accepted February 1<sup>st</sup>, 2007

**Keywords** Echinococcosis; Surgical Procedures, Operative; Pancreatic Cyst

## Correspondence

Seyed Reza Moosavi  
Shahid Beheshti University of Medical Sciences  
Shohada-Tajrish, Medical Center  
Tehran  
Iran  
Phone: +98-21.227.8001-12  
Fax: +98-21.227.2144; +98-21.228.62756  
E-mail: seyed29@yahoo.com

Document URL: <http://www.joplink.net/prev/200703/15.html>

## References

1. Rodriguez Vargas J, Arroyo Carrera I, Pitarch Esteve V. Pancreatic hydatid cysts. *Cir Pediatr* 1992; 5:46-7. [PMID 1567748]
2. Khiari A, Mzali R, Ouali M, Kharrat M, Kechaou MS, Beyrouti MI. Hydatid cyst of the pancreas. Apropos of 7 cases. *Ann Gastroenterol Hepatol (Paris)* 1994; 30:87-91. [PMID 8067682]
3. Krige JE, Mirza K, Bornman PC, Beningfield SJ.

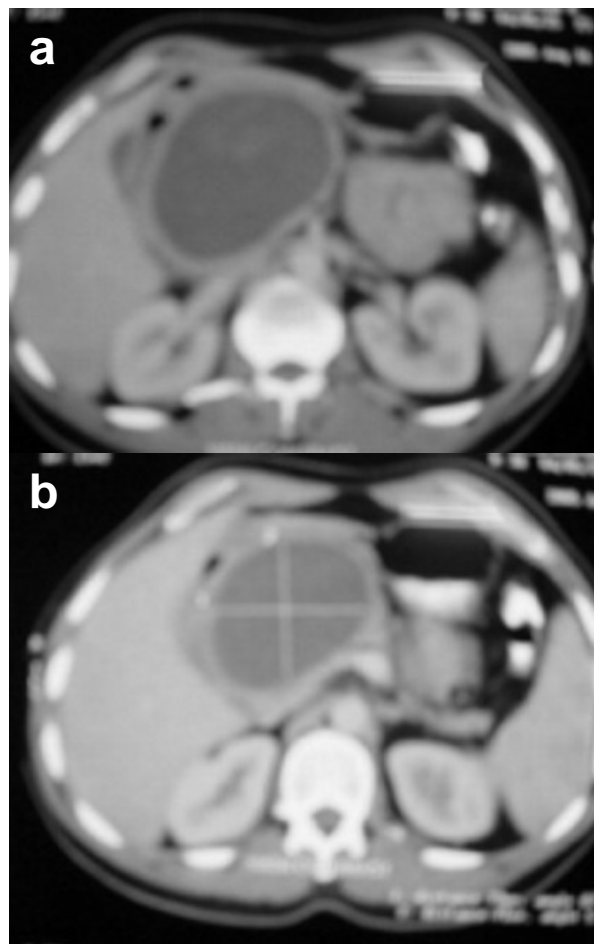


Figure 1. CT scan of the pancreatic mass.

Primary hydatid cysts of the pancreas. *S Afr J Surg* 2005; 43:37-40. [PMID 16035381]

4. Safioleas MC, Moulakakis KG, Manti C, Kostakis A. Clinical considerations of primary hydatid disease of the pancreas. *Pancreatology* 2005; 5:457-61. [PMID 15985772]

5. Ozmen MM, Moran M, Karakahya M, Coskun F. Recurrent acute pancreatitis due to a hydatid cyst of the pancreatic head: a case report and review of the literature. *JOP. J Pancreas (Online)* 2005; 6:354-8. [PMID 16006687]

6. Sayek I, Onat D. Diagnosis and treatment of uncomplicated hydatid cyst of the liver. *World J Surg* 2001; 25:21-7. [PMID 11213152]

7. Missas S, Gouliamos A, Kourias E, Kalovidouris A. Primary hydatid disease of the pancreas. *Gastrointest Radiol* 1987; 12:37-8. [PMID 3792756]

8. Ugras S, Sakarya ME, Arslan H, Bozkurt M, Akdeniz H. The diagnosis by fine needle aspiration biopsy of hydatid cyst of the pancreas. *Acta Chir Belg* 1997; 97:244-6. [PMID 9394966]

9. Erkan N, Hacıyanlı M, Yildirim M, Yılmaz C. A case report of the unusual presence of hydatid disease in the pancreas and breast. *JOP. J Pancreas (Online)* 2004; 5:368-72. [PMID 15365205]

10. D'Alia C, Lo Schiavo MG, Tonante A, Gagliano E, Taranto F, Bonanno L, Sturniolo G. Pancreatic echinococcosis. Report of a clinical case and review of the literature. *Chir Ital* 2003; 55:581-4. [PMID 12938607]