

## Endoscopic “String Sign”

Jesus Espinel<sup>1</sup>, Eugenia Pinedo<sup>2</sup>, Gabriela Rascarachi<sup>3</sup>, Vanesa Ojeda<sup>4</sup>

<sup>1</sup>Endoscopy Unit and <sup>2</sup>Department of Radiology, Hospital de León. León, Spain.

<sup>3</sup>Endoscopy Unit, Hospital del Bierzo. Ponferrada, Spain.

<sup>4</sup>Department of Digestive Diseases, Dr. Negrín University Hospital. Las Palmas de Gran Canaria, Spain

A 76-year-old female patient was admitted at hospital with diarrhea, weight loss, fatigue and abdominal pain. Her physical examination and laboratory test were normal; however, the radiological images showed an atrophic pancreas with cystic dilatation of the main pancreatic duct. Severe dilatation of the main pancreatic duct was confirmed on EUS, with the presence of round images of mucinous aggregates within (droplets of

mucous plug). In view of these findings, we performed a duodenoscopy, which showed mucin extrusion from a patent ampulla (a “fish-mouth” look-like patulous papilla with mucus excretion from the orifice; Image 1), a pathognomonic finding of intraductal papillary mucinous tumor (IPMT) of the main pancreatic duct. We obtained blind biopsies and the histological results confirmed the diagnosis of IPMT. After removing the duodenoscope, a mucus string of about 40 cm in length was adhered to the biopsy channel of the duodenoscope (Image 2).

Received September 11<sup>th</sup>, 2013 – Accepted December 11<sup>th</sup>, 2013

**Key words** Cystadenoma, Mucinous; Pancreatectomy; Pancreatic Cyst; Viscosity

**Correspondence** Jesus Espinel  
c/ Santos Olivera n°30, 4°-B; 24.005-León; Spain  
Phone: +34-987.237.400; Fax: +34-987.235.318  
E-mail: espinel.jesus@gmail.com

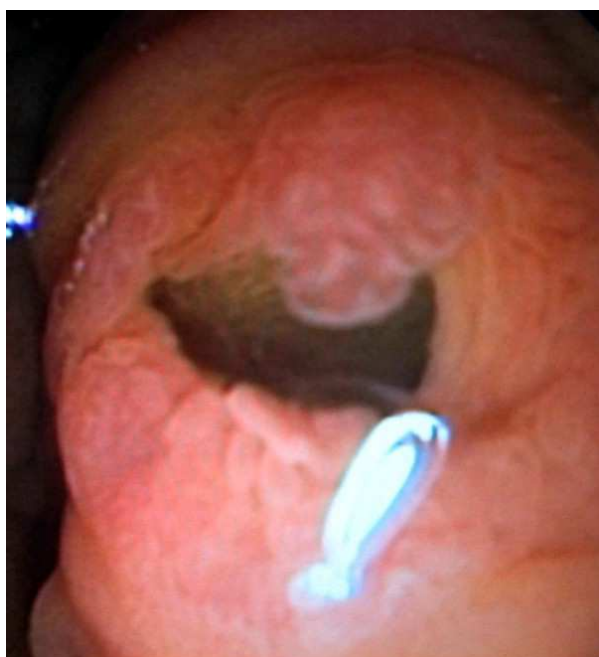


Image 1

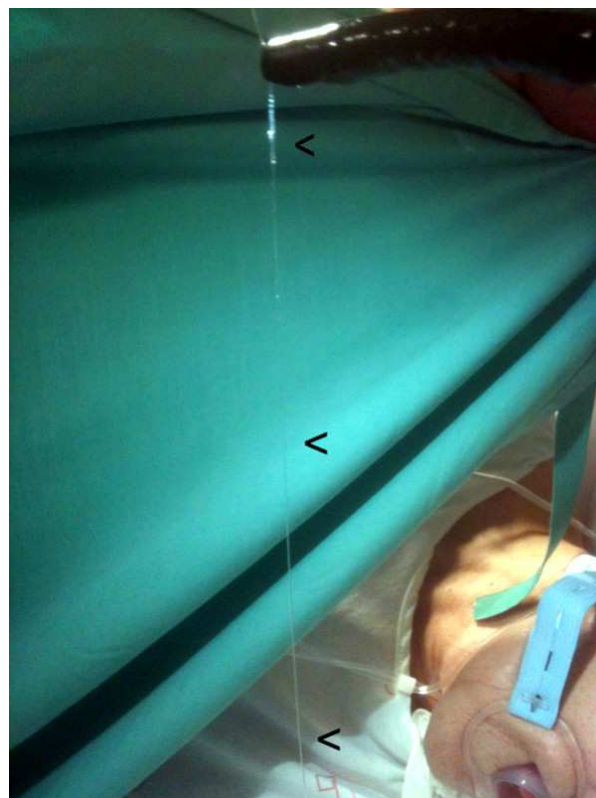

Image 2

Viscosity is one of the main features which might help on the diagnosis of a pancreatic cystic lesion. It is useful to distinguish mucinous from non-mucinous cystic lesions. Cystic fluid from serous cystadenomas and pseudocysts had mean relative viscosity values of 1.24 and 1.25 respectively. By contrast, mean relative viscosity values of mucinous cysts were significantly higher, ranging from 1.2 to 30 [1]. A recent study concluded that viscosity greater than 1.6 predicted mucinous cystic adenoma/adenocarcinoma [2]. A novel surrogate marker of cyst viscosity was used by Leung *et al.*, and it was described as the “string sign” [3]. This test was determined by placing a drop of fluid between the thumb and index finger and measuring the maximum length of stretch before disruption of the mucous string. The authors concluded that a long string sign (greater than 3.5 mm) has a high predictive value for a mucinous lesion. The string sign is a simple technique which could help to supplement the diagnosis of cystic lesions.

In our case, we obtained a very long string sign (about 40 cm in length) with the help of the duodenoscope (“endoscopic string sign”).

---

**Conflict of interest** The authors have no potential conflicts of interest.

---

#### References

1. Lewandrowski KB, Southern JF, Pins MR, Compton CC, Warsaw AL. Cyst fluid analysis in the differential diagnosis of pancreatic cysts. A comparison of pseudocysts, serous cystadenomas, mucinous cystic neoplasms, and mucinous cystadenocarcinoma. *Ann Surg.* 1993; 217(1):41-7. [PMID: 8424699]
2. Linder JD, Geenen JE, Catalano MF. Cyst fluid analysis obtained by EUS-guided FNA in the evaluation of discrete cystic neoplasms of the pancreas: a prospective single-center experience. *Gastrointest Endosc.* 2006; 64(5):697-702. [PMID: 17055859]
3. Leung KK, Ross WA, Evans D, Fleming J, Lin E, Tamm EP, et al. Pancreatic cystic neoplasm: the role of cyst morphology, cyst fluid analysis, and expectant management. *Ann Surg Oncol.* 2009; 16 (10):2818-24. [PMID: 19536601]