

Endoscopic Fenestration of a Duodenal Duplication Cyst to Resolve Recurrent Pancreatitis

Marie-Antoinette J Rockx¹, Vivian C McAlister²

Departments of ¹Medicine and ²Surgery, London Health Sciences Centre. London, Canada

Summary

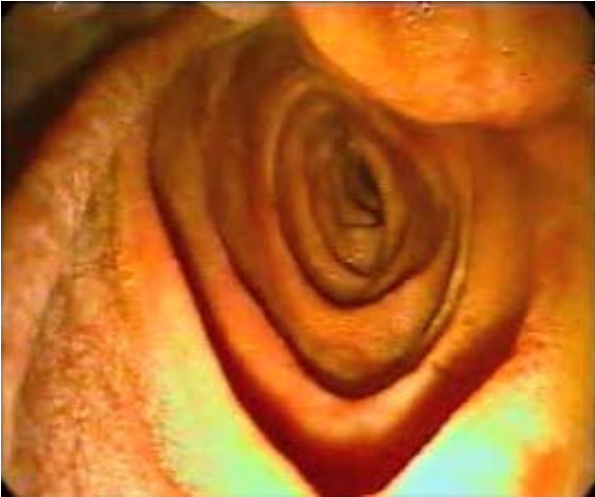Non-invasive tools such as endoscopic ultrasound and magnetic resonance cholangiopancreatography have assisted the diagnosis of unexplained or recurrent acute pancreatitis prior to endoscopic retrograde cholangiopancreatography (ERCP). The majority of these patients are improved by endoscopic therapy with ERCP. Duodenal duplication cyst is a known but rare cause of recurrent acute pancreatitis that is also amenable to ERCP. We document the diagnosis and treatment of a 26-year-old man who had six episodes of pancreatitis that were found to be due to a duodenal duplication cyst. The pancreatico-biliary tree emptied into the cyst, which caused episodic obstruction and reflux contaminated juice resulting in pancreatitis. The patient also complained of persistent epigastric discomfort between attacks. Video demonstration of the technique for fenestration of the cyst is presented. Free emptying of bile and pancreatic juice from the cyst has resulted in elimination of the patient's persistent epigastric discomfort and attacks of pancreatitis.

In approximately 20% of patients with pancreatitis, the cause and most appropriate treatment are not established by conventional clinical, laboratory or radiological techniques. Even though up to 75% of patients with unexplained pancreatitis have either micro-lithiasis or ampullary dysfunction, endoscopic

ultrasound is preferred over endoscopic retrograde cholangiopancreatography (ERCP) in order to avoid unnecessary risk of complications [1]. Cotton *et al.* used a combination of endoscopic ultrasound, manometry and ERCP to evaluate 162 patients with pancreatitis, of whom 90 had unexplained or recurrent pancreatitis [2]. Findings were categorized into five distinct etiologies: ampullary dysfunction (n=28; 31%), pancreas divisum (n=18; 20%), biliary (n=18; 20%), idiopathic (n=18; 20%) and tumor-related (n=8; 9%). The majority (96%) of the patients recovered after treatment at ERCP. Duodenal duplication cyst is a known but rare cause of pancreatitis. It was not reported in their series but it may be amenable to endoscopic ultrasound and ERCP [3].

Case report

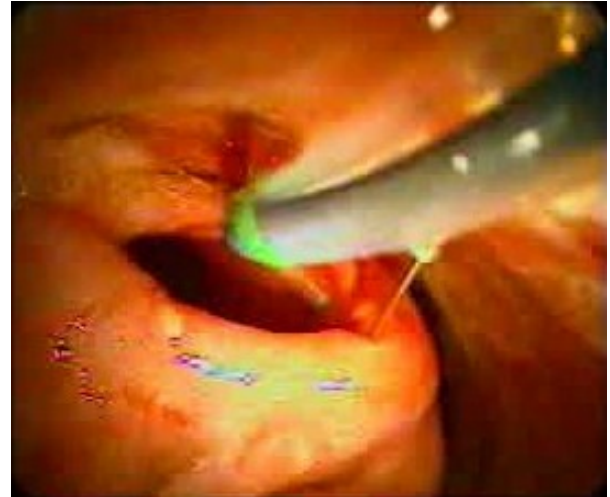A 26-year-old male was admitted to hospital with his sixth episode of acute pancreatitis. The young man drank no alcohol. His triglycerides were normal on several measurements. No gallstones had been seen on previous imaging (extracorporeal ultrasound, computerized tomography) but a prophylactic laparoscopic cholecystectomy had been performed after the third episode of pancreatitis. He had no history of exotic travel. There was no family history of pancreatic problems. He took no medications on a regular basis. He complained of a persistent abdominal discomfort between episodes of pancreatitis. This episode settled



Videoclip 1.

with three days of supportive care. Imaging done prior to this admission included a magnetic resonance cholangiopancreatogram (MRCP) which demonstrated a normal biliary tree. Prior to accepting a referral for ERCP, the MRCP was reviewed. There was no filling defect in the common bile duct but an unusual cystic filling defect protruded into the lumen of the second part of the duodenum, which was consistent with a duplication cyst. The diagnosis was confirmed with an endoscopic ultrasound.

At ERCP, a large protrusion into the second part of the duodenum was seen at the site of the longitudinal fold (Videoclip 1). Contrast was injected through a pinhole, which was found at the normal position for the ampulla, to fill an extraluminal cyst. The sphincterotome was placed into the cyst and the opening



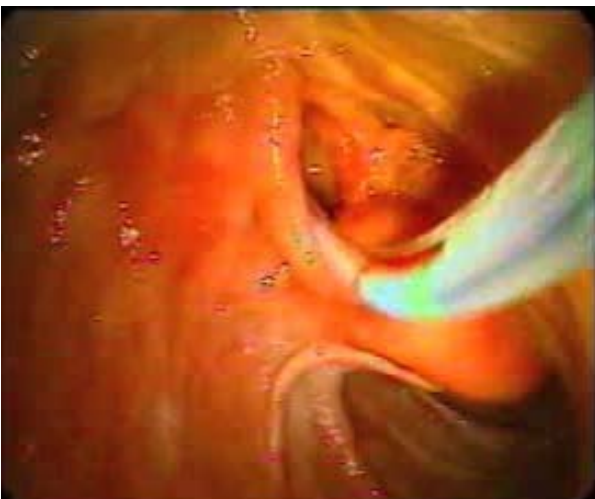Videoclip 3.

was widened into the duodenum, releasing a burst of cloudy bile colored fluid. Once opened, the inside of the cyst was found to be lined with mucosa which was inspected to exclude the presence of ectopic or neoplastic tissue (Videoclip 2). Fenestration of the cyst was completed by cruciate extensions of the initial incision (Videoclips 3 and 4).

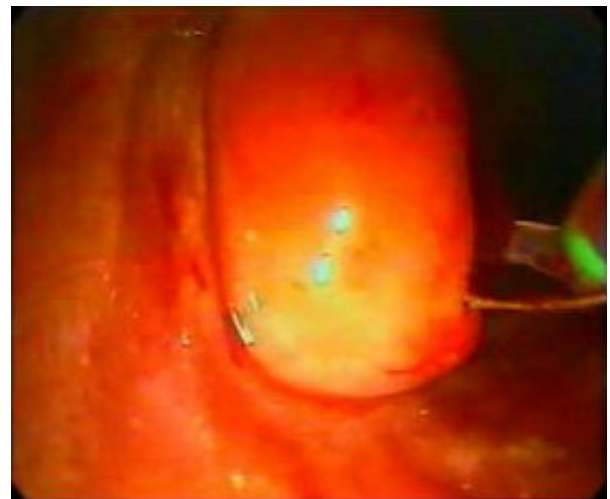
The patient recovered quickly and he remains well one year later without recurrence of pancreatitis. The persistent low-grade abdominal pain that had always been in the background before the fenestration, disappeared after the procedure.

Discussion

A duplication cyst is a benign congenital anomaly acquired during the digestive system's embryonic development [4]. It is a



Videoclip 2.



Videoclip 4.

tubular structure with an internal lining of gastrointestinal epithelium, smooth muscle in its wall and adherence to some portion of the alimentary tract [5]. The gastric epithelial lining contains both parietal and chief cells [6]. The most common sites for duplication cysts are the distal ileum, posterior mediastinum, and duodenum [7].

One theory states that a duplication cyst involving the pancreas most likely results from the failure to regress of an enteric diverticulum formed from the pancreatic duct [7]. Duplication cysts are rare anomalies that result from abnormal foregut development. The primitive gut starts to develop in the third to fourth weeks of life. The esophagus, stomach, duodenum, pancreas, liver, and biliary system all arise from the foregut [8]. There are two widely held theories of the development of a gastric duplication cyst. Bremer's theory of errors on recanalisation is based on the observation that in the fifth to sixth weeks of life there is rapid epithelial proliferation of the gut, resulting in obliteration of the lumen [8, 9]. McLetchie's theory of a neurenteric band is based on the observation that during the third week of life, the primitive gut is developing and anomalies may occur in the separation of the notochord, resulting in a diverticulum of the foregut [8, 10]. While usually diagnosed in infancy, it has been described in young adults [4, 8, 11]. There are several possible mechanisms for pancreatitis from a duplication cyst. A transitory and mobility-related duodenal obstruction of the major papilla outflow by the cyst may occur [4]. There may be migration of biliary sludge and/or microstones from the cyst to the biliary tree [4]. The cyst may produce viscid mucous secretions which obstruct the pancreatic duct [5]. The cyst may be sufficiently large to compress the pancreatic duct or hepatobiliary tree [8]. Recurrent pancreatitis may result from obstruction of the communicating pancreatic duct by shed cyst blood or mucoid material originating from within the cyst cavity [8]. We do not think that these postulated mechanisms explain the finding in the patient described above. His pancreatic and biliary

ducts emptied into the duplication cyst, which itself only had a pinhole sized exit. Because the patient was not jaundiced, bile emptying from the cyst into the duodenum was sufficient and the ampulla prevented transmission of pressure from the filled cyst into the biliary tree. Small volume reflux of duodenal juice into the ampulla may, however, have provoked episodes of acute pancreatitis. Free drainage of cyst contents eliminates this problem and resolves not only recurrent acute pancreatitis but also the persistent low-grade pain of which the patient complained.

Cyst excision with [7] or without Roux-en-Y pancreaticojejunostomy [12] or Roux-en-Y cystojejunostomy [8] are commonly cited surgical options. The role of endoscopy was first described in 1984 when it was used to diagnose the cause of duodenal obstruction in a patient who was treated by transduodenal excision of a duplication cyst [12]. In 1987, the polypectomy snare technique was used to partially excise a duodenal duplication cyst [3]. Use of the endoscopic needle knife and sphincterotome to open the cyst into the duodenum is the currently favored endoscopic method [13]. Illustrations provided by Roy *et al.* are similar to those in our presentation which adds to the literature only by providing moving images in an open-access web-based journal [13]. These images clearly illustrate the mechanisms by which a duodenal duplication cyst causes recurrent acute pancreatitis and cyst fenestration relieves it.

Received June 13th, 2007 - Accepted October 19th, 2007

Keywords Cholangiopancreatography, Endoscopic Retrograde; Cysts; Pancreatitis; Pathological Conditions, Anatomical; Videotape Recording

Conflict of interest The authors have no potential conflicts of interest

Correspondence

Marie-Antoinette J Rockx
Division of Nephrology
Health Sciences Centre

820 Sherbrook St.
Winnipeg, MB
Canada R3A 1R9
Phone: +1-204.787.3266
Fax: +1-204.787.3326
E-mail: mrockx@exchange.hsc.mb.ca;
vivian.mcalister@lhsc.on.ca

Document URL: <http://www.joplink.net/prev/200711/13.html>

References

1. Wilcox CM, Varadarajulu S, Eloubeidi M. Role of endoscopic evaluation in idiopathic pancreatitis: a systematic review. *Gastrointest Endosc* 2006; 63:1037-45. [PMID 16733122]
 2. Coyle WJ, Pineau BC, Tarnasky PR, Knapple WL, Aabakken L, Hoffman BJ, et al. Evaluation of unexplained acute and acute recurrent pancreatitis using endoscopic retrograde cholangiopancreatography, sphincter of Oddi manometry and endoscopic ultrasound. *Endoscopy* 2002; 34:617-23. [PMID 12173081]
 3. Stelling T, von Rooij WJ, Tio TL, Reeders JW, Bartelsman JJ, Tytgat GN. Pancreatitis associated with congenital duodenal duplication cyst in an adult. *Endoscopy* 1987; 19:171-3. [PMID 3304989]
 4. Guarise A, Faccioli N, Ferrari M, Romano L, Parisi A, Falconi M. Duodenal duplication cyst causing severe pancreatitis: imaging findings and pathological correlation. *World J Gastroenterol* 2006; 12:1630-3. [PMID 16570360]
 5. Gandhi MR, Sprigg A, Walker J. Case report: recurrent pancreatitis caused by a duodenal duplication cyst communicating with the pancreatic duct. *Clin Radiol* 1995; 50:726-8. [PMID 7586969]
 6. Webster J, Terry S, Humphrey D, Khan S. Anorexia and pancreatitis associated with a gastric duplication cyst of the pancreas. *Surgery* 2001; 129:375-6. [PMID 11231468]
 7. Del Rosario JF, Silverman WB, Ford H, Adkins J, Wiener E. Duplication cyst of the pancreatic duct presenting as pancreatitis. *Gastrointest Endosc* 1998; 47:303-5. [PMID 9540888]
 8. Whiddon DR, Olutoye OO, Broderick TJ, Mills AS, Turner MA, Zfass AM, Sugerman HJ. Recurrent acute pancreatitis caused by a gastric duplication communicating with an aberrant pancreas. *Am Surg* 1999; 65:121-4. [PMID 9926743]
 9. Bremer JL. *Congenital Anomalies of the Viscera*. Cambridge, MA, USA: Harvard University Press, 1957.
 10. McLetchie NGB, Purves JK, Saunders RLCH. The genesis of gastric and certain intestinal diverticula and enterogenous cyst. *Surg Gynecol Obstet* 1954; 99:135-41.
 11. Etienne S, Pilette C, Prophette B, Serra-Maudet V. Duplications gastriques de l'adulte: à propos d'un cas révélé par des poussées itératives de pancréatite aiguë œdémateuse. [Gastric duplication in the adult: a case report presenting as recurring acute edematous pancreatitis]. *Ann Chir* 2002; 127:641-4. [PMID 12491642]
 12. Dave P, Romeu J, Clary S, Rybak B, Messer J. Endoscopic removal of an obstructing duodenal duplication cyst. *Endoscopy* 1984; 16:75-6. [PMID 6714179]
 13. Vandenbroucke F, Dagenais M, Letourneau R, Lapointe R, Roy A. Endoscopic treatment of a duodenal duplication cyst. *Endoscopy* 2005; 37:601. [PMID 15933941]
-