

CASE REPORT

Effectiveness of Elective Surgery in Patients with Chronic Pancreatitis

Kyohei Abe¹, Tomoyoshi Okamoto¹, Michinori Matsumoto¹, Yasuro Futagawa¹, Katsuhiko Yanaga²

¹Department of Surgery, The Jikei University Daisan Hospital, Tokyo, Japan

²Department of Surgery, The Jikei University School of Medicine, Tokyo, Japan

ABSTRACT

Background Medications and/or endoscopic therapy constitute first-line treatment for chronic pancreatitis; however, some patients remain refractory to conservative treatment. There are reports of surgical treatment for patients with chronic pancreatitis and their effectiveness, but few studies have investigated postoperative prognosis. **Methods** We investigated 15 patients (12 with chronic pancreatitis and 3 with (preoperatively diagnosed pancreatic tumor) between 2003 and 2019. Patients were aged 40–80 years (median 56 years, male: female ratio 12:3). Notably, 2, 10, and 3 patients underwent pancreaticoduodenectomy, distal pancreatectomy, and pancreaticojejunostomy, respectively. We evaluated preoperative diagnoses, operative procedures, short-term complications, surgical outcomes, long-term disease course, and prognosis based on medical findings. **Results** No operative mortality occurred however, 5 patients developed postoperative complications (pancreatic leakage and pseudocyst and pneumonia). Three people diagnosed with pancreatic cancer before surgery had no symptoms of pancreatitis, but postoperative histopathological examination revealed that these patients had tumor-forming pancreatitis. No postoperative recurrence occurred in any of the 12 patients with recurrent chronic pancreatitis. Chronic pancreatitis was attributed to preoperative alcohol consumption in 9 patients; 5 of them resumed alcohol consumption postoperatively. Notably, 3 patients developed hepatic cirrhosis and esophageal varices and died of hepatic failure (1 patient), pancreatic cancer (2 patients). Prognosis was good in patients without pre- or postoperative alcohol consumption. **Conclusion** Surgical treatment successfully controlled abdominal pain in patients with recurrent pancreatitis. Pre- and postoperative alcohol abstinence and close follow-up for cancer should be emphasized to reduce the risk of postoperative liver disease and pancreatic cancer.

INTRODUCTION

Chronic pancreatitis usually causes intractable symptoms secondary to progressive and irreversible changes in the pancreas. Progressive chronic pancreatitis results in a gradual decline in the endocrine and exocrine functions of the pancreas with disturbances in digestion and absorption or pancreatic diabetes [1]. Chronic pancreatitis is characterized by recurrent analgesic-resistant abdominal and back pain with disease progression, which significantly impairs patients' social and family activities. Treatment for chronic pancreatitis is primarily aimed at maintaining patients' quality of life (QOL) by alleviating intractable pain and preventing progression of pancreatic dysfunction. Surgical intervention is considered in patients who are refractory

to conservative therapies [1, 2, 3]. Operative procedures for chronic pancreatitis include neurotomy, pancreatic duct drainage, and pancreatectomy. It is important to evaluate the outcomes of these interventions, including the long-term QOL and prognosis. We investigated patients with chronic pancreatitis who underwent surgery at our hospital. Based on our findings, we report the effectiveness of surgery and postoperative management in these patients.

MATERIALS AND METHODS

Patients

This study included 15 patients with final histopathological diagnosis of chronic pancreatitis (including autoimmune pancreatitis [AIP]) treated at the Jikei University Daisan Hospital between 2003 and 2019. Patients ages ranged between 40 and 80 years (median 56 years), and the male: female ratio was 12:3. We evaluated preoperative diagnoses, operative procedures, short-term complications, surgical outcomes, long-term disease course, and prognosis. This study was approved by the Human Ethics Review Committee of the Jikei University Daisan Hospital (Institutional Committee number 27-177(8062)) and conforms to the provisions of the Declaration of Helsinki. Informed consent was obtained from all subjects.

Received October 10th, 2020 - Accepted November 25th, 2020

Keywords Alcohol Abstinence; Chronic Pancreatitis; Conservative Therapy; Preoperative; Postoperative; Quality of Life

Abbreviations CT computed tomography; PD pancreaticoduodenectomy; PV portal vein; SMPV superior mesenteric and portal vein; SPV splenic vein

Correspondence Kyohei Abe

The Jikei University Daisan Hospital 4-11-1, Izumihoncho, Komae-shi, Tokyo 201-8601, Japan

Tel +81-33-480-1151

Fax +81-33-480-1151

E-mail kyoheiabe@jikei.ac.jp

Operative Procedure

Pancreaticoduodenectomy (PD) was performed on patients with lesions mainly in the pancreatic head region. The procedures involved PD or subtotal stomach-preserving pancreaticoduodenectomy without lymph node dissection, and all patients underwent Child-II reconstruction (Braun anastomosis added). Distal pancreatectomy (DP) was performed for tumor lesions mainly in the pancreatic body and tail. The operative procedure involved DP without lymph node dissection. Pancreaticojejunostomy (PJ) was selected for patients with diffuse chronic pancreatitis accompanied by pancreatic stones or a dilated main pancreatic duct. The main pancreatic duct was exposed by separating the pancreatic parenchyma along the duct, pancreatic stones were removed, and the duct was anastomosed with an elevated jejunum.

RESULTS

Among the 15 patients who underwent surgery, 12 patients were preoperatively diagnosed with chronic pancreatitis and 3 with pancreatic tumor (malignancy could not be excluded in these 3 patients). All 15 patients were diagnosed with diabetes preoperatively. Three patients diagnosed with pancreatic cancer before surgery had no symptoms of pancreatitis, but postoperative pathological examination revealed that they had tumor-forming pancreatitis. Persistent pain or recurrent pancreatitis

was considered an indication for surgical treatment of chronic pancreatitis. We performed PD in 2, DP in 10, and PJ in 3 patients (Table 1). The average operative time for DP, PD, and PJ was 233, 346, and 236 minutes, and the average intraoperative blood loss was 548, 287, and 270 g, respectively. No perioperative mortality was observed; however, postoperative complications occurred in 5 patients (pancreatic leak, Grade-B, in 2, pneumonia in 1, and pancreatic pseudocyst in 2 patients). All 15 patients were diagnosed with diabetes preoperatively, who were postoperatively administered digestive pancreatic enzymes orally. Patients in whom surgery was associated with worsening of diabetes required postoperative insulin administration to control their blood glucose levels. Blood glucose levels were well controlled postoperatively, and no patient reported difficulty with blood glucose control. DP or PJ led to resolution of recurrent abdominal pain and pancreatitis in 12 patients. Among 9 patients in whom chronic pancreatitis (12 patients) was attributed to preoperative alcohol consumption, 5 resumed alcohol consumption postoperatively. Of these 5 patients, 3 developed hepatic cirrhosis and esophageal varices and died of hepatic failure (1 patient) or pancreatic cancer (2 patients) (Fig 1). Two of 3 patients with tumor-forming pancreatitis were diagnosed with AIP (Fig 1) and received steroids postoperatively. During a mean follow-up of 1–14 years (median 6 years), these patients developed residual pancreatic cancer, 3 and 5 years postoperatively; 1 patient each developed gastric and colorectal cancer.

Table 1. Operative procedure.

| | Preoperative diagnosis | | |
|-------------------------|------------------------|--------------------------|-----------------------|
| | total, N= | chronic pancreatitis, N= | pancreatic cancer, N= |
| Pancreaticoduodenectomy | 2 | 0 | 2 |
| Distal pancreatectomy | 10 | 9 | 1 |
| Pancreaticojejunostomy+ | 3 | 3 | 0 |

+ All PJ operations were performed using the Partington procedure.

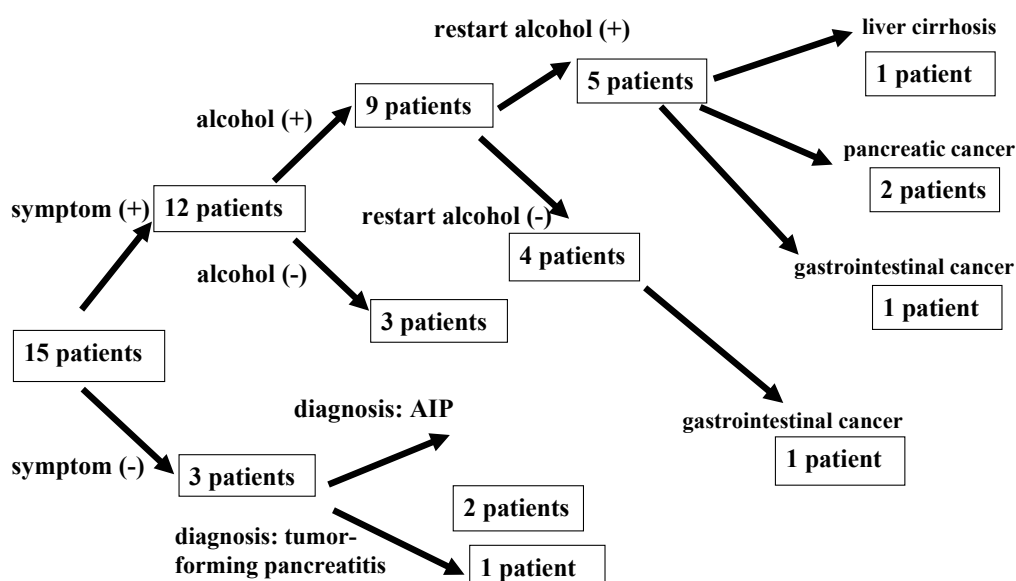


Figure 1. Clinical characteristics of the 15 patients included in this study. Among the 9 patients in whom chronic pancreatitis was attributed to heavy preoperative alcohol consumption, 5 resumed alcohol consumption postoperatively. These include patients who died of hepatic failure (1 patient), pancreatic cancer (2 patients).

DISCUSSION

Conservative treatment with medication for pain control remains the mainstay of therapy for chronic pancreatitis [4]. Endoscopic therapy is also used to treat spasmodic pain, pancreatic cysts and abscesses, stenosis, and other symptoms of chronic pancreatitis [4]. Surgical therapy is indicated in 137 patients with pain refractory to conservative therapies or in those with complications, such as bile duct and/or duodenal stenosis and aneurysms, or in patients in whom pancreatic cancer cannot be excluded [4, 5]. Surgical therapy for chronic pancreatitis is categorized into the following types of procedures: neurotomy, pancreatic duct drainage, and pancreatectomy [1, 5]. Neurotomy is performed for patients with mild-to-moderate spasmodic pain. However, its applicability is limited. Pancreatic duct drainage is useful for patients with a dilated main pancreatic duct [1, 5]. Pancreatectomy is effective for patients with localized lesions [1, 5]. The advantages and disadvantages of each procedure should be considered when determining the optimal treatment strategy for each patient [1, 5]. In this study, 12 patients with recurrent pancreatitis (despite the administration of long-term multidisciplinary medical therapy) were treated surgically. Among these, DP was performed in 9 patients with localized lesions and PJ in 3 patients with diffuse lesions and a dilated main pancreatic duct. Surgical therapy for chronic pancreatitis is primarily aimed at symptomatic treatment of pain and complications to improve patients' QOL and facilitate rehabilitation. Recent clinical studies report that surgery performed during the early phase of the disease effectively controls pain and maintains patients' QOL [6]. A large-scale retrospective study in Japan reported excellent pain control in patients who underwent surgery. Notably, surgical treatment could potentially reduce the risk of pancreatic cancer [7]. Hence, surgical therapy may prevent disease progression in addition to symptom resolution. In the present study, we observed that all 12 patients with recurrent abdominal pain showed postoperative improvement. In this study, 5 of the 9 patients who admitted to heavy preoperative alcohol consumption resumed this activity after postoperative improvement in symptoms, despite our repeated instructions and emphasis on alcohol abstinence. These patients showed worsening including progressive concomitant hepatic disease, resulting in poor prognosis. Patient education on an outpatient basis

is difficult; therefore, we propose interdepartmental coordination involving neuropsychiatry consultations and interventions such as home healthcare services in specific categories of patients. Some patients developed postoperative gastrointestinal cancer including pancreatic cancer; therefore, careful evaluation for cancer is also important during follow-up.

Conclusion

Surgical treatment successfully controlled abdominal pain in patients with recurrent pancreatitis. Owing to the risk of postoperative liver disease and pancreatic cancer, pre- and postoperative alcohol abstinence and close follow-up for cancer should be emphasized.

Conflicts of Interest

The authors declare that they have no conflict of interest.

References

1. Singh VK, Yadav D, Garg PK. Diagnosis and Management of Chronic Pancreatitis: A Review. *JAMA - J Am Med Assoc* 2019; 322:2422-34. [PMID: 31860051].
2. Díte P, Ružicka M, Zboril V, Novotný I. A prospective, randomized trial comparing endoscopic and surgical therapy for chronic pancreatitis. *Endoscopy* 2003; 35:553-8. [PMID: 12822088].
3. Andrews L. Endoscopic or surgical intervention for painful obstructive chronic pancreatitis. *Gastroenterol Nurs* 2016; 39:404-18. [PMID: 27684639].
4. Drewes AM, Bouwense SAW, Campbell CM, Ceyhan GO, Delhaye M, Demir IE, et al. Guidelines for the understanding and management of pain in chronic pancreatitis. *Pancreatology* 2017; 17:720-31. [PMID: 28734722].
5. Ishida M, Motoi F. Surgical management of chronic pancreatitis. *J Japanese Soc Gastroenterol* 2017; 114:2118-24.
6. Cahen DL, Gouma DJ, Laramée P, Nio Y, Rauws EAJ, Boermeester MA, et al. Long-term outcomes of endoscopic vs. surgical drainage of the pancreatic duct in patients with chronic pancreatitis. *Gastroenterology* 2011; 141:1690-5. [PMID: 21843494].
7. Ueda J, Tanaka M, Ohtsuka T, Tokunaga S, Shimosegawa T. Surgery for chronic pancreatitis decreases the risk for pancreatic cancer: A multicenter retrospective analysis. *Surg (United States)* 2013; 153:357-64. [PMID: 22989892].