

## Ectopic Gastric Submucosal Pancreatic Tissue

George H Sakorafas<sup>1</sup>, Michael G Sarr<sup>2</sup>

<sup>1</sup>Department of Surgery, 251 Hellenic Air Force Hospital. Athens, Greece.

<sup>2</sup>Department of Surgery, Mayo Clinic. Rochester, MN, USA

A 37-year-old woman was found to have a submucosal mass in the gastric antrum. She presented with recurrent episodes of right upper quadrant pain. Evaluation included a normal abdominal ultrasonography and esophagogastroduodenoscopy, which revealed a benign appearing 1 cm sessile polypoid mass in the gastric antrum (Image 1). The gastric mucosa over the mass was normal both visually and histopathologically on biopsies. Endoscopic ultrasonography revealed a 1x0.5 cm submucosal mass (Image 2). The patient strongly desired having this removed and, therefore, was operated with the presumed diagnosis of a gastric leiomyoma. The mass, easily identified at surgery, was removed through a gastrotomy. Histology revealed ectopic pancreatic tissue within the gastric submucosa.

While this is not an uncommon finding on the serosa of the small bowel (Image 3), a submucosal pancreatic rest is quite unusual [1, 2, 3].

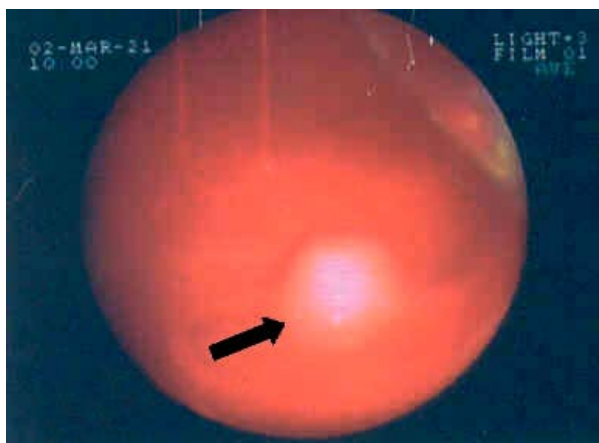

Image 1

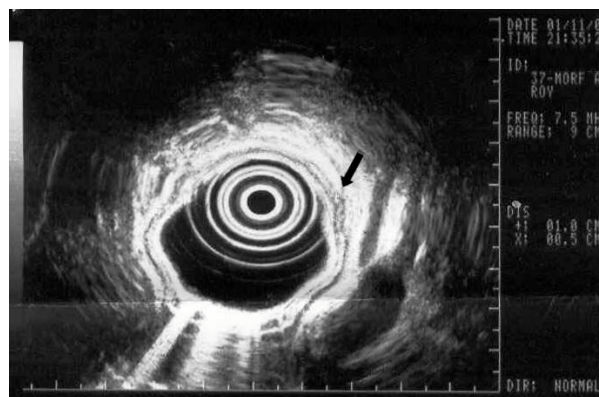


Image 2

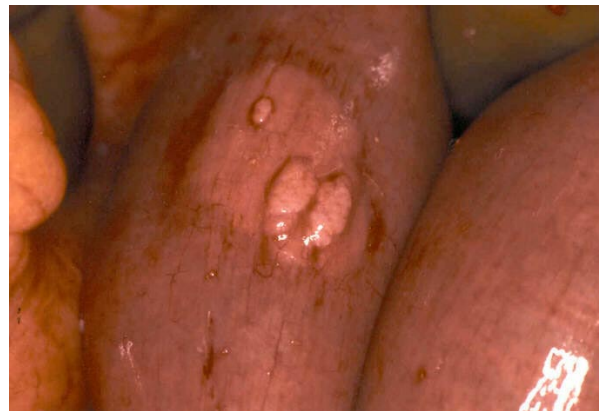

Image 3

Received September 11<sup>th</sup>, 2003 - Accepted September, 30<sup>th</sup>, 2003

**Keywords** Abnormalities; Anatomy; Case Report; Diagnostic Imaging; Histology; Pancreas

### Correspondence

George H Sakorafas  
Arkadias 19-21  
GR-115 26 Athens

Greece

Phone:+30-210.7487.318

Fax:+30-210.7487.192

E-mail address: [georgesakorafas@yahoo.com](mailto:georgesakorafas@yahoo.com)

---

**References**

1. Matsushita M, Takakuwa H, Nishio A. Endosonographic features of gastric adenomyoma, a

type of ectopic pancreas. *Endoscopy* 2003; 35:621-2. [PMID 12822101]

2. Gottschalk U, Casper B, Boden G. Ectopic pancreas presenting as a large gastric antral papilla. *Endoscopy* 2003; 35:547. [PMID 12783360]

3. Harold KL, Sturdevant M, Matthews BD, Mishra G, Heniford BT. Ectopic pancreatic tissue presenting as submucosal gastric mass. *J Laparoendosc Adv Surg Tech* 2002; 12:333-8. [PMID 12470407]