

## Duodenal Diverticulitis Presenting as Cholangitis

Berendsen L<sup>1\*</sup>, Bouman DE<sup>2</sup> and Venneman NG<sup>1</sup>

<sup>1</sup>Department of Gastroenterology and Hepatology, MST Enschede, The Netherlands

<sup>2</sup>Department of Radiology, MST Enschede, The Netherlands

\*Corresponding author: Berendsen L, Department of Gastroenterology and Hepatology, MST Enschede, The Netherlands, Tel: (053) 487 2410; E-mail: L.Berendsen@mst.nl

Rec date: Feb 06, 2017; Acc date: Apr 26, 2017; Pub date: Apr 29, 2017

Citation: Berendsen L, Bouman DE, Venneman NG. Duodenal Diverticulitis Presenting as Cholangitis. J Clin Gastroenterol Hepatol 2017, 1: 2.

### Abstract

An Endoscopic Retrograde Cholangiopancreatography (ERCP) was performed because of suspected ascending bacterial cholangitis due to common bile duct stones. A prominent papilla with an abnormal aspect was noticed. Given the suspicion of a malignancy, a CT-abdomen and additional gastroduodenoscopy were performed for further analysis. These resulted in the final diagnosis: duodenal diverticulitis, which apparently mimicked ascending bacterial cholangitis. Conservative treatment with supportive care resulted in full recovery.

**Keywords:** Cholangitis; Duodenal obstruction; Gallstones

### Case Presentation

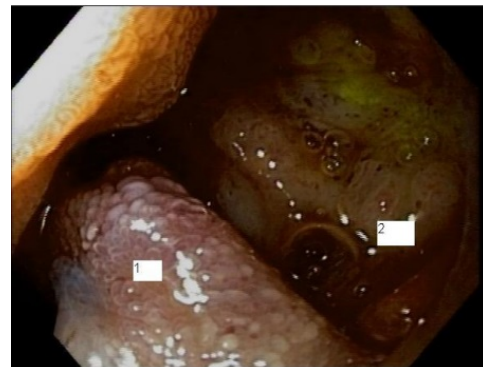
A 90-year-old female patient was referred to our hospital with suspicion of ascending bacterial cholangitis due to common duct stones. Her medical history reported breast cancer and a recent admission to another hospital because of cholangitis, from which she quickly recovered after intravenous antibiotics.

Her main complaints were nausea and loss of appetite. In addition, she experienced an unpleasant taste in her mouth. Blood tests showed elevated liver enzymes (Alkaline Phosphatase: 734 U/L, gamma-Glutamyl Transpeptidase: 2003 U/L, Aspartate Amino-transferase 303 U/L, Alanine Aminotransferase 407 U/L, bilirubin: 47 µmol/L; all 3 × upper limit of normal) and elevated C-reactive protein. Abdominal ultrasound, performed in another hospital, showed a dilated common bile duct of which the distal part could not be examined. Another finding was the presence of multiple gallbladder stones.

### Discussion

Suspecting recurrent ascending bacterial cholangitis due to bile duct stones, an Endoscopic Retrograde Cholangiopancreatography (ERCP) was performed. The major papilla was bulging, but not due to the classic configuration of

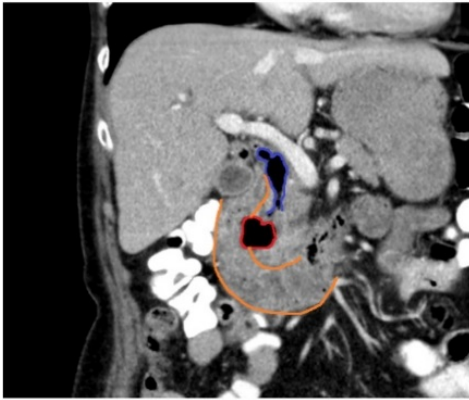
an impacted gallstone. Despite of a small pre-cut papillotomy, cannulation of the common bile duct was not achieved. Given the suspicion of malignancy, an abdominal CT-scan was performed. This showed a large juxtapapillary diverticulum with massive air in the common bile duct. No other abnormalities were seen in papillary or pancreatic region (**Figure 1**). Additional linear gastroscopy showed a diverticulum, localized proximal of the major papilla, from which pus was dripping. The cavity of the diverticulum showed hyperaemic mucosa with fibrinous tissue.



**Figure 1** 1-Edge of diverticulum; 2-Bottom of diverticulum.

We concluded therefore that our patient suffered from duodenal diverticulitis (**Figure 2**), a disorder, although rare, that has been reported previously [1,2]. Recurrent cholangitis with massive common bile duct air was probably caused by perforation of the diverticulum into the common bile duct. Several days after admission, with only supportive care, our patient was released from the hospital with a further uneventful course.

There is another case-report of a patient suffering from cholangitis caused by an ampullary duodenal diverticulum in which the surgical treatment consisted of choledochojejunostomy utilizing a Roux-en-y-loop [3]. Our case showed that antibiotic treatment and supportive care may be sufficient.



**Figure 2** Orange: duodenal configuration with inflammatory respons; Blue: Aerobilla (Common Bile Duct); Red: Juxtapapillary diverticula.

## References

1. De Perrot T, Poletti PA, Becker CD, Platon A (2012) The complicated duodenal diverticulum: Retrospective analysis of 11 cases. *Clin Imaging* 36: 287-294.
2. Luz LP, Eloubeidi MA (2009) Duodenal diverticulitis mimicking cholangitis: Endoscopic and EUS appearance. *Am J Gastroenterol* 104: 2125-2126.
3. Castilho Netto JM, Speranzini MB (2003) Ampyillary dudenal diverticulum and cholangitis. *Sao Paulo Med J* 121: 173-175.