

CASE REPORT

Distal Pancreatectomy with Celiac Axis Resection for Pancreatic Cancer Following Coil Embolization of the Common Hepatic Artery

Hisashi Gunji, Akihiro Cho, Hiroshi Yamamoto, Matsuo Nagata, Osamu Kainuma, Nobuhiro Takiguchi, Hiroaki Souda, Atsushi Ikeda, Akinari Miyazaki

Department of Gastroenterological Surgery, Chiba Cancer Center Hospital, Chiba, Japan

ABSTRACT

Context It has been reported that some locally advanced pancreatic body and tail cancers can be radically resected by distal pancreatectomy with celiac axis resection. However, the removal of the celiac axis can result in fatal complications due to hepatic ischemia. **Case report** A Seventy-two-year-old man with pancreatic body cancer was selected to undergo distal pancreatectomy with celiac axis resection. We performed coil embolization of the common hepatic artery to obtain adequate hepatic inflow from the gastroduodenal artery prior to distal pancreatectomy with celiac axis resection. R0 resection was achieved by distal pancreatectomy with celiac axis resection. No complications related to hepatic arterial deficiency occurred during the postoperative course, and no evidence of recurrence has been seen for 28 months. **Conclusion** Preoperative embolization of the common hepatic artery is a useful technique for avoiding hepatic ischemia when distal pancreatectomy with celiac axis resection is performed in patients with pancreatic body and tail carcinoma. This procedure has the potential to improve the resectability of pancreatic cancer.

INTRODUCTION

Despite recent developments in diagnosis and therapy, the survival outcome of patients with pancreatic body and tail cancer remains dismal [1, 2, 3, 4, 5, 6]. The crucial factor is its low resectability rate because it easily invades the important vessels, such as the common hepatic artery (CHA), the splenic artery (SPA), the celiac artery (CA), and the superior mesenteric artery (SMA).

The Appleby operation was first performed for patients with gastric cancer to achieve radical lymph node dissection along the celiac axis [7, 8]. In 1976, Nimura used this operative technique in patients with pancreatic body and tail cancer [9]. This technique is attractive for tumor clearance in patients with pancreatic cancer, but fatal complications related to hepatic arterial insufficiency sometimes occur. Transient clamping of the CHA and verifying the pulsation of the proper hepatic artery (PHA) is a common method for avoiding hepatic ischemia. Other procedures during operation have also been reported.

Kondo proposed preoperative coil embolization of the CHA to develop hepatic arterial flow via the pancreatic arcade from the SMA [10]. Here, we present this procedure in a patient with a locally advanced pancreatic body cancer that invaded the celiac artery.

CASE REPORT

A Seventy-two-year-old man was referred to our hospital for the evaluation and treatment of a huge pancreatic tumor. Gastroscopy showed a large submucosal tumor at the gastric body. Enhanced computed tomography (CT) revealed a huge tumor of the pancreatic body that consisted of solid and cystic components. Although it appeared highly likely that the SPA, SPV, and CA were involved by tumor, the SMA, gastroduodenal artery (GDA), and portal vein (PV) were not involved (**Figure 1**). Neither hepatic metastasis nor ascites was detected. The patient's serum carcinoembryonic antigen (CEA) level was 11.8 ng/mL, which was beyond the normal range, and the carbohydrate antigen (CA) 19-9 level was 2.0 U/mL, which was within the normal range. Thus, DP-CAR was planned to achieve a cancer-negative margin.

Angiography and embolization of the CHA

Angiography was performed to evaluate the anatomy of the peripancreatic vessels and to perform coil embolization of the CHA preoperatively.

Superior mesenteric arteriography showed no encasement of the SMA. The right hepatic artery (RHA) was branching from the SMA. Subsequent portography showed a smooth PV. CT during arterial portography confirmed no hepatic metastasis.

Received July 5th, 2016 - Accepted July 22nd, 2016

Keywords Pancreatectomy; Pancreatic Neoplasms; Surgical Procedures, Operative

Abbreviations CA celiac artery; CHA common hepatic artery; GDA gastroduodenal artery; PHA proper hepatic artery; PV portal vein; SMA superior mesenteric artery; SPA splenic artery; RHA right hepatic artery

Correspondence Hisashi Gunji
Department of Gastroenterological Surgery
Nitona 666-2, Chuo-ku
Chiba 260-8717, Japan
Tel + 81 243 264 5431
Fax + 81 043 262 8680
E-mail hgunjijp@yahoo.co.jp

Although celiac arteriography revealed encasement of the SPA and CA, the GDA and PHA were intact. Coil embolization of the CHA and CA was performed with the interlocking detachable coil (IDC; Platinum Coil Vascular Occlusion System®, Boston Scientific) as the anchor for preventing coils from prolapsing to the PHA.

After embolization, superior mesenteric arteriography showed development of the pancreatic arcade (**Figure 2**). No complications occurred during and after the angiographic procedure.

Operative procedure

Two days after embolization the operation was performed. Following laparotomy, it was clear there were no hepatic metastases or peritoneal dissemination.

On opening the bursa omentalis, the cancer adhered to the stomach, but there was no invasion of the GDA and SMA, which indicated that DP-CAR was feasible. The pancreas was cut using a linear stapler just above the PV. The left side of the neural plexus around the SMA was peeled toward the root of the SMA, safely preserving the replaced RHA, and the root of the CA was exposed. The CA was ligated and divided. The color of the liver surface never changed.

Retroperitoneal dissection was done sustaining the layer exposing the left renal vein and kidney. Finally, the distal pancreas, retroperitoneal tissue, stomach, spleen, and lymph node were resected en bloc (**Figure 3**). The gastric reconstruction was done in the Roux-en-Y fashion.

Clinical And Pathological Outcome

On pathology, the resected tumor measured 4.5x4.0x4.0 cm. The histological diagnosis was invasive ductal carcinoma derived from an intraductal papillary mucinous neoplasm, a well differentiated tubular adenocarcinoma. According to the General Rules of Study of Pancreatic Cancer of the Japanese Pancreas Society, the tumor was pT4, s+, rp+, a+, pl+, oo+, pcm-, dpm-, ly1, v1, ne3, n3; H0 P0 T4 N3 M0 stage IVb, R0 resection.

Perineural invasion was severe, and the cancerous involvement reached to the adventitia of the CA and SPA; however, the cut end of the CA was free of carcinoma. The patient's postoperative course was uneventful, and he was discharged on the 14th postoperative day. The patient had diarrhea that occurred several times per day, but it has been controlled by medication. He is now followed as an outpatient. No obvious evidence of recurrence has been detected for 28 months.

DISCUSSION

The prognosis of pancreatic cancer is regarded as one of the most dismal of the solid tumors.

Body and tail pancreatic cancer is more likely than pancreatic head cancer to be detected when it is unresectable. Even with a potentially curative resection, long-term survival is difficult to achieve. The overall 5-year

survival rate of resected left sided pancreas cancer is 9.6%-22% in the recent literature [1, 2, 3, 4], while several reports have documented that R0 resection can provide a chance for cure [1, 6].

DP-CAR is regarded as the extreme radical pancreatectomy for pancreatic body and tail cancer. However, its benefit for long-term survival is controversial, since very few cases have been published, and the outcome of consecutive series has never been reported. For selected locally advanced cases, successful R0 resection by DP-CAR was reported, mainly from a Japanese hospital [9, 10, 11, 12, 13, 14, 15]. They concluded that this procedure can increase resectability

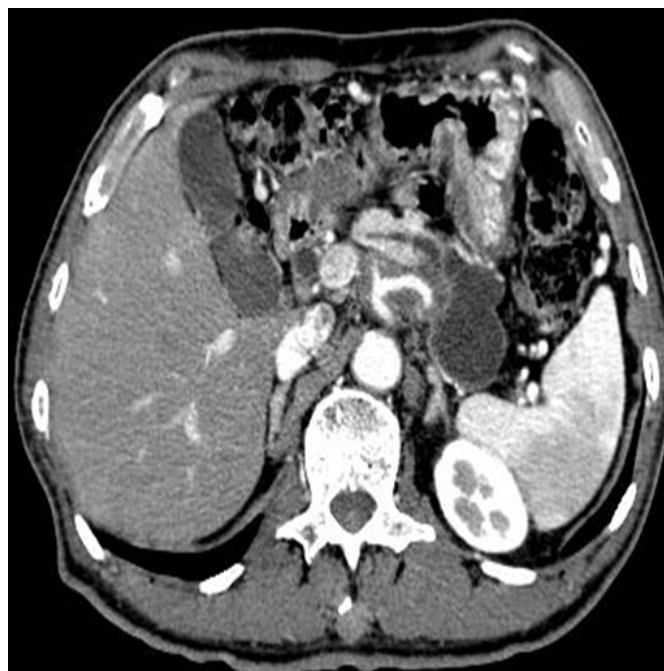

Figure 1. The enhanced CT shows that the pancreatic body tumor, including the cystic component, is involving the celiac axis.

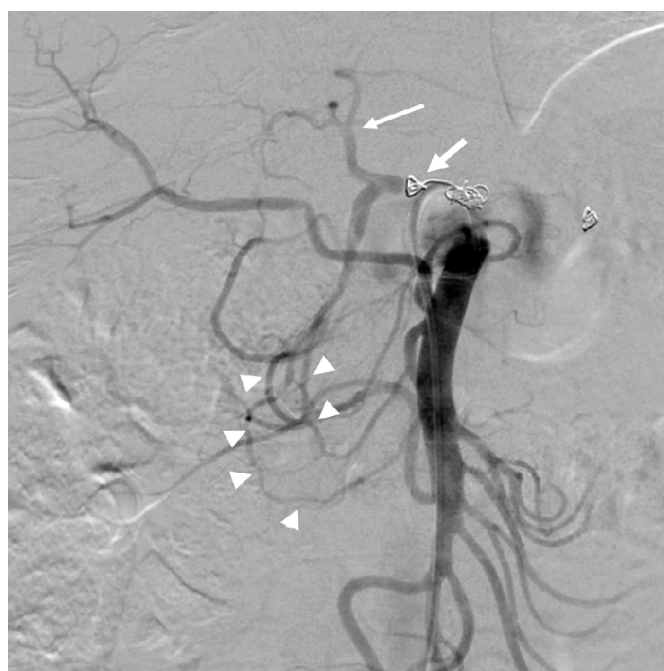

Figure 2. Superior mesenteric arteriogram after embolization of the CHA by coils (thick arrow) shows good visualization of the left hepatic artery (thin arrow) via the obvious pancreatic arcade (arrow heads).

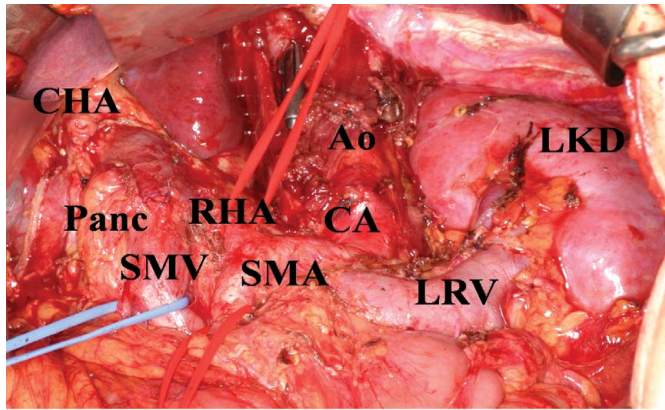


Figure 3. The operative figure after resection of the stomach, spleen, body and tail of the pancreas, CHA, SPA, and CA.

Ao aorta; CA the stump of the celiac artery; CHA the stump of the common hepatic artery; LKD left kidney; LRV: left renal vein; Panc the pancreatic stump; RHA; the replaced right hepatic artery; SMA superior mesenteric artery; SMV superior mesenteric vein

of body and tail pancreatic cancer, and it offers patients a better quality of life with removal of back pain, but it does not improve clinical outcome.

Distal pancreatectomy concomitant with en bloc resection of the celiac axis is the ideal operation for patients with cancerous involvement of the root of the CHA or SPA, but it can be potentially complication due to hepatic arterial ischemia.

When the CA is resected, most hepatic inflow is compensated by the blood flow of the SMA via the pancreatic arcade. However, the flow volume of the pancreatic arcade varies with the individual. Moreover, Kimura reported that, in 12% of autopsy cases, the arcade between the posterior superior pancreaticoduodenal (PSPD) artery and the posterior inferior pancreaticoduodenal (PIPD) artery was not found [16]. In fact, Konishi reported that two of four cases needed CHA reconstruction because the pulsation of the PHA was weak after occlusion of the celiac axis [11].

To avoid inadequate hepatic inflow, several procedures have been proposed; Hirai reported the usefulness of intraoperative Doppler ultrasonography [17]. Miyakawa measured hepatic venous hemoglobin oxygen saturation to assess the hepatic circulation [18]. These two methods require hepatic arterial reconstruction if the hepatic inflow is estimated to be insufficient [19]. To the best of our knowledge, the only method to ensure adequate hepatic arterial flow without reconstruction is preoperative embolization of the CHA. This technique was firstly reported by Kondo [10]. The safety of this technique is based on the previous study in which the temporary occlusion of the CHA using a balloon catheter caused immediate arterial distribution to the liver from the SMA [20]. The reason why we embolized the CHA even though this patient had the RHA replaced from the SMA was to avoid the risk of hepatic ischemia by incidental injury of the replaced RHA when dissecting the neural plexus around the SMA. In this angiographic procedure, preventing coils from prolapsing to the PHA is crucial. Thus, we used the interlocking

detachable coil (IDC), which is often used for embolization of aneurysms [21]. The weakness of this procedure is the lack of objective evidence of development of the pancreatic arcade, even though the thickened pancreatic arcade was visualized. One must also consider the risk of intimal injury to the artery due to decreased arterial flexibility caused by cancerous involvement. "An optimal timing of the operation after embolization is still unknown. Long interval period has both the potential for the development of pancreatic arcade and the risk of cancerous spread. Although the radical resection was safely performed only two days after embolization in this case, further investigation is needed in the arterial collateral flow." Even though pathology showed cancerous invasion extending to the adventitia of the CA and SPA in this case, the patient has been free of recurrence without adjuvant chemotherapy for 28 months. Although more cases are needed to determine the safety and benefit of this approach, this procedure can contribute to improving the resectability of pancreatic body and tail cancer without serious morbidity.

Conflict of Interest

The authors declare that there is no conflict of interests regarding the publication of this paper.

References

1. Sohn TA, Yeo CJ, Cameron JL, Koniaris L, Kaushal S, Abrams RA, Sauter PK, et al. Resected adenocarcinoma of the pancreas--616 patients: results, outcomes, and prognostic indicators. *J Gastrointest Surg* 2001; 5: 681; author reply 681. [PMID: 12086909]
2. Christein JD, Kendrick ML, Iqbal CW, Nagorney DM, Farnell MB. Distal pancreatectomy for resectable adenocarcinoma of the body and tail of the pancreas. *J Gastrointest Surg* 2005; 9:922-7. [PMID: 16137585]
3. Bergenfeldt M, Moesgaard F, Burcharth F. Curative resection for left-sided pancreatic malignancy. *HPB (Oxford)* 2006; 8:211-5. [PMID: 18333279]
4. Shoup M, Conlon KC, Klimstra D, Brennan MF. Is extended resection for adenocarcinoma of the body or tail of the pancreas justified? *J Gastrointest Surg* 2003; 7: 946-52; discussion 952. [PMID: 14675703]
5. Shimada, K., Sakamoto Y, Sano T, Kosuge T. Prognostic factors after distal pancreatectomy with extended lymphadenectomy for invasive pancreatic adenocarcinoma of the body and tail. *Surgery* 2006; 139:288-9. [PMID: 16546491]
6. Wagner M, Redaelli C, Lietz M, Seiler CA, Friess H, Büchler MW. Curative resection is the single most important factor determining outcome in patients with pancreatic adenocarcinoma. *Br J Surg* 2004; 91:586-94. [PMID: 15122610]
7. Appleby LH. The coeliac axis in the expansion of the operation for gastric carcinoma. *Cancer* 1953; 6: 704-7. [PMID: 13059764]
8. Appleby LH. Removal of the celiac axis in gastrectomy for carcinoma of the stomach in selected cases: a ten-year assessment. *J Int Coll Surg* 1960; 34:143-7. [PMID: 13793980]
9. Nimura Y, Hattori T, Miura K, Nakajima N, Hibi M. Our experience of resection of carcinoma of the body and tail of the pancreas by Appleby's procedure. *Operation* 1976; 15:885-889. (In Japanese)
10. Kondo S, Katoh H, Shimizu T, Omi M, Hirano S, Ambo Y, Okushiba S, et al. Preoperative embolization of the common hepatic artery in preparation for radical pancreatectomy for pancreas body cancer. *Hepatogastroenterology* 2000; 47:1447-9. [PMID: 11100373]

11. Konishi M, Kinoshita T, Nakagori T, Inoue K, Oda T, Kimata T, Kikuchi H, et al. Distal pancreatectomy with resection of the celiac axis and reconstruction of the hepatic artery for carcinoma of the body and tail of the pancreas. *J Hepatobiliary Pancreat Surg* 2000; 7:183-7. [PMID: 10982611]
 12. Kimura W, Han I, Furukawa Y, Sunami E, Futakawa N, Inoue T, Shinkai H, et al. Appleby operation for carcinoma of the body and tail of the pancreas. *Hepatogastroenterology* 1997; 44:387-93. [PMID: 9164507]
 13. Horiguchi A, Miyakawa S, Mizuno K, Ishihara S, Miura K. Portal vein resection without reconstruction during Appleby operation in a patient with pancreatic body carcinoma with cavernous transformation. *Hepatogastroenterology* 1999; 46:2628-30. [PMID: 10522054]
 14. Liu B. Modified Appleby operation in treatment of distal pancreatic cancer. *Hepatobiliary Pancreat Dis Int* 2003; 2:622-5. [PMID: 14627533]
 15. Yamaguchi K, Nakano K, Kobayashi K, Ogura Y, Konomi H, Sugitani A, Tanaka M. Appleby operation for pancreatic body-tail carcinoma: report of three cases. *Surg Today* 2003; 33:873-8. [PMID: 14605963]
 16. Kimura W, Nagai H. Study of surgical anatomy for duodenum-preserving resection of the head of the pancreas. *Ann Surg* 1995; 221:359-63. [PMID: 7726671]
 17. Hirai I, Kimura W, Kamiga M, Mizutani M, Takeshita A, Watanabe T, Fuse A. The significance of intraoperative Doppler ultrasonography in evaluating hepatic arterial flow when assessing the indications for the Appleby procedure for pancreatic body cancer. *J Hepatobiliary Pancreat Surg* 2005; 12:55-60. [PMID: 15754101]
 18. Miyakawa S., Horiguchi A, Hanai T, Mizuno K, Ishihara S, Niwamoto N, Iwase Y, et al. Monitoring hepatic venous hemoglobin oxygen saturation during Appleby operation for pancreatic cancer. *Hepatogastroenterology* 2002; 49:817-21. [PMID: 12063998]
 19. Takenaka H., Iwase K, Ohshima S, and Hiranaka T. A new technique for the resection of gastric cancer: modified Appleby procedure with reconstruction of hepatic artery. *World J Surg* 1992; 16:947-51. [PMID: 1462635]
 20. Nakamura H, Tanaka M, and Oi H. Hepatic embolization from the common hepatic artery using balloon occlusion technique. *AJR Am J Roentgenol* 1985; 145:115-6. [PMID: 3873830]
 21. Irie K, Taki W, Nakahara I, Sakai N, Isaka F, Kikuchi H. Endovascular treatment of a partially thrombosed giant basilar tip aneurysm using interlocking detachable coils--case report. *Neurol Med Chir (Tokyo)* 1997; 37:681-4. [PMID: 9330532]
-