

Comparison Between Distal Paravertebral and Line Block Anesthesia for Laparotomy in Goats

Yadav SK^{1*}, Bostami MB², Ryad HM¹, Sarkar S³ and Sutradhar BC¹

¹Department of Medicine and Surgery, Chittagong Veterinary and Animal Sciences University (CVASU), Bangladesh

²Pet Hospital and Research Center Dhaka (CVASU), Bangladesh

³Department of Veterinary and Upazilla Livestock Services, Nazirpur, Pirojpur, Bangladesh

*Corresponding author: Saroj Kumar Yadav, MS Surgery, Department of Medicine and Surgery, Chittagong Veterinary and Animal Sciences University (CVASU), Bangladesh, Tel: 008801770307209; E-mail: shirfraaz@gmail.com

Received date: February 26, 2019; Accepted date: April 25, 2019; Published date: April 30, 2019

Copyright: ©2019 Yadav SK, et al. This is an open-access article distributed under the terms of the Creative Commons Attribution License, which permits unrestricted use, distribution, and reproduction in any medium, provided the original author and source is credited.

Citation: Yadav SK, Bostami MB, Ryad HM, Sarkar S, Sutradhar BC (2019) Comparison Between Distal Paravertebral and Line Block Anesthesia for Laparotomy in Goats. J Vet Med Surg. Vol. 3 No. 1: 23.

Abstract

Objectives: Towards relate the probability and efficiency of two methods of local anesthesia with Lidocaine 2% for laparotomy in goat.

Material and methods: A total of 10 goats experiencing laparotomy were divided into two groups of 5: one group undertook a Line block anesthesia (Line Block) technique consisting of an incisional line block, and the other group undertook distal paravertebral anesthesia (DPVA). Indications for laparotomy were rumenotomy and exploratory laparotomy. The two methods were compared with affection to the reaction of the goats to the application of anesthesia, the degree of difficulty and the amount of time and anesthetic agent required. The reactions of the goats to incision of the various layers of the abdominal wall, abdominal exploration and surgical closure of the abdomen and wound healing time were evaluated.

Results: The study was about a comparison of which technique is better for laparotomy. Both techniques required a mean of 5 minutes to complete but the DPVA method was considered more difficult than the LB. Comparison of the two techniques in respect to different types of pain reactions (no reaction, non-specific reaction, specific reaction) during cutting of the different layers of the abdominal wall revealed that DPVA provided significantly better analgesia than the LB. After DPVA, pain reactions to incision of the external oblique abdominal muscle were more severe, but reactions to abdominal exploration and to suturing the two oblique abdominal muscles were significantly milder than after LB and wound healing was significantly better than the LB.

Conclusion and clinical significance: Neither technique resulted in the consistent and complete elimination of pain reactions in every patient, but overall DPVA had better results than the LB. The analgesic effect of both techniques could be improved by mild tranquilization/sedate before laparotomy.

Keywords: Postsurgical seroma; Incisional hernia; Distal paravertebral anesthesia (DPVA); Laparotomy; Hematological parameters

Introduction

Laparotomy is universally designated for exploratory drives when the clinical diagnosis is inexact or for therapeutic surgical involvement has been made [1]. It is solitary of the furthestmost conjoint surgical procedures in livestock practice which is customarily accomplished on standing cattle [2]. However, no document recorded in standing goats. In Bangladesh a lot of vegetables (e.g., carrot, radish, cabbage, potato etc.) and cereal crops (e.g., rice, wheat, pulses etc.) are produced frequently. When the prices of these products get down in the market and sometimes excess feeding of the products can create acidosis with bloat and choke. That time it needs to remove the materials from rumen with laparotomic intervention. For Chittagong with a lot of goats in number from the aesthetic point of view as well as in Hindu religious festival named Manasha puja, people sacrifice goats for the Goddess Manasha. So, the laparotomy is common for the above-mentioned conditions. For research, Shahedul Alam Quaderi Teaching Veterinary Hospital (SAQTVH) is renowned in Bangladesh and of courses in the world. We did the intervention as research. In contrast to general anesthesia, there is less to cardiovascular depression and no inhibition of the visceral organs in local and regional anesthesia. During local anesthesia exertion and charge for the surgery is lower than in general anesthesia [3]. For the laparotomy, it is an absolute absence of pain in the incision and occlusion of the abdominal cavity. The mode of action of local anesthetics comprises blockade of sodium channels, which checks nerve depolarization. Lidocaine may use by perineural infiltration, intra-articular or epidural injection provides excellent analgesia. Lidocaine is the commonly used local anesthetics in veterinary medicine, but it has a historical reputation of being toxic to goat kids [4,5]. For the enough desensitization of the flank, 13th thoracic spinal nerve and the

first two lumbar spinal nerves need to be anesthetized. Elimination of the sensitivity of peritoneum is caused by the switching of the second lumbar spinal nerve reached. This one gives a branch that runs on the surface of the peritoneum [6]. In the literature, there are different methods of local anesthesia for the laparotomy in the area of hunger pit [3]. The flank area is easily desensitized by performing a line block, which is the most commonly used method in food animals [3]. Disadvantages of this technique are the large volume of local anesthetic and the lack of relaxation of the back and abdominal muscles [7]. Furthermore, incomplete anesthesia of the deeper layers in heavy animals as well as hematomas and seromas due to injections [8]. The infiltration of cutting line with a local anesthetic may cause tissue damage and wound healing disorders [9] especially at the addition of vasoconstrictors. Another disadvantage of line infiltration is an intraoperative necessary magnification at post-anesthesia that renewed access waiting until the onset of action is required [7]. Distal paravertebral anesthesia (DPVA) is intended to be safely in being pain-free and easy, fast and with little local anesthetic can be performed [10]. The performance area is complete and uniform in all layers anesthetized [7]. In inflammatory reactions around the incision line in the flank or in a relaparotomy with distal paravertebral anesthesia is better than incision infiltration [3]. The disadvantage of this technique has difficulty in fatty animals. On the other hand, the orientation leads to anatomical distinctive points not always safe anesthesia, because the spinal nerves follow a variable path [6]. One of the dangers of DPVA is the possibility of penetration of large blood vessels. Besides, it is the uncertainty of the pelvic limbs upon diffusion of the local anesthetic in the route of motor nerves [3,7].

Materials and Methods

Study period

The present study was conducted during the period of July 2017 to June 2018 at Shahidul Alam Quadery Teaching Veterinary Hospital (SAQTVH), Chittagong Veterinary and Animal Sciences University (CVASU) Chittagong, Bangladesh.

Study area

The study was driven at SAQTVH in Chittagong Veterinary and Animal Sciences University as case registered and outpatients of Chittagong Metropolitan area of Chittagong (Figure 1).

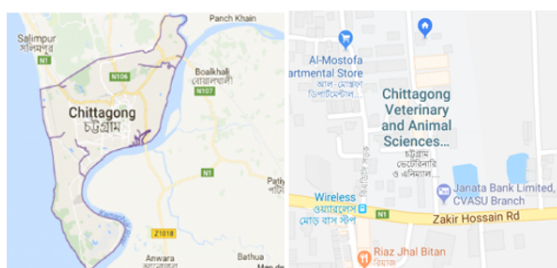

Figure 1 Geographical location of study area.

Study design

A total of ten (n=10) samples from two groups mixed with male and female (5 male and 5 female of local breed) of different ages were chosen for this study (Figure 2).

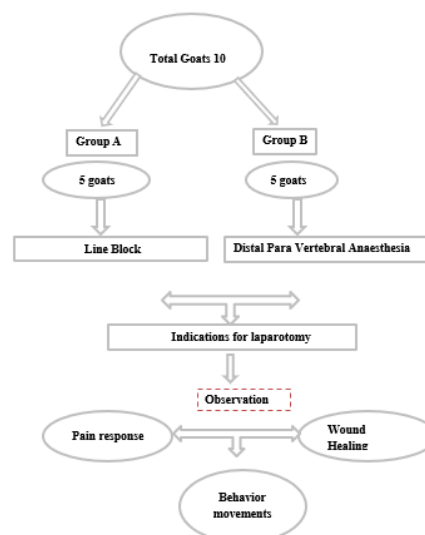


Figure 2 The overall experimental design of this study.

Preoperative measures

For laparotomy, the goats were in a stationary or a fixed mobile togetherness before the start of blocking, proper shaving from T13 to L4 and sketch diagram of nerve supply for proper nerve block was drawn for proper detection and identified the nerves for proper anesthesia and pain sensation measure.

Anesthesia

As a local anesthetic, lidocaine 2% solution came without further additives for use (Jasocane 2%, Jayson pharma Dhaka Bangladesh) Lidocaine does @6 mg/kg BW [11] for two types of techniques applied as distal paravertebral anesthesia and modified line infiltration. After setting the respective anesthesia was waited at least for 5 minutes, before the operation started [2].

Surgical procedure

Feed and water were withdrawn from animals at least 12 hours prior to the surgery. The left flank region of each goat in both groups was prepared for routine aseptic surgery by clipping the hairs around the proposed surgical site; the site was scrubbed with Povidone-iodine solution containing 10% povidone-iodine (Opsonin Pharma Limited, Dhaka) and then flushed with 70% alcohol. Regional anesthesia was achieved with a plain 2% lidocaine hydrochloride and injection (Jason Caine, Jayson pharma limited, Dhaka).

Goats of both groups were placed on the right lateral recumbency exposing the left flank. Laparotomy was done according to the standard procedure described by Ames et al.

[11,13,14]. The laparotomy was routinely closed from within outward; muscle layers were closed using Jonson chromic catgut of the size of 1/0 and atraumatic ½ circle taper point needle (Anhui Kangning Industrial Groups, China) using simple continuous to peritoneum and ford interlock in the muscle layer (Figure 3).

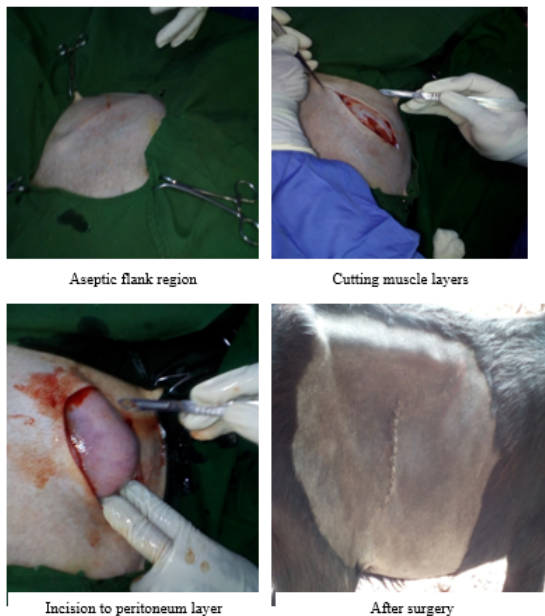


Figure 3 Surgical procedure.

The subcutaneous layer was closed using Jonson chromic catgut of the size of 2/0 and atraumatic ½ circle taper point needle using simple continuous suture pattern. The skin was closed using a vertical mattress suture pattern with nylon of the size of 0 and atraumatic 3/8 curved, cutting needle (Agary Pharmaceuticals Ltd, Xinghuai, China). Meloxicam injection at the rate of 0.5 mg/kg subcutaneous injection (ACME Pharmaceutical, Dhaka) was administered for 3 days after surgery to take care of postoperative pain. Ampicillin injection at the rate of 20 mg/kg BW (ACI Pharmaceutical, Dhaka) was administered for 5 days after surgery to control the secondary bacterial infection (Figure 5).

Distal paravertebral anesthesia (DPVA)

The skin of the left last ribs to fourth lumbar transverse process was clipped and scrubbed with disinfectant over the surgical area where the needle was introduced. The distal paravertebral nerve block desensitizes the dorsal and ventral rami of the spinal nerves T13, L1, and L2 at the distal ends of the transverse processes of L1, L2, and L4, respectively. A 23-gauge, 3.5 cm needle was inserted ventral to the transverse process, and 6 ml of local anesthetic was infused in a fan-shaped pattern (Figure 4).

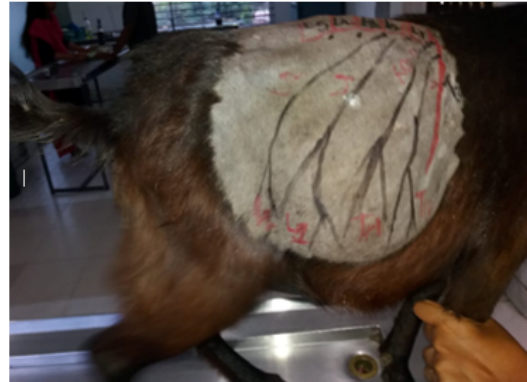

Figure 4 Distal Paravertebral anesthesia technique. Drawing of the nerve supply T13, L1, L2, L3 and L4 palpation of the cranial edge of the transverse process of lumbar vertebra (redline denotes lumbar vertebra and black denotes nerve supply) of an imaginary line for the anesthesia of the first lumbar spinal nerve.

The needle was removed completely and then reinserted or redirected dorsal to the transverse process, in a caudal direction, where 2 ml of local anesthetic was again infused in a fan-shaped pattern. This procedure was repeated for the transverse processes of the L2 and L4 lumbar vertebrae of spinal nerves.

Line block (LB)

A 23-gauge 3.5-cm needle is used to infuse multiple small injections of 6 mL of local anesthetic solution subcutaneously and into the deep muscle layers and peritoneum. The pain of successive injections may be alleviated by placing the edge of the needle into the edge of the previously desensitized area at an approximately 20-degree angle (Figure 5).

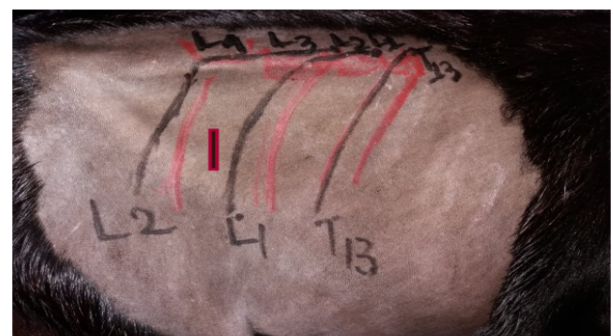

Figure 5 The technique of the line block anesthesia (LB) where the red and black color denote nerve supply and LB block with 2% of lidocaine and deep red line denotes a line of incision.

Surgical wound assessment

The clinical appearance of the skin was assessed and scored twice: 18-24 hours and 10-25 days after surgery as described by Sylvestre et al. [15] using a 4-point scoring scale, based on the following criteria: discharge, swelling, erythema, and dehiscence. Mostly complication was seen after surgery to monitor the wound to know the wound healing conditions.

Hematology

Blood samples were collected from each animal in the groups through the jugular vein after thorough disinfection of the area with 70% alcohol, the sample was collected using 5 mL syringe and needle into EDTA bottles. The samples were collected before surgery as a baseline (T0), 24 hours after anesthesia (T24) and one week after surgery (T7). Physiological parameters were taken manually (heart rate taken by auscultation with a stethoscope, pulse rate taken by digital counting, respiration by counting abdominal movement, rectal temperature with a clinical thermometer) at intervals of 0, 30, 60 minutes and 24 hours after lignocaine administration. The samples were analyzed using digital hematology analyzer (Full Automated Blood Cell Counter PCE-210, Erma Inc, Tokyo, Japan) according to the procedure described [16,17].

Intra- and postoperative complication

Intra and post-surgical complications were assessed using a 3-point scoring system designed, parameters considered were intraoperative hemorrhages, postsurgical seroma, incisional hernia, and wound fistula described by a protocol from Abubakar et al. [18] (Table 1).

Table 1 Criteria used to score intraoperative and postsurgical complications.

Outcome	Scores		
	0	1	2
Haemorrhage	None	Mild	Severe
Seroma	None	Mild	Severe
Wound fistula	None	Mild	Severe
Incisional hernia	None	Mild	Severe

Subjective healing interval

Subjective healing interval was determined by visual observation and taking notes of days of apparent surgical site healing b (Figures 6 and 7).

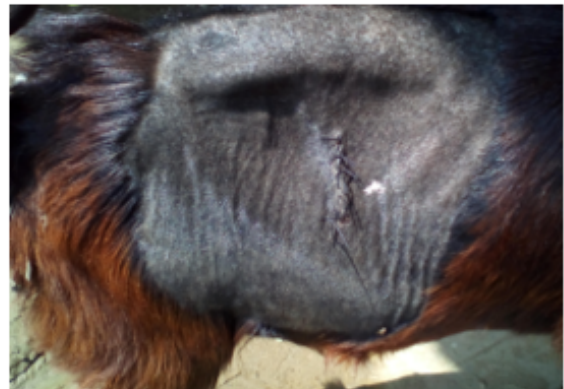

Figure 6 Wound healing condition in DPVA after 5 days.

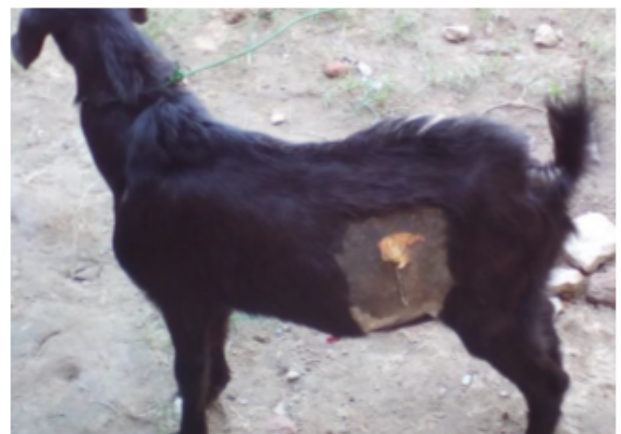

Figure 7 Wound healing condition after 5 days in line block.

Data collection and analysis

In the anesthesia protocol, the reactions of the animal to the set the local anesthesia in six given reaction degrees noted (Table 2). The documentation also included the required amount of local anesthetic and the time required for the performance of local anesthesia. In the operation log, there were the pain reactions in the various stages of the procedure detained (Table 2). In an evaluation of reaction with grade 0 was allowed to the animal during the carried-out action showed no reaction. Resulted in a rating with grade 1 to 3, the animal showed nonspecific reactions that were not in connection with the manipulations of the anesthetist or the surgeon had to stand, so no statement regarding allow pain. The animal left clear signs of restlessness and defense resulted in a rating with the reactions of grades 4 to 6 considered to be specific. Out of 10 goat patients, 6 averaged 7 days (Maximum 25 days) daily in the clinic to be examined. Creating the logs and recording the data were done after an introduction to the assessment of the BCS, in the anesthetic methods and in the surgical procedure. For data entry specially created data sheets were used in the "Microsoft

Excel, Windows Version 10". The statistical evaluation was done with the "Data Analysis" tools. The differences in the mean values were calculated by "t-test. Two samples assuming unequal variances". For comparisons between forms of anesthesia, the odds ratio (OR) determined. A p-value of <0.05 was considered significant.

Table 2 Grading of patient reactions that occurred during the application of lidocaine, during abdominal incision/closure and during exploration of the abdominal cavity.

Degree of reaction		Behavior
0	Nonspecific reaction	No reaction
1		Slight skin or muscle twitching (slight Moan)
2		Distinct muscle twitching (strong moaning)
3		Trippeln / unrest
4	Specific reaction	Defensive movements like hitting with the leg
5		Dodge attempts such as going back and forth
6		Outbreak attempt / intention to go down

Results

Both the pre-piercing and the subsequent application of the local anesthetic caused pain reactions. The risk of an animal showing a pricking response was significantly greater in DPVA when applying the local anesthetic. Proved at the LB the piercing and the anesthetic application is the same pain. Regarding the surgical opening of the abdominal cavity, there were some significant differences. The average pain score line block anesthesia was more painful than the average pain score in distal paravertebral anesthesia technique were pain reduction in the two techniques.

Comparison of pain response between line block (lb) vs distal para vertebral block (DPVA)

The present study reveals that distal paravertebral anesthesia is less pain for laparotomy than the Line block anesthesia (**Figure 9**). The below graph shows the red line as the timing of pain response in DPVA compared to the timing of pain response in LB by a blue line. Pain shows a better response in DPVA as less pain in the specific time of laparotomy (**Figure 8**).

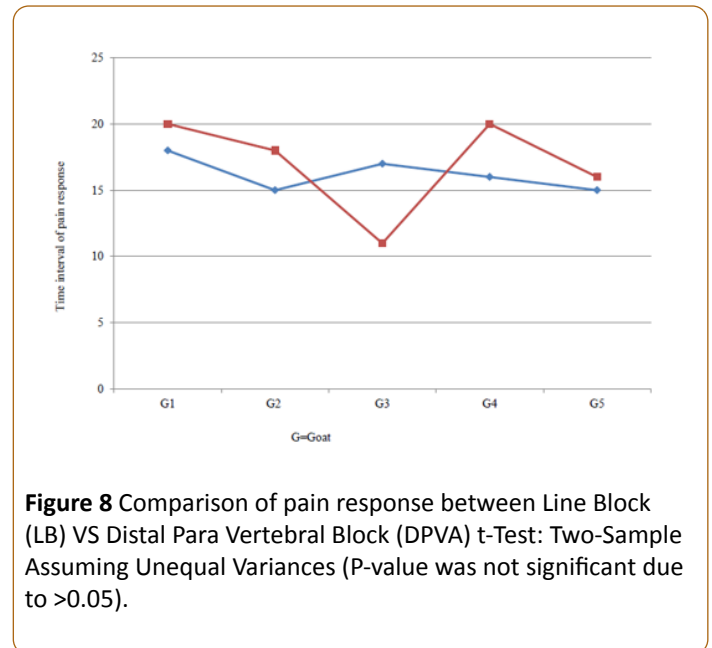


Figure 8 Comparison of pain response between Line Block (LB) VS Distal Para Vertebral Block (DPVA) t-Test: Two-Sample Assuming Unequal Variances (P-value was not significant due to >0.05).

Animals movements behaviors

The present study based on goat movements behaviors which were my target pain response measurement key for evaluation and grading. In this study, we can see mostly non-specific reaction behaviors, so we can say that 2% lidocaine anesthesia for pain management is good in both interventions. The below table had taken the responsibility to judge the different conditions of that two intervention which was necessary for the study (**Table 3**).

Table 3 Grading of patient reactions that occurred during the application of lidocaine during abdominal incision/closure and during exploration of the abdominal cavity.

Degree of reaction		Behavior
0	Nonspecific reaction	No reaction
1		Slight skin or muscle twitching (slight Moan)
2		Distinct muscle twitching (strong moaning)
3		Trippeln / unrest

Pain response during time

Pain responses during the preparation time of the patient and as well as in application time had been separated in three grades ranges. The bar diagram reveals almost the same pain response in "grade 0" ranges for both in DPVA and LB. As time advanced, for the middle bars configured as grade 1-3 got a good knock in application period which means the anesthetic is working well. We can see that during application time DPVA create more pain than the LB (**Figure 9**).

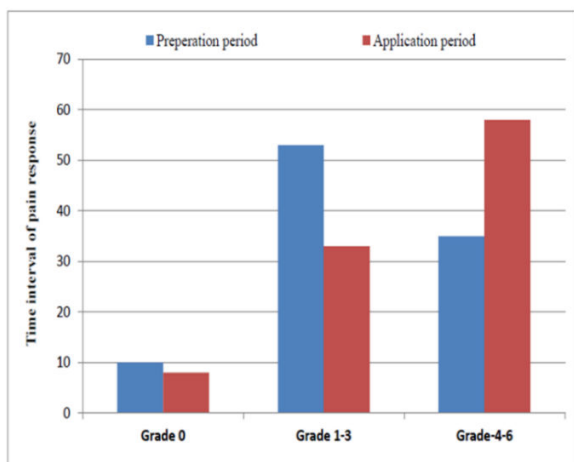


Figure 9 Percentage of pain reaction during DPVA and LB for preparation time and application time (in minutes).

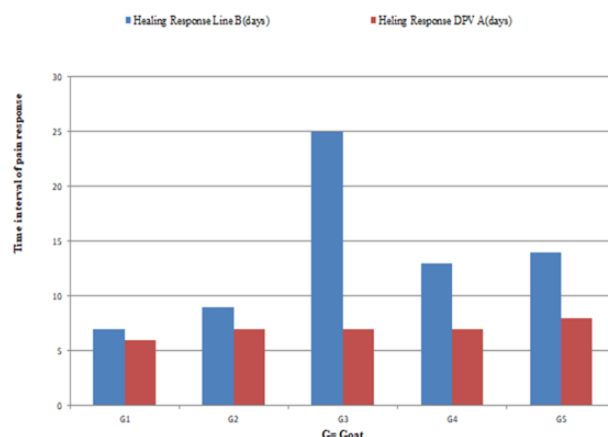


Figure 10 Comparison of wound healing response between Line Block (LB) VS distal Paravertebral Block (DPVA) t-Test: Two-Sample Assuming Unequal Variances (P – value was not significant due to >0.05).

Comparison of wound healing response

Comparison between two techniques of wound healing revealed that DPVA had good wound healing response than the LB and there was no infection in DPVA but one case (Goat-3) had a complication during the healing process which delayed the time of healing (**Figure 10**).

Hematology parameter

The hematological values observed in this study were within the normal range as the lignocaine had worked well to control cardiac arrhythmia and suppressing automaticity and this may have helped to keep the hematological parameters within a normal range (**Table 4**).

Table 4 Total leucocytes and differential leucocytes count before and after surgery of the DPVA and LB approaches (mean \pm SD).

Parameters	Mean scores			
	Groups	Before surgery	24 hours of surgery	One week after surgery
RBC ($\times 10^6/\ell$)	DPVA	12.32 \pm 1.35	12.79 \pm 1.23	12.23 \pm 1.32
	MIA	13.13 \pm 0.51	13.69 \pm 0.52	13.36 \pm 0.85
PCV (%)	DPVA	21.92 \pm 2.56	24.66 \pm 5.24	16.15 \pm 2.85
	MIA	25.22 \pm 1.19	25.90 \pm 1.15	25.72 \pm 4.37
Hemoglobin (g/d)	DPVA	8.12 \pm 1.36	8.98 \pm 2.25	8.63 \pm 1.51
	MIA	9.16 \pm 0.43	9.84 \pm 0.59	9.86 \pm 1.28
Total WBC ($\times 10^3/\ell$)	DPVA	25.48 \pm 4.19	37.70 \pm 3.90	34.93 \pm 3.12
	MIA	33.86 \pm 9.96	50.52 \pm 16.32	51.08 \pm 5.07
Granulocytes ($\times 10^3/\ell$)	DPVA	11.10 \pm 3.69	13.24 \pm 3.45	10.23 \pm 5.72
	MIA	11.38 \pm 4.41	20.90 \pm 10.51	18.62 \pm 5.07
Lymphocytes ($\times 10^3/\ell$)	DPVA	11.74 \pm 3.27	19.16 \pm 2.61	21.33 \pm 8.22
	MIA	33.86 \pm 3.40	24.06 \pm 7.37	28.32 \pm 11.98
Monocytes ($\times 10^3/\ell$)	DPVA	2.60 \pm 0.89	4.08 \pm 1.21	3.35 \pm 0.66
	MIA	4.14 \pm 1.02	5.60 \pm 1.54	4.12 \pm 0.44

Discussion

Till date, the study reported here was the first in which investigators compared two local anesthetic techniques for laparotomy in the goats. 10 goats experiencing laparotomy were divided into two groups where five animals, undertook a technique consisting of an incisional line block and the other five undertook distal paravertebral anesthesia. Both techniques required a mean of five minutes to complete but the line block method was considered more difficult than the distal paravertebral anesthesia. After distal paravertebral anesthesia, pain reactions to incision of the external oblique abdominal muscle were more severe, however, reactions to abdominal exploration and to suture the two oblique abdominal muscles were significantly milder than after line block. Wound healing was significantly better than inline block. Neither technique resulted in a consistent and complete elimination of pain reactions in every patient, but overall distal paravertebral anesthesia had better results than the line block.

The assessment of the pain behavior of an animal is selfsame life-threatening to measure in animals like cattle and goat [9,19]. About their specific pain expressions or the individual pain, sensitivity is little known [19,20]. The administration of 6 ml (100 mg) @ of 6 mg/kg BW of 2% lignocaine hydrochloride to accomplish distal paravertebral nerve block produced appreciable analgesia of the lateral abdominal wall. It is noteworthy that 2 ml (40 mg) of the drug was deposited at each site rather than 3 ml (60 mg) as specified by some authors. This deliberate reduction in the volume of lignocaine has a significant implication on both the economy of cost and reduced toxicity to the animal, which supports my present study [7,26]. In the course of the investigation, it became clear that not only the comparison of the two methods but also the effectiveness of local anesthesia was put to the test. The results obtained in this study shown that the DPVA is more feasible and easier, which was also recommended by Nuss [2]. The implementation of LB not only referred to the inexperienced, but also more than 50% of experienced anesthetists mention that as "not easy". Reason for that it often deep or small hunger pit, worrying to hurt abdominal organs, as well defensive movements of the animals. Probably also played one role that the injection for the LB because of the larger length also had a larger diameter than those for the DPVA which was also recommended by Nuss [2]. For infiltration anesthesia should, therefore, be possible to use thin needles to help the pain in the present examination could about pain reactions. DPVA is less panic then the LB which is also recommended by Nuss [2].

The present investigation was in the prospect of a better distribution of the anesthetic and thereby achieve a better effect. However, the DPVA was not in most cases as a mention for [3,10] reliable in pain elimination. Furthermore, it would be desirable to have more potent local anesthesia [3] for livestock available, for longer operations. The BCS of the animals influenced neither feasibility in the present study still the effectiveness of anesthesia. In bleeding, the needle was withdrawn and placed differently. Diffusion of the local anesthetic toward the pelvic limb, recognizable by an unstable state or by a decline of the Patients [7,23] could not be observed

in any of the animals. For the assessment of pain during the operation appeared the distinction in "no reaction", "unspecific reaction" and "specific response" most important because the pain cannot be eliminated. These findings encourage to refine the anesthesia techniques and to use more advanced measures, such as light sedation which is also recommended by Nuss et al. [2].

Subcutaneous and muscular infiltration at LB provided good anesthesia. At the incision of the Marcus obliquus externus significantly underperformed the DPVA and LB obviously, the local anesthetic was at the incision initially effective under LB in the area of the cutting line and then quickly became non-specific in the well-perfused muscle, which is recommended by Löscher [24]. When wound closure was done, the effect got subsided, so that the Marcus obliquus externus and internally abdominis significantly showed more reactions after DPVA occurred. The duration of action of lidocaine was thus too short for pain response.

The present study reveals that the use of plain lidocaine which is better than the combined with epinephrine which is also recommended by Skarda et al. [3]. Study on DPVA, the depth was in the nerve surrounding connective and fatty tissue, thus reducing the active ingredient runs slower and the effect is guaranteed longer which was also recommended by Link and Smith [25]. At the LB were because of the rapid decay of the effect also no differences in the painfulness at long continuous and short-lasting operations determine. Therefore, for the laparotomy in goats, a more potent local the anesthetic will be available regarding the more difficult to infiltrate deeper muscle layers. There were no differences between LB and DPVA in terms of effectiveness. That's good, contrary to expectations cutting off the LB in the deep layers are likely to be on their component, which is believed to be one the DPVA equivalent anesthesia of the inner layers contributed. Present study mention that exploration of the abdominal cavity by local anesthetics techniques among the DPVA significantly fewer signs of pain, which is also recommended by Nuss [2]. During the study period, replenishment was usually only after incision of the external oblique abdominal, it is seen that the pain reactions remained too strong. In the present Investigation when the animals feel more pain then surgery pause for a while. This was also practiced in other studies [26,27]. Sedation of the goat in laparotomy is discussed in the literature. In recent years, however, the opinions prevail, that the positive effects justify the use of xylazine [14,23]. The Sedation is the mode of administration of xylazine important. The intravenous administration leads to a faster, more intensive effect and to better analgesia than intramuscular administration. At the subcutaneous injection is the least risk that the Animal goes down [28]. but in the present research, there is no use of xylazine for sedation. In the present study, there were slight variations of total white blood cells (WBC) count of the two approaches before surgery, at 24 hours, and at the first week after surgery, the LB group had slight variation WBC value at all the intervals with non-significant differences at first and second week after surgery [29,30]. There were slight variations of total granulocytes between the two groups with the LB group having slightly higher values at all the intervals, but there is no

significant difference between the two groups. The lymphocytes values of the two groups also varied and the LB approach had the slight highest value which is also supported by Abubakar [18].

In present study seen that LB techniques for laparotomy among five, one goat has shown edema in incision line and wound healing delayed for 25 days but there is no any infection seen in DPVA and wound healing seen in nearly 7-8 days but in LB takes longer time then DPVA so we can say that DPVA is better than the LB supported by Skarda [12].

In summary, it should be noted that both investigated anesthesia techniques in a part of the animals are not satisfactory pain switch was achieved. This unsatisfactory effectiveness can be due to the technical implementation of anesthesia, but also at the relatively weak effect and short duration of action of lidocaine falsehood [31-35].

Conclusions

After conducting the study on comparison of two methods of local anesthesia for laparotomy in goat had reached few decisions like:

- Local anesthesia is very effective in field condition to save the animals
- Both anesthetic techniques could reduce the pain completely suppress reactions in only 50% of the animals.
- The pain was more reliably switched off under DPVA than under MIA.
- A replenishment of local anesthetic should be scheduled for both techniques become furthermore, slight sedation of the animals which help to reduce more painless laparotomy.
- More potent local anesthetics as procaine 2%, for example, lidocaine, should be used for the laparotomy in goat.

Acknowledgment

We would like to thank full to the directors of Shahidul Alam Quadery Teaching Veterinary Hospital (SAQTVH).

References

1. Hendrickson DA (2007) Techniques in Large Animal Surgery. Black, well Publishing, Ames, Iowa USA, 3rd edn, pp: 221-223.
2. Nuss K, Eiberle BJ, Louis SC (2012) Comparison of two methods of local anaesthesia for laparotomy in cattle. *Veterinary Practice* 40: 141-149.
3. Skarda RT, Tranquilli WJ (2007) Local and regional anesthetic and analgesic techniques: ruminants and swine. *Lumb & Jones Veterinary Anesthesia and Analgesia*, pp: 643-681.
4. Taylor PM (1991) Anaesthesia in sheep and goats. *Practice* 1: 31-36.
5. Smith MC, Sherman DM (2009) Dehorning and descenting. *Goat Medicine*, 2nd edn. pp: 723-731.
6. Arnold JP, Kitchell RL (1957) Experimental Studies of the Innervation of the Abdominal Wall of Cattle. *American Journal of Veterinary Research* 67: 229-240.
7. Ivany JM, Muir WW (2004) Farm animal anesthesia. *Farm animal surgery*. St Louis (MO): WB Saunders, pp: 97-112.
8. Edmondson MA (2008) Local and regional anesthesia in cattle. *Veterinary Clinics of North America: Food Animal Practice* 24: 211-226.
9. Steiner A, von-Rotz A (2003) The most important local anesthesia in cattle: A Review. *Schweiz Arch Tierheilkd* 145: 621-663.
10. Farquharson J (1940) Paravertebral lumbar anesthesia in the bovine species. *Journal of American Veterinary Medicine Association* 1: 54-57.
11. Ames NK (2007) *Noordsy's. Food Animal Surgery*. Wiley-Blackwell, 5th edn, p: 960.
12. Skarda RT (1986) Techniques of local anesthesia in ruminants and swine. *Veterinary Clinic North American Food Animal Practics* 2: 621-663.
13. Freeman DE (2003) *Abdominal Surgery. Summary Procedure and Principles*, International Veterinary Information Service, New York, USA, p: 22.
14. Tuagi RP, Singh J (1993) *Ruminant surgery. Textbook of the Surgical Disease of Cattle, Buffaloes, Camels, Sheep and Goats*, C.S.B Publishers and Distributors, New Delhi, India 1: 195-223.
15. Sylvestre A, Wilson J, Hare J (2002) A comparison of two different suture patterns for skin closure of canine ovariohysterectomy. *The Canadian Veterinary Journal* 43: 699-702.
16. Egbe-Niyi TN, Nwaosu SC, Salami HA (2000) Haematology values of apparently healthy sheep and goats as influenced by age and sex in arid zone of Nigeria. *African Journal of Biomed Research* 1: 109-115.
17. Egbe-Niyi TN, Nwaosu SC, Salami HA (2000) Haematology values of apparently healthy sheep and goats as influenced by age and sex in arid zone of Nigeria. *African Journal of Biomed Research*, pp: 109-115.
18. Abubakar AA, Andeshi RA, Yakubu AS, Lawal FM, Adamu U (2014) Comparative Evaluation of Midventral and Flank Laparotomy Approaches in Goat. *Journal of Veterinary Medicine*, p: 6.
19. Feist M, Köstlin R, Nuss K (2008) Examination of the Pain Expression Behavior of Cows after Claw Surgery. *Veterinarian Practice* 36: 367-376.
20. Anderson DE, Muir WW (2005) Pain management in ruminants. *Veterinary Clinics. Food Animal Practice*, pp: 19-31.
21. Olaifa AK, Olatunji-Akioye AO, Agbaje LO, Olatunji-Akioye AO (2009) Distal paravertebral nerve block effects on west african dwarf goat hematology and physiology. *Israel Journal of Veterinary Medicine*, p: 128.
22. Clarke KW, Trim CM (2013) *Veterinary Anaesthesia E-Book*. Elsevier Health Sciences, p: 352.
23. Muir MW, Hubbell JA, Bednarski RM, Skarda RT (2005) Local anesthesia in ruminants and pigs. *Handbook of Veterinary Anesthesia (4th edn)* Mosby, St. Louis, USA, pp: 72-99.
24. Löscher W (2006) Local anesthetics. *Pharmacotherapy for domestic animals and livestock*. 7th Parey in MVS Medical Publishing, pp: 125-130.
25. Link RP, Smith JCZ (1956) Comparison of some local anesthetics in cattle. *Journal of the American Veterinary Medical Association* 129: 306-309.

26. Holton L, Reid J, Scott EM, Pawson P, Nolan A (2001) Development of a behavior-based scale to measure acute pain in dogs. *Veterinary Record* 1: 525-531.
27. Underwood WJ (2002) Pain and distress in agricultural animals. *Journal of American Veterinary Medicine Association* 221: 208-211.
28. Budras KD, Wünsche A (2002) Atlas of the anatomy of the bovine. Hannover, Schlütersche GmbH and Co. KG, Publishing and Printing.
29. Dietz O, Henschel E, Busch W (1988) Anesthesia and operations on large and small animals. Sink, p: 215.
30. Frey HH, Löscher W (2002) Textbook of pharmacology and toxicology for veterinary medicine. Sink, p: 364.
31. Henke J, Erhardt W, Tacke S (2008) Analgesic protocols before, during and after anaesthesia of dogs and cats in painful situations. *Veterinary Practice of Small Animals/pets* 36: 27-34.
32. Hudson CD, Whay HR, Huxley JN (2008) Recognition and management of pain in cattle. In *Practice/BJM Journals* 30: 126-134.
33. Nickel R, Schummer A, Seiferle E (1992) Textbook of the Anatomy of Pets, Musculoskeletal System. Berlin and Hamburg Parey, p: 256.
34. Nuss K, Eiberle BJ, Louis SC (2012) Comparison of two local anesthetic techniques for laparotomy in cattle. *Veterinary Practice G: Large Animals/Livestock* 40: 141-149.
35. Callaghan KO (2002) Lameness in cattle and associated pain in cattle. *Challenging Traditional Perceptions*, pp: 212-219.