



Case Report: Alveolar Rhabdomyosarcoma of the Prostate Presenting as Lower Urinary Tract Symptoms in a Young Adult

Tiffany Grace C. Uy*, Gale Rizzae M. Alcala, Joseph C. Bocobo, Carmella Lou A. Bingcang, Anna Marie M. Pascual-Panganiban, Agnes S. Evangelista-Gorospe, Juliano Zacarias K. Panganiban, Marcelo Severino B. Imasa

Department of Medicine, St. Luke's Medical Center, Quezon City, Philippines

ABSTRACT

Introduction: Rhabdomyosarcoma (RMS) of the prostate in young adults is exceedingly rare.

Case presentation: A 27 year-old male presented with 2-month history of lower urinary tract symptoms. Prostate was enlarged smooth nontender with no nodularities. PET-CT showed prominent iliac chain lymph nodes, enlarged spleen and multiple osseous lytic and blastic lesions. Histopathology of prostate tissues revealed round cell malignancy, positive for Desmin and myogenin. Archer analysis was positive for PAX3: FOXO1 fusion gene. Patient was diagnosed as Alveolar Rhabdomyosarcoma of the prostate Stage IVB (cT4N1M1B-bone). He underwent Vincristine, Dactinomycin and Cyclophosphamide (VAC) chemotherapy.

Conclusion: Prostatomegaly and splenomegaly are unusual findings in a young male. A high index of suspicion will help in detecting prostatic malignancy before it is too late.

Keynote message: This reports the rare case of Alveolar Rhabdomyosarcoma of the prostate in a young male with lower urinary tract symptoms. It highlights the need for high index of suspicion in young patients with prostatomegaly, to help detect malignancy before it is too late.

Keywords: Lower urinary tract symptoms; Prostate cancer; Rhabdomyosarcoma

INTRODUCTION

Rhabdomyosarcoma (RMS) of the prostate in young adults is exceedingly rare. We report a case of Alveolar RMS prostate in a young adult presenting as lower urinary tract symptoms.

CASE PRESENTATION

A 27 years old man consulted for 2 month history of lower urinary tract symptoms. On physical exam, he had an enlarged smooth nontender prostate with no nodularities and no blood on examining finger. Traube's space was obliterated.

Initial workup showed Hb 8.9 g/dL Hct 26.4% WBC $7.1 \times 10^9/L$ (N54% L15% E3% M3% St17% Mye2% Metamyelocytes 6%) Platelets $102 \times 10^9/L$. PT 11.8 sec/INR 0.98/PTT 24.5 sec. Crea

1.61 mg/dL (CKD-EPI EGFR 60) BUN 26 mg/dL HCO₃ 27 meq/L Na 139 mmol/L K 3.4 mmol/L Cl 101 mmol/L iCa 1.16 mg/dL Mg 1.7 mg/dL, TC 170 mg/dL TAG 127 mg/dL HDL 51 mg/dL LDL 110 mg/dL ALT 66 IU AST 62 IU TB 0.56 mg/dL CB 0.17 mg/dL UB 0.39 mg/dL ALP 107 IU/L Albumin 4.47 g/dL. Urinalysis light yellow, clear urine, negative for glucose bile ketones protein nitrites blood and lymphocytes, SG 1.004, pH 7.0, RBC 0/HPF WBC 0/HPF Epithelial cells 0/HPF Casts 0/HPF Bacteria 0/HPF. PSA 0.23 ng/mL was normal for age.

As shown in **Figure 1**, Multiparametric Prostate MRI with contrast showed markedly enlarged prostate gland with intravesical extension measuring 6.6 cm × 7.1cm × 8.7 cm with a volume of 212 ml with a PIRADS 5 score.

Received: 31-May-2023

Editor assigned: 02-June-2023

Reviewed: 16-June-2023

Revised: 21-June-2023

Published: 28-June-2023

Manuscript No: IPRJO-23-16601

PreQC No: IPRJO-23-16601 (PQ)

QC No: IPRJO-23-16601

Manuscript No: IPRJO-23-16601 (R)

DOI: 10.36648/iprjo-7.2.11

Corresponding author Tiffany Grace C. Uy, Department of Medicine, St. Luke's Medical Center, Quezon City, Philippines, E-mail: tiffanygraceuy@gmail.com

Citation Uy TGC, Alcala GR, Bocobo J, Bingcang CL, Panganiban AM, et al. (2023) Case Report: Alveolar Rhabdomyosarcoma of the Prostate Presenting as Lower Urinary Tract Symptoms in a Young Adult. Res J Onco. 7:11.

Copyright © 2023 Uy TGC, et al. This is an open-access article distributed under the terms of the Creative Commons Attribution License, which permits unrestricted use, distribution, and reproduction in any medium, provided the original author and source are credited.

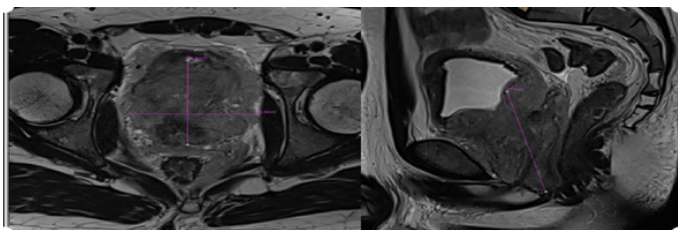


Figure 1: Prostate MRI. Multi-parametric MRI of the prostate gland, in T2 axial and T2 sagittal planes, showing prostatomegaly measuring 6.6 cm × 7.1 cm × 8.7 cm (AP × T × CC), with volume of 212 mL

FDG PET-CT showed FDG-avid mass in prostate gland, measuring 8.5 cm × 7.0 cm × 6.5 cm SUV 9.6, prominent to enlarged bilateral iliac chain lymph nodes, enlarged spleen and multiple osseous lytic and blastic lesions in L1 and L4 vertebral bodies, sacrum and bilateral pelvic bones.

Patient underwent Koelis US-MRI Fusion Transperineal prostate biopsy, bilateral ureteral stenting, with indwelling foley catheter. Histopathology showed round cell malignancy, immunohistochemistry positive for Desmin and myogenin.

As shown in **Figure 2**, bone marrow showed a markedly hypercellular bone marrow for age (>95%), with extensive infiltration of atypical cells and tumor giant cells. Immunohistochemistry was positive for CD56, Desmin and Myogenin. Genetic tests were positive for PAX3 (exon 7): FOXO1(exon 2) fusion gene.

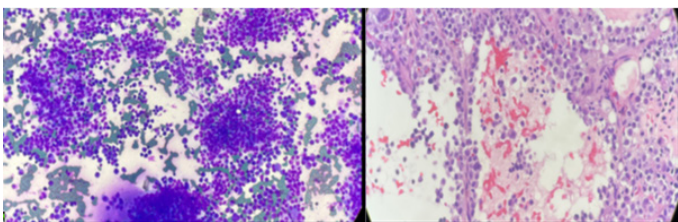


Figure 2: Histopathology of the bone marrow aspiration and core bone, right superior posterior iliac crest, showing bone marrow smear in high power view and trephine core in high power view

Dynamic Liver CT showed splenomegaly, slightly dilated portal and splenic veins with gastrosplenic collateral vessels and normal-sized liver. Liver elastography was F0.

Diagnosis was Alveolar Rhabdomyosarcoma of the prostate Stage IVB (cT4N1M1B-bone), with noncirrhotic portal hypertension, postobstructive uropathy s/p Ureteral stenting bilateral. Patient underwent 3 cycles of Vincristine (1.5 mg/m²), Dactinomycin (40 mcg/kg) and Cyclophosphamide (1200 mg/m²) MESNA. He was given Denosumab every 28 days and Caltrate advanced 2 tabs TID for bone protection and Carvedilol 6.25 mg daily for portal hypertension.

On serial follow-up, liver enzymes peaked at ALT 375 IU/L, AST 126 IU/L. Patient was given Legalon 140 mg TID, Transmetil 500 mg OD, Godex DS 300 mg capsule TID, Essentiale forte TID with decrease in liver enzymes. Creatinine trends remained stable ranging from 0.7 mg/dL to 0.8 mg/dL.

After 3 cycles, repeat FDG PET-CT showed significant regression in size and extent of hypermetabolism in the prostatic mass, with interval increase in hypermetabolic activity in its left prostatic lobe attributed to residual active malignancy. There was interval non-demonstration of the hypermetabolic iliac chain lymph nodes, stable mixed lytic-blastic lesions in the thoraco

lumbar vertebral bodies and sacrum.

He is currently set to undergo radiation therapy to the prostate midway through completion of entire chemotherapy regimen.

RESULTS AND DISCUSSION

Rhabdomyosarcoma (RMS) is a malignancy of mesenchyme cells that have varying degrees of differentiation towards skeletal muscle cells [1]. The most common affected sites are head and neck (28%), extremities (24%), with genitourinary tract only comprising 18% [2]. Rhabdomyosarcoma is generally a disease of children, and is exceedingly rare in adults [3].

Prostate RMS accounts for <1% of all prostate malignancies in adult life [4]. It is described only in case reports. Clinical presentation includes dysuria, urinary and rectal obstruction. PSA levels are usually normal. Main sites of metastasis include the lungs, liver and skeleton. Having a cancer predisposition syndrome, such as Neurofibromatosis, Noonan, Li Fraumeni, is the strongest risk factor for developing RMS [5].

RMS is histologically divided into embryonal, alveolar, spindle cell/sclerosing and pleomorphic subtypes. Each harbor characteristic genetic aberrations with implications for prognostication [6]. Due to high discordance among pathologists, genetic testing is used for confirmation.

For early stage RMS, surgical management aims for complete tumor resection. For unresectable cases, the mainstay of treatment remains to be chemotherapy. Vincristine sulfate, dactinomycin (actinomycin-D), and Cyclophosphamide (VAC) regimen remains the backbone of Pediatric RMS chemotherapy [7,8]. Due to the rarity of the disease in adults, there is a lack of standardized treatment in this age group, but retrospective studies have shown that concordance with pediatric protocols have better survival [9]. Hence our patient was managed with VAC. Since VAC has been associated with high risk of gonadal dysfunction, sperm cryopreservation was performed prior to initiation.

Compared to children, adult RMS has significantly worse outcome. Five-year overall survival in children was 61% compared to 27% in adults (7). The reason for poor survival has been found to be due to higher IRS stage, unusual histology and metastatic disease at the time of diagnosis. Additional studies have shown other factors that contribute to poor survival, including lack of compliance to the regimen, delays in diagnosis and the lack of RCTs for the adult groups [10,11].

The advent of gene testing has implications for prognostication, enabling identification of the specific genetic aberrations driving the tumors. This area of research may help find potential therapeutic targets in the future [12].

CONCLUSION

Prostatomegaly and splenomegaly are unusual findings in a young male. A high index of suspicion will help in detecting prostatic malignancy before it is too late.

CONSENT STATEMENT

Written informed consent was obtained from the patient to publish this report in accordance with the journal's patient

consent policy.

ACKNOWLEDGEMENT

None.

CONFLICT OF INTEREST

The authors declare no conflict of interest.

REFERENCES

1. Dondapati M, Reyes J, Ahmad S, Stern A, Lieber J (2021) Rare adult subtype of rhabdomyosarcoma, a common childhood soft tissue carcinoma. *J Investig Med High Impact Case Rep.* 9:23247096211042236.
2. Ciammella P, Galeandro M, D'Abbiero N, Palmieri T, Donini E, et al. (2013) Prostate embryonal rhabdomyosarcoma in adults: Case report and review of literature. *Rep Pract Oncol Radiother.* 18(5):310-315.
3. Bleyer A, O'Leary M, Barr R, Ries L (2006) Cancer epidemiology in older adolescents and 161 young adults 15 to 29 years of age, including SEER incidence and survival 1975-2000. *National Cancer Institute.* 06: 5767.
4. Stacchiotti S, Frezza A, Blay J, Baldini E, Bonvalot S, et al. (2021) Ultra-rare sarcomas: A consensus 163 paper from the connective tissue oncology society community of experts on the incidence threshold and the list of entities. *Cancer.* 127(16):2934-2942.
5. Amer K, Thromson J, Congiusta D, Dobitsch A, Chaudhry A, et al. (2019) Epidemiology, incidence, and survival of rhabdomyosarcoma subtypes: SEER and ICES database analysis. *J Orthop Res.* 37(10):2226-2230.
6. Parham D, Barr F (2013) Classification of rhabdomyosarcoma and its molecular basis. *Adv Anat Pathol.* 20(6):387-397.
7. Sultan I, Qaddoumi I, Yaser S, Rodriguez-Galindo C, Ferrari A (2009) Comparing adult and pediatric rhabdomyosarcoma in the surveillance, epidemiology and end Results program, 1973 to 2005: An analysis of 2,600 patients. *J Clin Oncol.* 27(20):3391-3397.
8. Crist W, Anderson J, Meza J, Fryer C, Raney R, et al. (2001) Intergroup rhabdomyosarcoma study-IV: Results for patients with nonmetastatic disease. *J Clin Oncol.* 19(12):3091-3102.
9. Ferrari A, Dileo P, Casanova M, Bertulli R, Meazza C, et al. (2003) Rhabdomyosarcoma in adults. A retrospective analysis of 171 patients treated at a single institution. *Cancer.* 98(3):571-580.
10. Kenney L, Laufer M, Grant F, Grier H, Diller L, et al. (2001) High risk of infertility and long term gonadal damage in males treated with high dose cyclophosphamide for sarcoma during childhood. *Cancer.* 91(3):613-621.
11. Makimoto A (2022) Optimizing rhabdomyosarcoma treatment in adolescents and young adults. *Cancers.* 14(9):2270.
12. Egas-bejar D, Huh W (2014) Rhabdomyosarcoma in adolescent and young adult patients: Current perspectives. *Adolesc.* 5:115-125.