

## CASE REPORT

# Biliary Migration of Pancreatic stents: Rare complication of Whipple Surgery

Divya Yadav, Prabhleen Chahal

Department of Gastroenterology and Hepatology, Digestive Disease Institute, Cleveland Clinic Foundation Cleveland, Ohio, USA

### ABSTRACT

**Context** Most of the pancreatic stents placed across pancreatojejunostomy at the time of Whipple procedure migrate spontaneously into the small bowel. **Case report** In this case series we present two patients with symptoms of abdominal pain, abnormal liver blood tests due to migration of pancreatic stents into the biliary tree through the choledochojejunostomy post Whipple surgery. **Conclusion** These cases highlight the symptomatic entity of spontaneous migration of pancreatic stent in to the biliary tree post Whipple surgery. However, this is easily treatable with an upper endoscopy.

### INTRODUCTION

Bridging of the pancreatico-enteric anastomosis by a pancreatic stent during Whipple surgery is a common procedure. Most of the pancreatic stents placed at the time of the surgery spontaneously migrate into the small bowel. We report 2 cases of pancreatic stents spontaneously migrating into the biliary system through the choledochojejunostomy opening.

### CASE REPORT

#### Case #1

A sixty-six-year-old male underwent a pylorus preserving Whipple procedure for cholangiocarcinoma one year prior to his presentation. He was referred to us for evaluation of new onset abnormal liver enzymes and jaundice without cholangitis.

Laboratory studies revealed AST level 41 U/L (reference range 7-40 U/L), ALT level 65 U/L (reference range 5-50 U/L) total bilirubin 12.9 mg/dL (reference range 0.0-1.5 mg/dL) and alkaline phosphatase 399 u/L (reference range 40-150 U/L). A CT scan of the abdomen showed prominence of the left intrahepatic biliary tree with pneumobilia. Migrated stent was seen extending from the

central left lobe to the level of the choledochojejunostomy site. The patient was referred to us for endoscopic retrieval of the migrated pancreatic stent [1].

With patient in the left lateral position, pediatric colonoscope was advanced to the choledochojejunostomy [2]. A 5F migrated plastic pancreatic stent was seen exiting the choledochojejunostomy anastomosis (**Figure 1**) which was successfully retrieved with a rat tooth forceps (**Figure 2**). Patient tolerated the procedure well and was discharged the same day with normalization of his AST, ALT and alkaline phosphatase and significant improvement in his total bilirubin level.

#### Case #2

A forty-one-year-old female underwent a Whipple procedure for serous cyst adenoma 2 months prior to her presentation. She was admitted to our facility with complaints of new onset upper abdominal pain she denied any fever. Laboratory studies revealed elevated liver enzymes with ALT 95U/L (reference range 7-40 U/L), AST 51 U/L (reference range 5-50 U/L) bilirubin total 0.3 mg/dL (reference range 0.0-1.5 mg/dL) and alkaline phosphatase 84 U/L (reference range 40-150 U/L). A CT scan of the abdomen showed a stent in the biliary system exiting through the choledochojejunostomy site. The patient was referred to us for endoscopic retrieval of the migrated stent [3].

With patient in the left lateral position, pediatric colonoscope was advanced in the bilio-pancreatic limb upto the choledochojejunostomy (**Figure 3**). The stent was successfully retrieved with a rat tooth forceps (**Figure 4**). There were no procedure related complications. She had complete resolution of her symptoms and she was discharged in 48 hours after the endoscopy with normalization of liver tests.

**Received** April 25th, 2015-**Accepted** May 29th, 2015

**Keywords** Biliary Tract; Endoscopy; Pancreaticoduodenectomy

**Correspondence** Prabhleen Chahal  
Cleveland Clinic

Mail Code A31  
9500 Euclid Avenue  
Cleveland, Ohio 44195

**Phone** +216 444- 6521

**Fax** +216 444-6284

**E-mail** CHAHALP@ccf.org

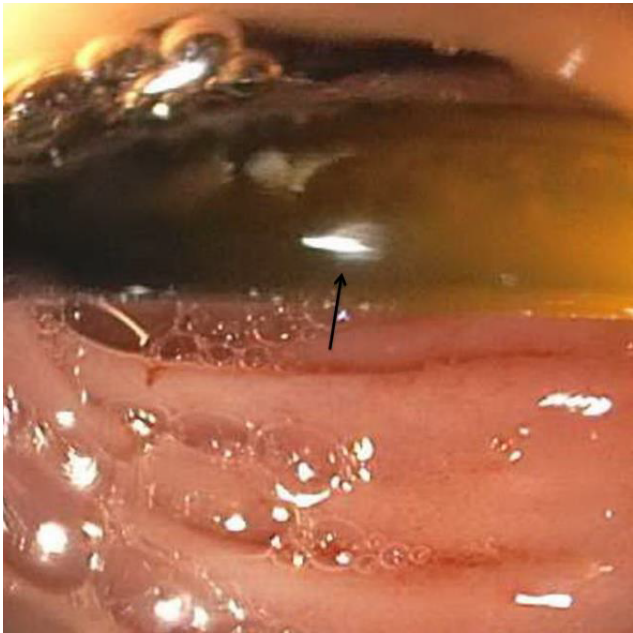


Figure 1. Migrated stent in the lumen

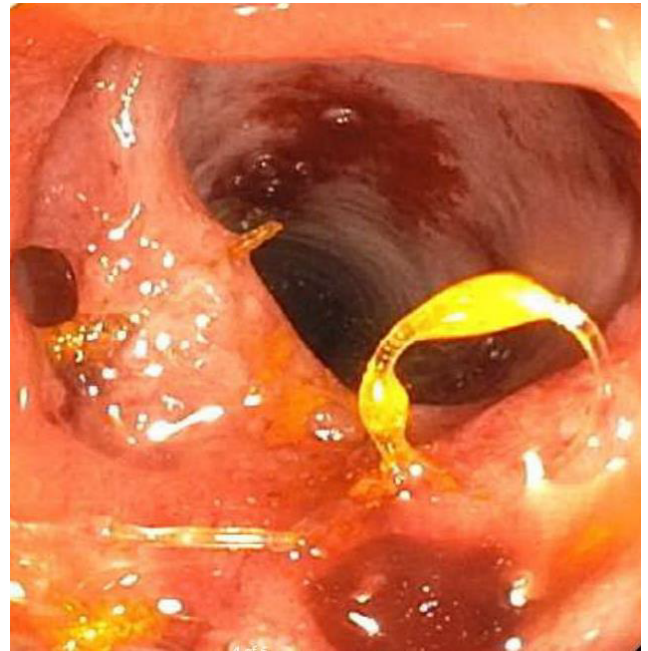

Figure 4. Stent Removed



Figure 2. Stent removed

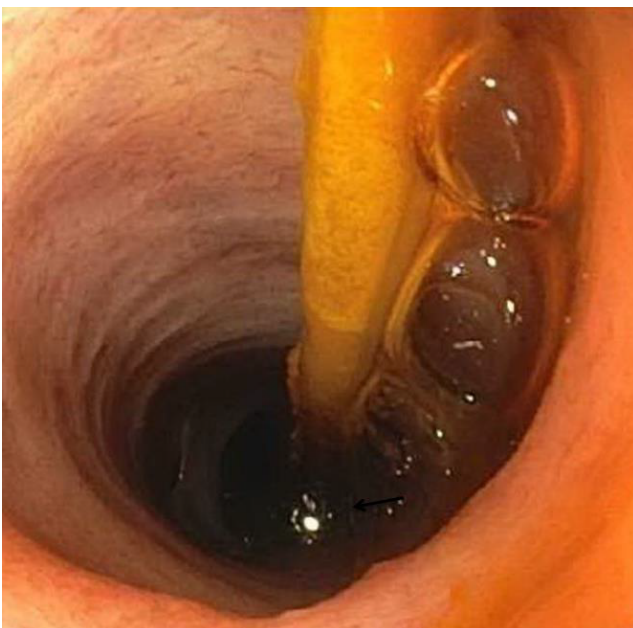

Figure 3. Migrated stent in bile duct

## DISCUSSION

Pylorus preserving pancreaticoduodenectomy (PPPD) is a smaller resection than classic Whipple procedure, as it preserves the stomach and pylorus. PPPD is associated with, reduced procedure time, less blood loss, and purported lower incidence of delayed gastric emptying. Intraoperatively placed prophylactic pancreatic stents across pancreatojejunostomy anastomosis prevent leakage of pancreatic enzymes which causes autolysis of normal tissue thus restricting the ability to heal the anastomosis and the surgical wound. Pancreatic fistula has been reported in 24% of post pancreaticoduodenectomy patients and can later lead to bleeding, abscess; sepsis and extended hospital stay and even death. Potential early complications from placement of the pancreatic stent include pancreatitis, ductal rupture and bleeding. Infection, bleeding, pancreatitis, intestinal obstruction, liver abscess and stent migration into biliary tree are among the late complications. Retrograde upper endoscopy is a safe and easy procedure to retrieve the migrated stent. We use pediatric colonoscope for endoscopic intervention in pancreatoduodenectomy patients as it allows easy and successful navigation of the 40-45 cm length of the afferent limb to reach the pancreatic and biliary anastomosis [1]. Rat-tooth forceps are easy to use and provide a distinct advantage of a secure grip while removing a small caliber foreign object like a pancreatic stent [4].

Thus a routine endoscopic procedure with a simple endoscopic accessory can help treat the rare and inadvertent complication of biliary stent migration post pancreaticoduodenectomy.

## CONCLUSION

These cases highlight the unusual complication of symptomatic spontaneous migration of pancreatic stent

into the biliary tree through the choledochojejunostomy site in post pancreaticoduodenectomy patients. The migrated stents can be safely and successfully retrieved with an upper endoscopy.

---

### Conflict of interest

The authors declare that they have no conflicts of interest concerning this article.

---

### References

1. Chahal P, Baron TH, Topazian MD et al. Endoscopic retrograde cholangiopancreatography in post-Whipple patients. *Endoscopy* 2006; 38: 1241-1245. [PMID: 17163326]

2. Tran KT, Smeenk HG, van Eijck CH, Kazemier G, Hop WC, Greve JW. et al. Pylorus preserving pancreaticoduodenectomy versus standard Whipple procedure: a prospective, randomized, multicenter analysis of 170 patients with pancreatic and periampullary tumors. *Ann Surg* 2004; 240:738-745. [PMID: 15492552]

3. Bawany MZ, Rafiq E, Thotakura R, McPhee MD, Nawras A. (2012). "Successful management of recurrent biliary colic caused by pancreatic stent migration after Whipple procedure." *J Interv Gastroenterol* 2(4): 205-206. [PMID: 23687612]

4. Rezvani M, O'Moore PV, Pezzi CM. Late pancreaticojejunostomy stent migration and hepatic abscess after Whipple procedure. *J Surg Educ* 2007; 64:220-3. [PMID: 17706575]

5. Tran KT, Smeenk HG, van Eijck CH, Kazemier G, Hop WC, Greve JW. et al. Pylorus preserving pancreaticoduodenectomy versus standard Whipple procedure: a prospective, randomized, multicenter analysis of 170 patients with pancreatic and periampullary tumors. *Ann Surg* 2004; 240:738-745. [PMID: 15492552]