



## Abdominal Compartment Syndrome in Pediatric Intensive Care: Two Case Report and Literature Review

Cecilia Bigio\*, Cesar Lemos

Department of Pediatric Intensive Care, University of Sao Paulo, State of Sao Paulo, Brazil

### ABSTRACT

The abdominal compartment syndrome affects critically ill patients under pediatric intensive care. It is characterized by abdominal hypertension with dysfunction of one or more organ systems. Unrestricted fluid resuscitation is one of the risk factors for its development. Early recognition of intra abdominal hypertension is necessary so that clinical or surgical measures can be taken in order to prevent the evolution to abdominal compartment syndrome and a subsequent irreversible multiple organ dysfunction syndrome. The aim of this study is to report two cases of abdominal compartment syndrome in an intensive care unit in a pediatric hospital, conduct a literature review on the subject and alert to the need to adopt internal routines to ensure early monitoring and approach to intra abdominal hypertension, before a multiple organ dysfunction syndrome sets in, thus aiming to reduce its morbidity and mortality. In the world literature, there is little information about the abdominal compartment syndrome in relation to the pediatric population. Thabet, et al. published a guideline for this population. Intra abdominal pressure should be routinely monitored in critically ill patients who have one or more risk factors for abdominal compartment syndrome. If intra abdominal hypertension is detected, intra abdominal pressure should be serially monitored. Early recognition of intra abdominal hypertension and prevention of abdominal compartment syndrome is the ideal treatment of abdominal compartment syndrome in pediatrics. Multicenter studies and quality projects in intensive care units are needed for its early recognition, monitoring and treatment, since it has high morbidity and mortality.

**Keywords:** Intra abdominal hypertension; Abdominal compartment syndrome; Pediatric intensive care; Early recognition; Morbidity and mortality

### INTRODUCTION

The Abdominal Compartment Syndrome (ACS) is a disease that affects severely ill patients. It is characterized by Intra Abdominal Hypertension (IAH) accompanied by dysfunction of one or more organ systems [1]. ACS progressively evolves into the Multiple Organ Dysfunction Syndrome (MODS),

sometimes irreversibly. According to some studies, IAH affects 15% to 45% of patients in Pediatric Intensive Care Units (PICU) report that ACS is diagnosed in 0,7% to 4,7% of the children treated in PICU [2]. Intra Abdominal Pressure (IAP) must be closely monitored to prevent ACS. Silva and Teles in a multicenter research, evaluated the knowledge and practices of intensive care physicians about ACS. 75% of interviewees

<b>Received:</b>	02-January-2023	<b>Manuscript No:</b>	IPJICC-23-12031
<b>Editor assigned:</b>	04-January-2023	<b>PreQC No:</b>	IPJICC-23-12031 (PQ)
<b>Reviewed:</b>	18-January-2023	<b>QC No:</b>	IPJICC-23-12031
<b>Revised:</b>	23-January-2023	<b>Manuscript No:</b>	IPJICC-23-12031 (R)
<b>Published:</b>	30-January-2023	<b>DOI:</b>	10.35248/2471-8505.23.9.001

**Corresponding author** Cecilia Bigio, Department of Pediatric Intensive Care, University of Sao Paulo, State of Sao Paulo, Brazil; E-mail: [cecbigio@gmail.com](mailto:cecbigio@gmail.com)

**Citation** Bigio C, Lemos C (2023) Abdominal Compartment Syndrome in Pediatric Intensive Care: Two Case Report and Literature Review. J Intensive Crit Care. 9:001.

**Copyright** © 2023 Bigio C, et al. This is an open-access article distributed under the terms of the Creative Commons Attribution License, which permits unrestricted use, distribution, and reproduction in any medium, provided the original author and source are credited.

knew the concept of ACS, but only 34% of them had measured the IAP [3]. In most cases, professionals did not measure the IAP because it was not a routine in the unit where they worked. In Germany, Otto, et al. demonstrated that 25% of intensivists did not measure IAP [4]. These works allude to the need to adopt internal routines and training to consolidate this measure in the Intensive Care Units (ICU). To try to change this scenario, in 2004 the World Society of the Abdominal Compartment Syndrome (WSACS) was created, which has been developing evidence based recommendations and consensus, with several publications on the subject [5].

### Objective

Due to the high morbidity and mortality of ACS, and as the chance of its reversal is directly related to the moment when IAP monitoring starts and the possible occurrence of IAH1 is detected, the aim of this study is to report two cases of ACS treated in the ICU of a pediatric hospital, with different outcomes, conduct a literature review on the subject and alert to the need to adopt internal routines to ensure early monitoring and approach to the IAH/ACS, before MODS occurs, thus aiming to reduce its morbidity and mortality. The detection of risk factors, as well as the installation of IAP monitoring measures, depend on the adoption of protocols in the PICUs and the adherence of physicians to them, as well as hospital management measures that ensure the continuous application of the implemented routines.

## LITERATURE REVIEW

On the PubMed the term “abdominal compartment syndrome” was searched with the filters “search field: Title” and “species: Human” and “ages: 0 month-18 years”. 103 articles dated between 1994 and 2021 were found. Of these, 10 were in more specific languages (Japanese, Russian, German, Chinese, and Turkish), 34 were in the adult population, 1 was a nursing article, and totaling 45 excluded articles, leaving 58 articles. Of the remaining 58 articles, 11 were excluded, as the patients were neonatal, 29 were case reports, adding up to a total of 40 further excluded articles, thus leaving 18 articles. Of the 18 selected pediatric articles, 7 articles were also excluded: 5 series of surgical patients with ACS in very specific populations, 2 studies on imaging findings in patients with ACS, thus leaving 11 articles. Of these, 2 articles were not found and 1 article did not contribute new data to the review, leaving 8 articles. The selected articles are described in **Table 1**. Other 586 abstracts and articles were also reviewed between 1989 and 2021 on the topic “abdominal compartment syndrome” with the filters “search field: Title” and “species: Human” in the general population, without age filter, in search of relevant data about the disease.

**Table 1:** Description of selected articles.

Selected article	Type	Reason for selection
Kirkpatrick, et al.	Guideline	Relevance of the type of study
Thabet, et al.	Review	
Carlotti, et al.	Review	
de Waele,	Review	
Divarci, et al.	Prospective study of the incidence of ACS	
Gottlieb, et al.	Pedagogical guidance text for clinical practice	Relevance of the type of study, considering that there is a shortage of publications on the subject in the pediatric population.
Steinau, et al.	Prospective study	
Pearson, et al.	Retrospective study of the incidence of ACS in surgical patients	

### Ethical Aspects

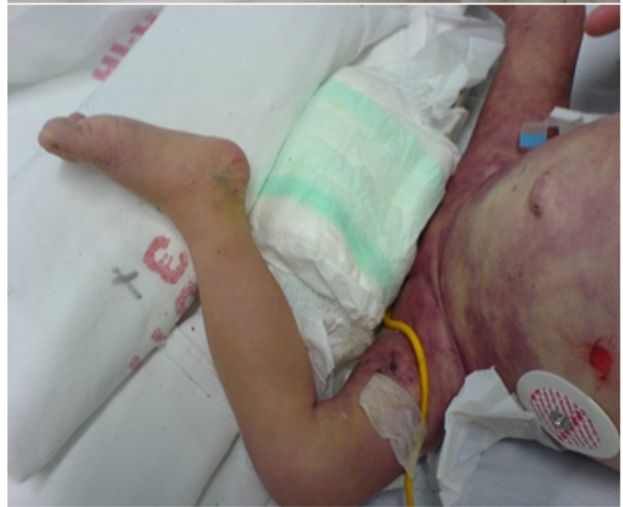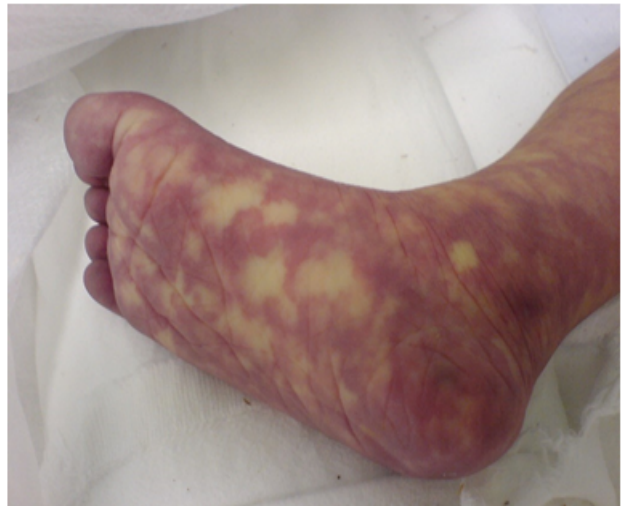This work is in accordance with the guidelines of the world medical association declaration of Helsinki. The patient's identity was protected, not allowing his/her identification.

### Clinical Case 1

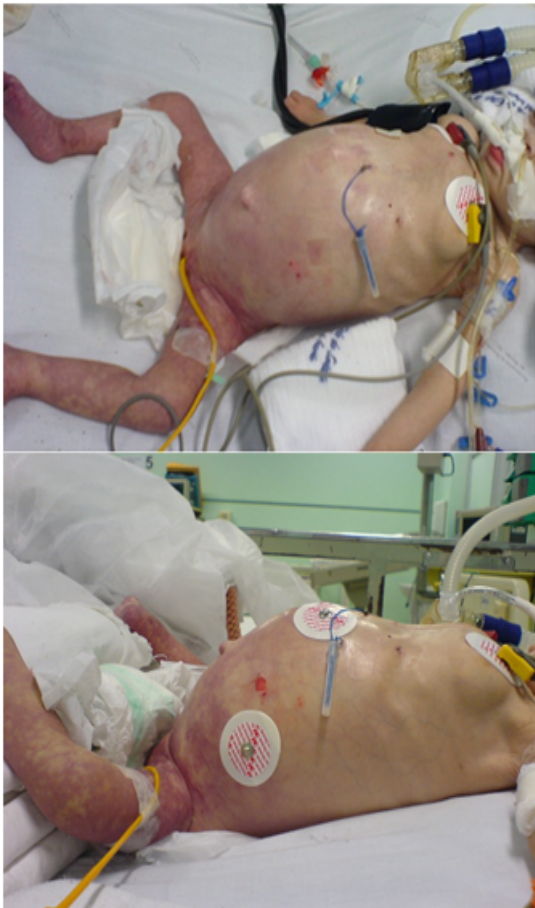A female infant with one year and 10 months of age, with down syndrome and rastelli type A Atrio Ventricular Septal Defect (AVSD) with right ventricular volume overload and pulmonary arterial hypertension. She was admitted to the PICU of a central pediatric hospital, coming from the PICU of a

regional hospital, with indication for follow up and surgical treatment with cardiology and cardiac surgery at the destination hospital. Upon admission to the central hospital, the diagnosis of sepsis was made. Treatment for sepsis including antibacterial and antifungal was instituted, after clinical stabilization. On the 11<sup>th</sup> day of admission to the central hospital, the patient underwent a total correction of AVSD with bovine pericardial patch. On the 14<sup>th</sup> postoperative day, she developed a diagnosis of endocarditis in the bovine pericardial patch and positive hemoculture for *Serratia marcescens*, starting specific antimicrobial treatment. On the

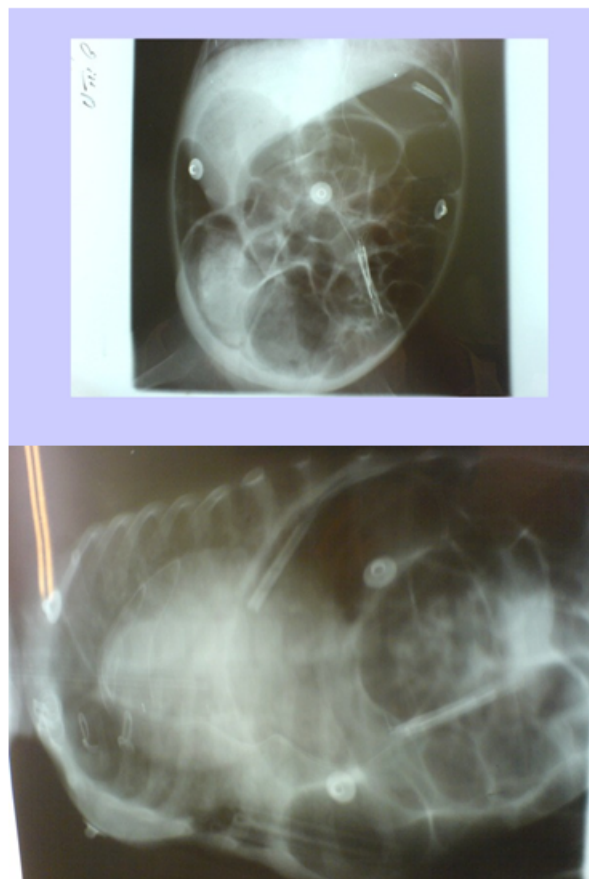28<sup>th</sup> postoperative day, a control echocardiogram was performed, which found persistence of endocarditis in the bovine pericardial patch. On the 29<sup>th</sup> postoperative day, with severe malnutrition and under clinical treatment, the patient evolved with reduced diuresis and respiratory failure, and had to return to mechanical ventilation. In 24 hours, received 225 ml/kg of weight of intravenous fluid 100 ml/kg of maintenance fluid, 35 ml/kg of enteral diet, a transfusion of 10 ml/kg of red blood cell concentrate and 80 ml/kg of volume expansion with saline solution 0, 9%. The patient evolved with abdominal distension with a tense, non-depressible abdomen and without noticeable peristalsis (**Figures 1 and 2**), lower limb temperature decrease, associated with livedo reticularis, which disappeared with the milking of the limb (**Figure 3**).



**Figure 2:** Livedo reticularis before and after limb milking.

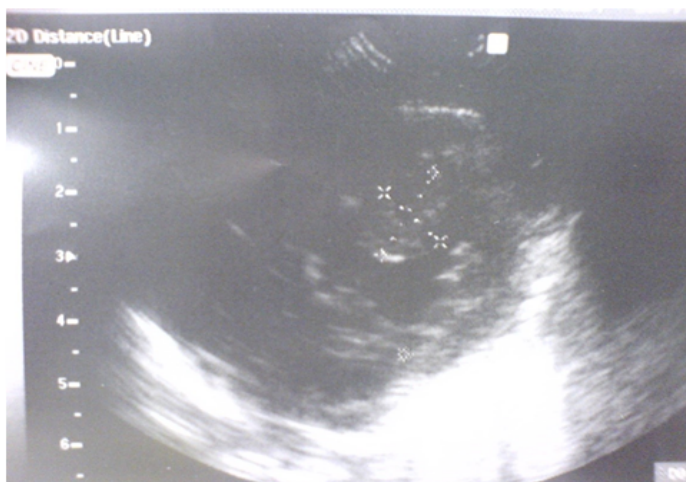


**Figure 1:** Abdominal distension with chest volume restriction top and side view.



**Figure 3:** Abdominal radiograph with distended bowel loops (anterior posterior view and in right lateral decubitus).

She also presented metabolic and respiratory acidosis, anuria, with increased urea and potassium, acute renal failure need to increase ventilator pressures and doses of vasoactive amines, characterizing a diagnostic of MODS. On this occasion, IAP was measured at 29 mmHg. The echocardiogram showed a large thrombus in the left ventricle (**Figure 4**). The child then underwent exploratory laparotomy eight hours after the onset of MODS, which revealed colon necrosis and small bowel distension. In the Trans operative period, she had a cardiorespiratory arrest and progressed to death.



**Figure 4:** Echocardiogram showing thrombus inside the left ventricle.

## Clinical Case 2

A female infant with one month and 28 days old, with cystic fibrosis and bile duct cyst, was transferred to the central pediatric hospital for follow up by gastroenterology, pulmonology and pediatric surgery. On the 26<sup>th</sup> day of hospitalization, she underwent bileo digestive bypass surgery. She evolved postoperatively with abdominal distension for 15 days, but with a depressible abdomen, not very painful, with normal bowel movements and receiving an enteral diet for her age. On the 16<sup>th</sup> postoperative day, she developed worsening of abdominal distension, still depressible, abdominal pain, tachypnea, light nasal flaring, and her diet was suspended. A maintenance intravenous hydration with 100% of the basic requirement was then installed, in addition to receiving 50 ml/kg of fluid replacement with 0.9% saline solution and 10 ml/kg of 12/12 h intravenous albumin, due to a clinical condition of liver failure and evidence of cirrhosis on abdominal ultrasound on the 10<sup>th</sup> postoperative day. On the 17<sup>th</sup> postoperative day, the abdominal distension worsened, becoming less depressible on palpation, and she developed respiratory failure due to restriction of the expansion of the rib cage. She also presented absence of peristalsis and bowel movements, oliguria (0.5 ml/kg/h in the first six hours of the day) and anuria (absence of diuresis in the following six hours), livedo reticularis in the lower limbs that improved with hand massage (venous stasis), mixed acidosis and hypoxemia (arterial blood gas with pH of 7.26; pCO<sub>2</sub> of 39.6 mmHg, pO<sub>2</sub> of 61 mmHg; bicarbonate of 18.3 mEq/L; excess base of 7.6 and SaO<sub>2</sub> 87.4%). She evolved in a few hours to respiratory failure, requiring or tracheal intubation and mechanical ventilation with inspiratory pressure: 25, expiratory pressure: 10, cycling frequency: 30 cpm and inspired oxygen fraction: 100%, with a maximum capillary oximetry of 90% after being adapted to these parameters. The chest X-ray showed little chest expansion with straightening of the ribs, significant abdominal distension, with hypo transparency of the abdomen. At this moment, the IAP was measured, which was at 38 mmHg with a blood pressure of 72/38 mmHg. Abdominal ultrasonography performed afterwards showed voluminous ascites. An ultrasound guided paracentesis was then performed with immediate drainage of 780 ml of xanthochroid fluid. After paracentesis, heart rate decreased from 160 to 130 bpm, SaO<sub>2</sub> went from 90 to 100%, allowing the reduction of mechanical ventilation parameters of expiratory pressure from 10 to three, inspiratory pressure from 25 to 15, cycling frequency of 30 to 25 cpm and inspired fraction of oxygen from 100% to 40%. Then, the patient was placed in positive pressure with continuous flow (CPAP) tracheal intra abdominal pressure. Decreased from 38 to seven mmHg, the lower limbs returned to normal and urinated 55 ml in the first three hours after decompression (3.2 ml/kg/h). Blood pressure increased to 98/45 mmHg.

## RESULTS

IAP was first mentioned by Marey, who suggested that inspiration exerted over intra abdominal pressure an inverse effect of what it produced on the chest. Monitoring of the IAP was first performed in 1865 by Braune in Germany, *via* the rectal route. The term abdominal compartment syndrome was first used in the world medical literature in 1989 by in four patients with ruptured abdominal aortic aneurysms at William Beaumont hospital in Royal Oak, Michigan. The syndrome occurred after surgical repair in patients who received more than 25 liters of fluid resuscitation and was characterized by the need for increased ventilator pressure, associated with increased central venous pressure, reduced urinary flow and massive abdominal distension. Until the mid 1990's, ACS was little studied, which was changed after the publication of two reviews on the subject, Scheim, et al. Burch, et al. Since then, IAH and ACS have been recognized in a large number of clinical and surgical, abdominal and extra abdominal, traumatic and non-traumatic pathologies, and several complications and consequences have been described [6-12]. The most affected organ systems in ACS are hemodynamic, cardiovascular, pulmonary, renal, neurological and intestinal. It was from the years 2006/2007 that the theme of the IAH/ACS was inserted more frequently in medical practice. According to Thabet, et al. medical interest in IAH has become more evident in the last 13 years. According to Ivatury's report until the end of the 1980's, we knew the method of measuring the IAP, the damage caused by the IAH and the forms of treatment. The clinical syndrome was also defined and named. But only after a few years, the concept penetrated our surgical minds" translation of the original text. This report clearly demonstrates dissociation between theoretical knowledge

and its practical applications in hospital medical routines. In 2017, Thabet, et al. published the first review of ACS in pediatrics with well-defined guidelines, based on international conferences on the topic, the WSACS guidelines and 44 pediatric studies published since 2000. Thus, for the first time, some criteria and parameters directed to IAH and ACS in pediatrics were established in a guideline and some risk factors for the development of IAH and ACS in the pediatric population were defined (Table 2) [13]. The multiple organ dysfunction syndrome, one of the possible evolutions of ACS, can occur in critically ill children, hospitalized in an intensive care unit, with IAP measurements much lower than in adults (10-15 mmHg) and at a faster rate [14]. Therefore, IAP should be routinely monitored in critically ill patients who present one or more risk factors for ACS. Early recognition of IAH and prevention of ACS is the ideal treatment for ACS in pediatrics, due to the high mortality rate described after the installation of ACS [15]. Normal IAP in spontaneously breathing children is zero mmHg and mechanical ventilation is seven  $\pm$  three mmHg, regardless of the child's body weight. Thus, pediatric IAH was defined as a sustained increase in IAP  $>10$  mmHg and ACS as dysfunction or worsening of a preexisting dysfunction of at least one organ or system that can be attributed to high IAP. In a prospective study in a pediatric and neonatal intensive care unit carried out by Divarci, et al. between 2009 and 2010, the main organ dysfunctions found were: Metabolic acidosis refractory to shock treatment measures, oliguria refractory to volume infusion, need for high pressure in mechanical ventilation, hypercapnia refractory to increased parameters in mechanical ventilation, hypoxemia refractory to increased PEEP and FiO<sub>2</sub>, intracranial hypertension [16].

**Table 2:** Identified risk factors.

---

### Reducing abdominal compliance

---

Due to acute respiratory failure with high intrathoracic pressures, trauma or extensive burns, circumferential third degree burn in the abdominal wall, prone position with head elevation  $>30^\circ$ , obesity gastroschisis, omphalocele, diaphragmatic hernia or abdominal surgery with tension closure.

#### The increased intraluminal content

Due to gastroparesis, intussusception, adynamic ileus, colonic pseudo-obstruction, constipation or hirschsprung's disease

#### Increased intra abdominal content

Due to abdominal trauma, kidney, liver, bowel transplantation, extracorporeal circulation membrane, hemoperitoneum, pneumoperitoneum, pancreatitis, liver dysfunction with ascites, splenomegaly, hepatomegaly, intra abdominal tumors, bleeding in retroperitoneum, peritonitis or enterocolitis

#### Capillary leakage with fluid resuscitation

Related to septic shock, cardiogenic, to toxic shock syndrome, to shock from trauma, to heart transplant rejection, to acidosis with pH  $<7.2$ , hypotension, hypothermia, polytransfusion, coagulopathy, pancreatitis, oliguria, sepsis, trauma and severe burns, laparotomy for injury control or Systemic inflammatory response syndrome

#### Others:

Prism score  $\geq$  or equal to 17, hypothermia, high lactate, fetal hydrops, heart transplant rejection, and capillary leakage after liver or kidney transplantation

---

More contemporary theories have suggested that a vicious cycle of bowel ischemia and reperfusion processes in critically ill children is an important factor in the pathophysiology of ACS. Studies show that pediatric patients who were severely burned and in various situations of shock have bowel inflammation induced by fluid resuscitation. There is, therefore, an increase in membrane permeability, with accumulation of fluid in the lumen of the intestines, in the interstitium and/or in the abdominal cavity, resulting in IAH and consequent lymphatic compression, increased edema and reduced perfusion, with intestinal ischemia. This ischemia leads to an increase in the already high membrane permeability, with the release of inflammatory mediators, with an increase in edema and IAP [17]. Excessive fluid resuscitation is therefore an important cause of ACS in critically ill children. Two authors suggested the correlation of aggressive fluid resuscitation as a predisposing factor for the development of ACS in the pediatric population in studies with a small number of patients [18,19]. A high level of suspicion of ACS is recommended in critically ill patients when large volume resuscitation is required. The increase in IAP is harmful to several organic systems, such as the cardiovascular, respiratory, and renal, among others. According to the increase in IAP leads to a reduction in venous return through the vena cava due to its compression and narrowing. These effects result in decreased cardiac preload. The IAH also displaces the diaphragm upwards, with a consequent increase in intrathoracic pressure, impairing cardiac contractility and resulting in lung compression, increased airway pressure, with a reduction in total lung capacity. Decreased oxygen delivery and cardiac output result in tissue hypoxia and renal failure. The pathophysiology of renal dysfunction is explained by several mechanisms, such as reduced cardiac output, increased renal venous pressure and increased renal parenchyma pressure. If the IAH is detected, the IAP must then be monitored in a serial manner. Divarci, et al. propose that once ACS is suspected, the IAP and investigation of organ and system dysfunction be made and that it proceed as follows: If the IAP is normal and there are no criteria for ACS, the IAP measurement should be repeated every 24 hours. If there is only IAH without ACS, follow with clinical measures to reduce the pressure of the abdomen and measurement of the IAP every six to eight hours. If there is already ACS, perform decompressed laparotomy. The urethral route is considered the preferred indirect route for measuring IAP in this population, since the intraperitoneal route has an increased risk of peritonitis and intestinal perforation. IAP should be measured with the patient in the expiratory phase, properly sedated and with neuromuscular blockade of their respiratory muscles. The measurement is taken after the rapid infusion, with a syringe, of one ml/kg of weight of distilled water in the urine collection system. In newborns and children, this measure of one ml/kg of weight is used, with a minimum of three ml and a maximum of 25 ml to be instilled at a time. The current pediatric consensus of the WSACS indicates regular IAP measurements every four hours as soon as the IAH diagnosis is obtained and recommends several clinical measures before surgical decompression if the patient does not have ACS. Clinical measures include pain and anxiety

control, neuromuscular blockade, nasogastric tube, rectal enemas, negative fluid balance, peritoneal dialysis for fluid removal, infusion of colloid solutions associated with loop diuretic, paracentesis and ultrafiltration [20]. The aim of clinical treatment is to prevent progression to ACS and subsequent MODS. Pearson et al recommend laparoscopic decompression in any child with lactate greater than 3 mg/dL, persistent oliguria, elevated ventilators pressures, increasing vasopressor score, and bladder pressure greater than 20 mmHg in patients with ACS. The mortality of ACS varies between 16 and 100% in critically ill children in several studies.

## DISCUSSION

In both cases reported above, a measurement system coupled to the intravesical tube was used to measure the IAP, after the instillation of 20 ml of 0.9% saline solution into the urinary catheter, regardless of the patients weight. Both cases evolved with a severe increase in IAP after large volume resuscitation, a risk factor associated with the pathophysiology of IAH/ACS in the current consensus. The first case reported presented a picture of significant chronic malnutrition, sepsis of recent hospital origin and endocarditis in the cardiac prosthesis, that is, it presented a high risk for serious complications. With such complex comorbidities and significant clinical instability, the patient was in very unfavorable conditions for the surgical approach; however, abdominal decompression was mandatory. In 2006, three cases of pediatric patients with complex congenital heart disease, using ECMO or not, who presented sepsis by a gram-negative germ or candida identified in a blood sample that evolved with mesenteric ischemia and ACS was reported. In 2015, an observational retrospective cohort study concluded that acute mesenteric ischemia that occurs in the postoperative period of cardiac surgery is directly related to a greater increase in IAP and, consequently, to ACS. This study states that an earlier approach with the maintenance of the abdomen open can lead to a reduction in mortality in these cases. The second case reported occurred in the same unit, with a patient with less complex comorbidities and clinical picture, and the ACS reversal occurred immediately after the IAP measurement, with verification of the IAH and emptying of the abdominal contents. The patient had a severe IAH, and ACS, but did not have irreversible MODS. According to de Waele, et al. monitoring IAP at the first sign of organ dysfunction is important, especially in pediatrics. Pearson, et al. in a prospective study of 264 patients who underwent exploratory laparotomy at a tertiary pediatric center, demonstrated that there is a significant relationship between mortality and bladder pressure. The mean bladder pressure of the study patients who died was 29.3 mmHg compared to 18.5 mmHg in those who survived. There is a shortage of articles on ACS in pediatric patients even today. Between 2007 and 2021, 70 articles were published on ACS in a pediatric population. Of these articles, 30 were case reports of the 10 reviews present, only three were about ACS in clinical and surgical children. The other studies are clinical studies, comparative studies, observational studies and

others. In 2015, conducted a multicenter study in PICU. The main findings of this study are the high prevalence of IAH in newly admitted critical pediatric patients, the independent association of IAH with hypothermia and high lactate levels. In this context, quality comparative multicenter studies with a high number of patients could provide improvements in the management of IAH and ACS, aiming to reduce their morbidity and mortality. Mortality from ACS remains high (50% to 60%) even after early surgical decompression, which increases the importance of detecting and treating IAH before organic damage occurs. With the adoption of the measures listed above, it becomes possible to be more effective in the detection and early monitoring of IAH, as well as the prevention of ACS and its evolution to irreversible MODS, thus contributing to the reduction of its morbidity and mortality.

## CONCLUSION

Publications and studies on ACS in the pediatric population are scarce to date. There are no studies with large samples in this population on this topic. Recognition, monitoring and early, effective and more frequent treatment of AIH and ACS are essential to avoid an evolution to irreversible MODS. More studies are still needed to analyze which measures would have an impact on reducing case mortality and morbidity.

## ACKNOWLEDGEMENTS

None

## REFERENCES

- Deindl P, Wagner J, Herden U, Schulz Jurgensen S, Schild R, et al. (2019) Monitoring intra abdominal pressure after liver transplantation in children. *Pediatr Transplant.* 23(7):1–7.
- Silva JPL, Teles F (2012) Assessment of intensivists knowledge on abdominal compartment syndrome. *Rev Bras Anesthesiol.* 62(4):531-537.
- Otto J, Kaemmer D, Binnebosel M, Jansen M, Dembinski R, et al. (2009) Direct intra abdominal pressure monitoring *via* piezo resistive pressure measurement: A technical note. *BMC Surg.* 9(1):1-5.
- Steinau G, Kaussen T, Bolten B, Sarchtrupp A, Neumann UP, et al. (2010) Abdominal Compartment Syndrome in Childhood: Diagnostics, therapy and survival rate. *Pediatr Surg Int.* 27(4):399-405.
- Ivatury R (2006) *Abdominal Compartment Syndrome.* 1<sup>st</sup> ed. CRC Press. Florida, United States.
- Fietsam RJr, Villalba M, Glover JL, Clark K (1989) Intra abdominal compartment syndrome as a complication of ruptured abdominal aortic aneurysm repair. *Am Surg.* 55(6):396-402.
- Schein M, Wittmann DH, Aprahamian CC, Condon RE (1995) The abdominal compartment syndrome: the physiological and clinical consequences of elevated intra-abdominal pressure. *Review J Am Coll Surg.* 180(6): 745-53.
- Burch JM, Moore EE, Moore FA, Franciose R (1996) The Abdominal Compartment Syndrome. *Surg Clin North Am.* 76(4):833-842.
- Pereira B (2019) Abdominal Compartment Syndrome and intra-abdominal hypertension. *Curr Opin Crit Care.* 25(6): 688-696.
- Ivatury RR, Diebel L, Porter JM, Simon RJ (1997) Intra abdominal Hypertension and the Abdominal Compartment Syndrome. *Surg Clin North Am.* 77(4): 783-800.
- Thabet FC, Ejike JC (2017) Intra abdominal hypertension and abdominal compartment syndrome in pediatrics. *J Crit Care.* 47(3):275-282.
- Pearson EG, Rollins MD, Vogler SA, Mills MK, Lehman EL, et al. (2010). De compressive laparotomy for abdominal compartment syndrome in children: before it is too late. *Comparative Study J Pediatr Surg.* 45(6):1324-1329.
- de Waele JJ, Ejike JC, Leppaniemi A, de Keulenaer BL, de Laet I, et al. (2015) Intra abdominal hypertension and abdominal compartment syndrome in pancreatitis, paediatrics, and trauma. *Anaesthesiol Intensive Ther.* 47(3):219-227.
- Divarci E, Karapinar B, Yalaz M, Ergun O, Celik A (2014) Incidence and prognosis of intra abdominal hypertension and abdominal compartment syndrome in children. *Observational Study J Pediatr Surg.* 51(3):503-507.
- Carlotti AP, Carvalho WB (2009) Abdominal compartment syndrome: A review. *Pediatr Crit Care Med.* 10(1): 115-120.
- Oda J, Yamashita K, Inoue T, Ode NHY, Mega K, et al. (2006) Resuscitation fluid volume and abdominal compartment syndrome in patients with major burns. *Burns.* 32(2):151-154.
- Rodas EB, Malhotra AK, Chhitwal R, Aboutanos MB, Duane TM, et al. (2005). Hyper acute abdominal compartment syndrome: an unrecognized complication of massive intraoperative resuscitation for extra-abdominal injuries. *Am Surg.* 71(11):977-981.
- Kirkpatrick AW, Roberts DJ, de Waele J, Jaeschke R, Malbrain ML, et al. (2013) Intra abdominal hypertension and the abdominal compartment syndrome: Updated consensus definitions and clinical practice guidelines from the World Society of the Abdominal Compartment Syndrome. *Intensive Care Med.* 39(7):1190-1206.