

Ruptured Thin-Cap Fibroatheroma as Cause of Recurrent Stemi and Malignant Arrhythmias

Luis Ortega-Paz,
Guiseppe Giacchi,
Salvatore Brugaletta,
Kohki Ishida and
Manel Sabaté

Keywords: Myocardial infarction; Fibroatheromatous Plaque; Stents; Optical coherence tomography

Abbreviations: PCI: Percutaneous Coronary Intervention; RCA: Right Coronary Artery; BMS: Bare Metal Stent; TIMI: Thrombolysis In Myocardial Infarction; OCT: Optical Coherency Tomography; TCFA: Thin-Cap Fibroatheroma

Received: September 15, 2015; **Accepted:** September 18, 2015; **Published:** September 21, 2015

86 years-old man with a previous PCI, was admitted to a hub hospital for an inferior STEMI and ventricular tachycardia. Coronary angiography showed stent thrombosis on distal segment of right coronary artery (RCA), which was treated by intracoronary adenosine and bare metal stent (BMS) implantation with restored TIMI 3 flow (**Figure 1A**). The patient remained stable and asymptomatic for 17 hours, then he began again with recurrent episodes of ventricular tachycardia with hemodynamic instability, and re-elevation of ST-segment in inferior leads in a 12-lead ECG. Patient was transferred to our catheterization laboratory: coronary angiography showed a non-occlusive thrombus image without angiographic evidence of stenotic plaque in the middle segment of RCA with preserved TIMI 3 flow (**Figure 1B and 1C**). Optical coherence tomography (OCT) was then performed, highlighting a ruptured thin-cap fibroatheroma (TCFA) with thrombus superimposed (**Figure 1D-1G**). A BMS was implanted, with restored TIMI 3 flow. After the procedure the patient was asymptomatic without ventricular arrhythmias until discharge. Plaque rupture is the most common cause of acute myocardial infarction: vulnerable plaques prone to rupture are usually characterized by a large necrotic core and a thin fibrous cap [1]. This case shows how a ruptured TCFA may be responsible of recurrent STEMI with malignant arrhythmias. Implantation of metallic or polymeric device may be useful to stabilize the plaque, and prevent new or recurrent ischemic and arrhythmic episodes [2,3].

Department of Cardiology, Thorax Institute, Hospital Clínic, Biomedical Investigation Institute, IDIBAPS, University of Barcelona, Spain

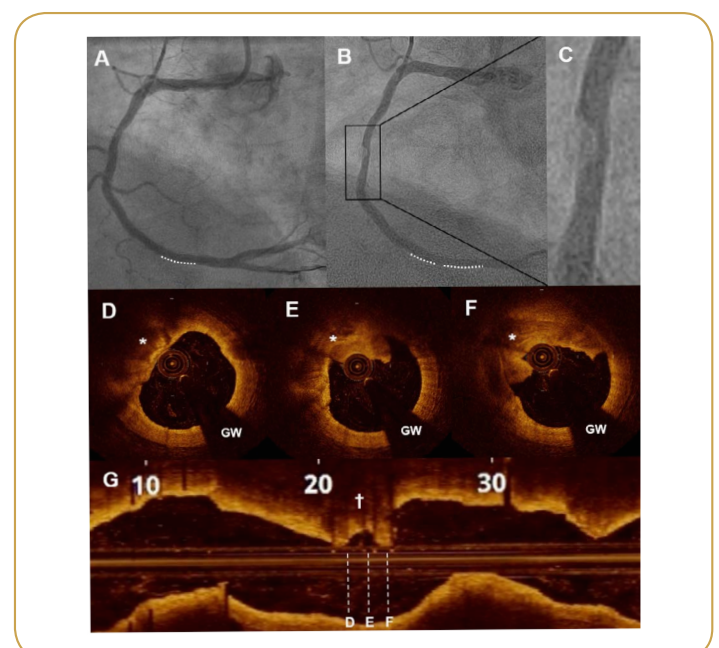
Corresponding author: Salvatore Brugaletta

✉ sabrugetta@gmail.com

MD, PhD. Cardiology Department, Thorax Institute, IDIBAPS, University of Barcelona. Hospital Clinic, c/Villarroel 170, 08036 Barcelona, Spain.

Tel: 514 343 6973

Citation: Ortega-Paz L, Giacchi G, Brugaletta S, et al. Ruptured Thin-Cap Fibroatheroma as Cause of Recurrent Stemi and Malignant Arrhythmias. *Interv Cardiol J* 2015, 1:1.



References

- 1 Falk E, Nakano M, Bentzon JF, Finn AV, Virmani R (2013) Update on acute coronary syndromes: the pathologists' view. *European heart journal* 34: 719-728.
- 2 Wykrzykowska JJ, Diletti R, Gutierrez-Chico JL, van Geuns RJ, van der Giessen WJ, et al. (2012) Plaque sealing and passivation with a mechanical self-expanding low outward force nitinol vShield device for the treatment of IVUS and OCT-derived thin cap fibroatheromas (TCFAs) in native coronary arteries: report of the pilot study vShield Evaluated at Cardiac hospital in Rotterdam for Investigation and Treatment of TCFA (SECRITT). *EuroIntervention : journal of EuroPCR in collaboration with the Working Group on Interventional Cardiology of the European Society of Cardiology* 8: 945-954.
- 3 Tomey MI, Narula J, Kovacic JC (2014) Advances in the understanding of plaque composition and treatment options: year in review. *J Am Coll Cardiol* 63: 1604-16.