

DOI: 10.21767/2471-8157.100050

New Mechanisms of Atrial Fibrillation

Guy Hugues Fontaine*

Groupe Hospitalier Pitié-Salpêtrière, Paris, UK

Corresponding author: Guy Hugues Fontaine, Groupe Hospitalier Pitié-Salpêtrière, Paris, UK, Tel: +33 1 42 16 00 00; E-mail: guy.fontaine2@numericable.fr

Rec Date: Feb 06, 2017, **Acc Date:** Feb 12, 2017, **Pub Date:** Feb 14, 2017

Citation: Fontaine GH. New Mechanisms of Atrial Fibrillation. Interv Cardiol J 2017, 3:1.

Short Communication

Atrial fibrillation is the most common arrhythmia in human. It is a cause of mortality and morbidity leading to one of the most important expenditure in the modern world. Especially, it is increasing even further because of prolongation of life due to the advances of medicine. A group from Paris has attempted to demonstrate a link between fat in the epicardium of atrial tissue to the production of fibrosis as a possible mechanism of atrial fibrillation (AF) [1]. In their discussion and conclusion, the authors admit that the mechanism of AF is not completely understood. After an excellent review of the CMR techniques available for the identification of fat, fibrosis, and water in the heart, they note a lack of spatial resolution of modern imaging techniques that result in their performing ex vivo CMR on two hearts. However, the modern digital microscope has an optimal resolution which could enable a more precise interpretation of the pathophysiology of AF.

The knowledge accumulated from my study of the histology of ARVD of the right ventricle from 73 patients clearly shows the topographic structure of fat, fibrosis, and possible superimposed myocarditis. The atrial structure of the so-called "normal heart" is similar to that observed on the free wall of the right ventricle in ARVD. In addition to epicardial fat, there is fibrosis of two forms, interstitial fibrosis which can be the result of the genetic disorder of the disease or, replacement fibrosis which may be the result of myocarditis generally starting from the epicardium (epicardial-myocarditis as it is known by clinicians) (Figures 1 and 2). A superimposed myocarditis may have a spectrum of presentation from the fulminant form leading to acute heart failure and death in a few days associated with invasion of both ventricles and atria by lymphocytes to that of a completely healed hyaline fibrosis. There may be intermediate aspects of myocarditis with a variable number of clusters of lymphocytes inside strands of fibrosis called the chronic-active form [2]. Also, there may be a genetic factor now considered to be of increasing importance in the understanding of ventricular cardiomyopathies [3,4]. In the background of atrial fibrillation [5] these cardiomyopathies can be present but quiescent without arrhythmias in the general population [6]. There can be additional complexity if we consider that myocarditis alone can cause fibrosis and adipocytes [2]. Therefore, myocarditis can produce an arrhythmogenic substrate. In addition, the acute form can be a

trigger of arrhythmias associated with an increase of CRP [7]. The same gene that is responsible for the problem in atrial development can also explain the increased susceptibility of these hearts [8] to be affected by myocarditis in a single or in multiple episodes by enterovirus and adenoviruses [9,10]. Therefore, the prevention or treatment of lone atrial fibrillation may be due to two targets: protection against and/or suppression of viruses [11], and prevention of fibrosis [12]. In the future, the ideal approach to prevention of atrial fibrillation will be the modification of the human genome using the genetic approaches such as the CRISPR-Cas9 [13]. Finally, the results obtained in the treatment of atrial fibrillation may be expanded to the treatment of the whole heart since the atrium and ventricle are two parts of the same embryologic structure as has been recently confirmed by the finding of "atrial dysplasia" [14]. A simple new tool to evaluate patients at risk of atrial fibrillation and to follow the effect of treatment should be the use of the new 16 lead High Definition ECG recorder [6].

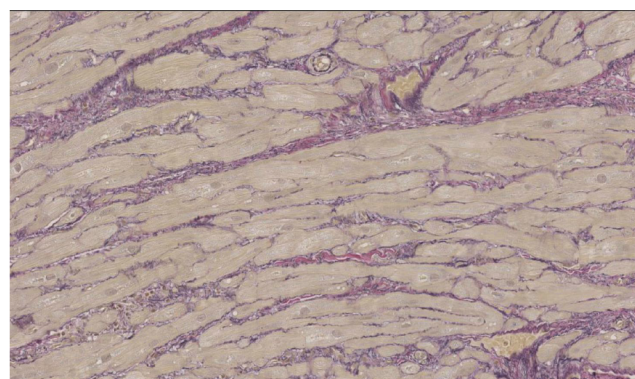


Figure 1 Interstitial fibrosis in atrial tissue (Elastic Van Gieson 120X).

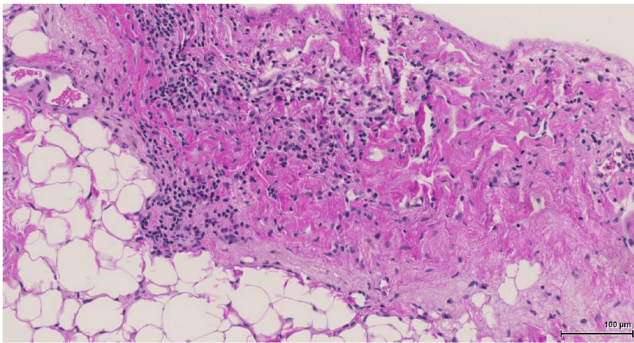


Figure 2 Replacement fibrosis with lymphocytes and adipocytes (H&E 120X).

References

1. Hatem SN, Redheuil A, Gandjbakhch E (2016) Cardiac adipose tissue and atrial fibrillation: the perils of adiposity. *Cardiovasc Res* 109: 502-529.
2. Cihakova D (2011) Myocarditis, In Tech Publications, EU.
3. Fressart V, Duthoit G, Donal E, Probst V, Deharo JC, et al. (2010) Desmosomal gene analysis in arrhythmogenic right ventricular dysplasia/cardiomyopathy: Spectrum of mutations and clinical impact in practice. *Europace* 12: 861-868.
4. Fontaine G, Fornes P, Fontaliran F (2001) Myocarditis as a cause of sudden death. *Circulation* 103: e12.
5. Lubitz SA, Yin X, Lin H, Kolek M, Smith GJ, et al. (2016) Genetic risk prediction of atrial fibrillation. *Circulation*.
6. Fontaine G, Chen HS (2014) Arrhythmogenic right ventricular dysplasia back in force. *Am J Cardiol* 113: 1735-1739.
7. Bonny A, Lellouche N, Ditah I, Hidden-Lucet F, Yitemben MT, et al. (2010) C-reactive protein in arrhythmogenic right ventricular dysplasia/cardiomyopathy and relationship with ventricular tachycardia. *Cardiol Res Pract* 24: 919783.
8. Lopez-Ayala JM, Pastor-Quirante F, Gonzalez-Carrillo J, Lopez-Cuenca D, Sanchez-Munoz JJ, et al. (2015) Genetics of myocarditis in arrhythmogenic right ventricular dysplasia. *Heart Rhythm* 12: 766-773.
9. Bowles NE, Ni J, Marcus F, Towbin JA (2002) The detection of cardiotropic viruses in the myocardium of patients with arrhythmogenic right ventricular dysplasia/cardiomyopathy. *J Am Coll Cardiol* 39: 892-895.
10. Gesualdo M, Scicchitano P, Carbonara S, Ricci G, Principi M, et al. (2016) The association between cardiac and gastrointestinal disorders: Causal or casual link? *J Cardiovasc Med (Hagerstown)* 17: 330-338.
11. Schultheiss HP, Piper C, Sowade O, Waagstein F, Kapp JF, et al. (2016) Betaferon in chronic viral cardiomyopathy (BICC) trial: Effects of interferon- β treatment in patients with chronic viral cardiomyopathy. *Clin Res Cardiol* 105: 763-773.
12. Lin CM, Chang H, Wang BW, Shyu KG (2016) Suppressive effect of epigallocatechin-3-O-gallate on endoglin molecular regulation in myocardial fibrosis in vitro and in vivo. *J Cell Mol Med* 20: 2045-2055.
13. Charpentier E, Doudna JA (2013) Biotechnology: Rewriting a genome. *Nature* 495: 50-51.
14. Fontaine G, Andreoletti L, Redheuil A, Gandjbakhch E, Frank R (2016) Epsilon wave on a loop recorder in a patient with myocarditis. *Europace*.