

DOI: 10.21767/2248-9215.100051

## Catastrophic Sudden Cardiac Death. Are there Lessons to be Learnt?

Dhiraj Kumar<sup>1\*</sup>, Girish Sabnis<sup>1</sup>, Dheeraj More<sup>1</sup>, Hetan Shah<sup>1</sup>, Charan Lanjewar<sup>1</sup>, Prafulla Kerkar<sup>1</sup>, Rohit Shrivastav<sup>2</sup> and Pradeep Vaideeshwar<sup>3</sup>

<sup>1</sup>Department of Cardiology, Seth GS Medical College and KEM Hospital, Mumbai, India

<sup>2</sup>Department of Internal Medicine, Seth GS Medical College and KEM Hospital, Mumbai, India

<sup>3</sup>Department of Pathology, Seth GS Medical College and KEM Hospital, Mumbai, India

\*Corresponding author: Dhiraj Kumar, Department of Cardiology, Seth GS Medical College and KEM Hospital, Mumbai, India, Tel: + 91-9323361116; E-mail: dhiraj1645@gmail.com

Received date: March 15, 2018; Accepted date: March 26, 2018; Published date: April 06, 2018

Copyright: © 2018 Kumar D, et al. This is an open-access article distributed under the terms of the Creative Commons Attribution License, which permits unrestricted use, distribution, and reproduction in any medium, provided the original author and source are credited.

Citation: Kumar D, Shrivastav R, Sabnis G, More D, Shah H, et al. (2018) Catastrophic Sudden Cardiac Death. Are there Lessons to be Learnt? Eur Exp Biol Vol. 8 No. 2:10.

### Abstract

**Background:** Sudden cardiac death is a catastrophic event which leads to loss of young and middle-aged population with dire consequences. Sometimes, a careful history, physical examination and most importantly electrocardiogram (ECG) can help in suspecting the common causes in young population like underlying channelopathies and cardiomyopathies which can further be diagnosed using echocardiography, cardiac MRI and in some cases genetic tests.

**Case summary:** A 33-year-old male presented with syncope and ventricular tachycardia leading to death. This patient was diagnosed to have Arrhythmogenic right ventricular dysplasia (ARVD) on post mortem pathological examination with features of fatty infiltration and thinning of right ventricular myocardium. Furthermore, on histologically fatty infiltration with inflammatory infiltrates were visualized.

**Discussion:** Clinical awareness amongst physicians about cardiomyopathies especially ARVD with its subtle yet suggestive ECG changes is the need of the hour. ARVD is a rare disease and can be diagnosed with certainty by analyzing ECG and adding imaging to it. When diagnosed cases are treated appropriately, at least a few cases of sudden cardiac death can be averted.

**Keywords:** Sudden cardiac death; Arrhythmogenic right ventricular dysplasia; Fatty infiltration; Case report

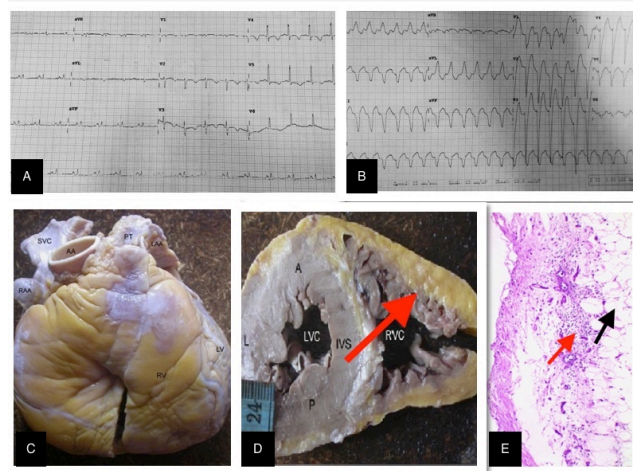
### Introduction

Sudden cardiac death describes an unexpected natural death from a cardiac cause within a short time period, generally  $\leq$  1 hour from the onset of symptoms, in a person without any prior condition that would appear fatal [1]. Although labelled so it is not always that it happens without warning signs and symptoms. We describe a case which exemplifies how such catastrophe if

not identified in time, can occur with refractory symptoms. Most of the times a simple history, clinical examination and a 12 lead ECG is enough to establish a diagnosis [2]. It is also important to be clinically aware of cardiomyopathies. If a timely diagnosis is made, then appropriate management can be instituted, and catastrophe can be prevented.

### Clinical Presentation

A 33-year-old farmer while working in his field had a syncope and was brought to the Emergency Room (ER). On examination patient had tachycardia and was in cardiogenic shock with a blood pressure of 70/56 mm of Hg (**Figure 1A**). His ECG showed broad complex tachycardia with superior axis and LBBB morphology (**Figure 1B**).



**Figure 1.** A- Sinus rhythm ECG showing T wave inversions in V1-3. B- LBBB superior axis VT. C & D- Fibro fatty infiltration of RV (red arrow). E- microscopic H & E section showing epicardial fatty infiltration (black arrow) and inflammatory infiltrates (red arrow).

After 200 Joules of synchronized biphasic direct current (DC) shock was given, the patient reverted to sinus rhythm. This ECG showed only T wave inversions in leads V 1-5 (**Figure 1A**). After stabilization amiodarone infusion was started. However, unfortunately the patient had a recurrence of ventricular tachycardia which degenerated into ventricular fibrillation. There was no response to DC shock and about 45 minutes of cardiopulmonary resuscitation and the patient succumbed. An autopsy was performed.

## Histopathology

On gross examination, the right side of the heart showed yellowish infiltration suggesting fatty or fibro-fatty replacement starting from epicardium extending into the endocardium with thinned out myocardium (**Figures 1C and 1D**). Almost entire muscle layer of right ventricle was replaced by fatty or fibro fatty tissue. This is the hallmark feature of Arrhythmogenic Right Ventricular Cardiomyopathy/Dysplasia (ARVC/D). Definite diagnosis of ARVC requires the histopathologic finding of transmural fatty or fibro-fatty replacement of RV myocardium (**Figure 1E**).

There are two histopathologic variants, namely fatty and fibro-fatty ARVC/D. In the fatty (or lipomatous) variant, the adipose tissue reaches the endocardium (transmural infiltration) and the wall thickness may be normal or even increased ("pseudo-hypertrophy"). However, a small amount of fibrous tissue, usually focal, is always present. In the fibro-fatty variant, the wall is thinner, parchment-like and translucent which accounts for the saccular aneurysms in the so-called triangle of dysplasia, a feature that should be considered pathognomonic of the disease [2].

## Discussion

ARVC is an inherited cardiomyopathy characterized by structural and functional abnormalities of the right ventricular myocardium with a frequency of approximately 1: 5,000. It is an autosomal dominant trait with variable penetrance and incomplete expression. It is an important cause of sudden cardiac death in young adults accounting for about 11% of all deaths [3]. Although ARVC requires histopathologic examination for definitive diagnosis, the typical ECG features and imaging help to identify patients earlier and prevent sudden cardiac deaths [4].

The natural history of ARVC/D is highly variable and four patterns have been proposed [5]:

a) Concealed form, minor arrhythmias, which usually go unnoticed. The diagnosis is usually made during family screening.

b) Overt Electrical Heart disorder, the most typical presentation, which usually occurs in young patients presenting with severe and symptomatic ventricular arrhythmias and SCD.

c) RV failure, RV dysfunction with pump failure.

d) Biventricular failure characterized by progressing dilation of RV and LV; this usually develops late in the natural history of the c.

A proper ECG screening of patients presenting with palpitations and syncope will help in identifying many patients with ARVC/D. There are several ECG features in the criteria diagnosis of ARVD:

a) T wave inversions in V1 through V3 (minor diagnostic criterion, but one of most common ECG abnormality present in 85% of patients

b) QRS duration=110 ms in V1 through V3

c) Epsilon wave (electric potentials after the end of the QRS complex). It is a major diagnostic criterion found in up to 30% of cases of ARVD.

Other ECG markers of ARVD have been reported: QRS and QT dispersion, parietal block defined as a QRS duration in leads V1 through V3 that exceeds the QRS duration in lead V6 by >25 ms, a prolonged S-wave upstroke in V1 through V3=55 ms (it was seen as the most prevalent ECG feature in 95% of ARVD [6].

Those patients meeting the fixed diagnostic criteria by Marcus et al. [6] can be used to make a definitive diagnosis and appropriate management can be instituted [7].

## References

1. Ackerman M, Atkins D, Triedman J (2016) Sudden Cardiac Death in the Young. *Circulation* 133: 1106-1026.
2. McGregor SM, Aliya N, Husain A (2015) Brief Review and Update of the Clinico-pathologic Diagnosis of Arrhythmogenic Cardiomyopathy. *Arch Pathol Lab* 139: 1181-1189.
3. Corrado D, Link M, Calkins H (2017) Arrhythmogenic Right Ventricular Cardiomyopathy; Review article. *N Engl J Med* 376: 61-72.
4. Thiene G, Nava A, Corrado D (1988) Right ventricular cardiomyopathy and sudden death in young people. *N Engl J Med* 188: 129-133.
5. Corrado D, Basso C, Thiene G, McKenna WJ, Davies MJ, et al. (1997) Spectrum of clinico-pathologic manifestations of arrhythmogenic right ventricular cardiomyopathy/dysplasia: a multicentre study. *J Am Coll Cardiol*.1997. 30;1512-1520.
6. Philips B, Cheng A (2016) Diagnosis and management of arrhythmogenic right ventricular dysplasia. *Curr Opin Cardiol* 31: 46-56.
7. Marcus FI, McKenna WJ, Sherrill D, Basso C, Bauce B, et al. (2010) Diagnosis of arrhythmogenic right ventricular cardiomyopathy/dysplasia: proposed modification of the Task Force Criteria. *Eur Heart J* 31: 806-814.