

Electromyography **Angel Molina Leon**

Neurophysiology Clinical Center Virgen De
La Caridad Cartagena-Murcia Spain

Corresponding author:

Angel Molina Leon

✉ molinadelaasuncion@gmail.com

Tel: + 968325258

Citation: Leon AM (2017) Electromyography.
Neurosci Brain Imaging. Vol. 1 No. 1: 2.

Editorial

What is Electromyography and what is used

Electromyography (EMG) is the electrophysiological study of the neuromuscular system. It is a complementary test, and prolongation of the clinical neurological study. Given the broad neuromuscular system and brain, in Spain there is a specific and specific pathway via MIR of Neuromuscular which is called Clinical Neurophysiology which includes EEG, EMG, Multimodal Potentials (PEAT, PEV, PESS) and Intraoperative Monitoring. In addition to sleep pathology, and polysomnography and is taught by physicians via MIR with 4 years of training within this specialty. The EMG is designed in each case according to each protocol, according to the specific pathology, it is not the same to see a syndrome of the carpal tunnel that to see a Polyneuropathy or to study in depth a patient with suspicion of lateral sclerosis amiotrofica ELA, and in function of this each protocol has a different duration. One of the characteristics in my judgment of a good neurophysiologist is meticulousness, patience, the taste for this part of medicine and objectivity, it is very important to be objective [1-3].

The test consists of two part electroneurography and electromyography (**Figure 1**).

Indications of electromyography

- Differentiation between weakness of central or peripheral origin.
- Differentiation between weakness of neurogenic or myogenic origin.
- Differentiation between preganglionic (radicular) or postganglionic (plexular/truncal) lesion.
- Location of the lesion in the mononeuropathies compressive or traumatic and determination of the degree of affectation (focal demyelination versus axonal degeneration) [4,5].
- Differentiation between multifocal neuropathies and polyneuropathies; degree of involvement of the motor and sensory fibers.
- Differentiation between demyelinating and axonal neuropathies.
- Determination of prognosis in neuropathies.
- Characterization of neuromuscular junction disorders (pre- or postsynaptic).
- Identification of signs of denervation, fasciculations, myotonia and neuromyotonia in "normal" muscles.
- Differentiation between cramp and contracture [6].

Electroneurography

Consists of the study of nerves, this sensory conduction, motor conduction, F waves, reflex blink reflex, H reflex, repetitive stimulation, pudendal nerve protocol, etc. This technique is based on the electrical stimulation of a nerve and the recording of the potential caused by placing electrodes to measure it well in the same nerve, or in the muscle innervated by it. The potential is, therefore, and unlike those spontaneously generated by brain and muscle, an artificially produced potential. Latency, conduction velocity (the time it takes for the potential to occur) to be evaluated; the amplitude, that is to say, the functioning volume of structures that generate the response, and the form thereof, i.e. the functional integration of said structure. Latency expresses the degree of myelination of nerve fibers. Increased latency, or even a decrease in nerve conduction velocity, are signs of demyelination [7].

The amplitude of the potential accounts for the number of response generators. At a potential recorded on a nerve, the decrease in amplitude is a sign of axon loss. At the potential recorded in a muscle the decrease in amplitude may mean either axons lost, or the inability of the muscle to respond.

Electromyography study of muscle functionality, there are three types of normal, neuropathic and or myopathic patterns.

Importance of EMG in different syndromes

Mononeuropathies and entrapment syndromes:

Pathophysiology of traumatic nerve injuries (neuroapraxia, axonotmesis neurotmesis)

Clinical presentation of traumatic injuries:

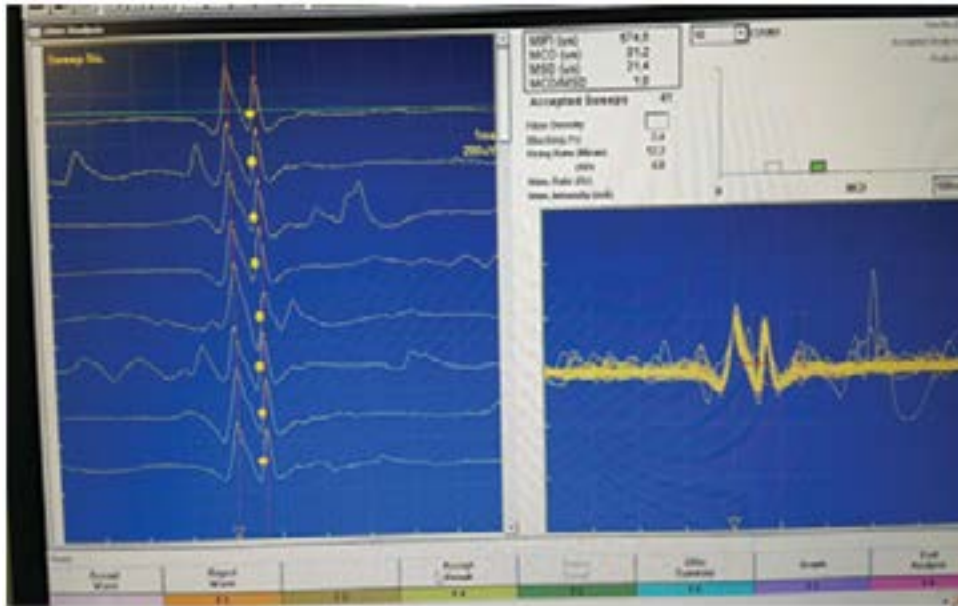


Figure 1 Electroencephalography.

- In acute injuries
- Acute compression injuries
- Chronic compression injuries - Actrapamientos.

EMG diagnosis, classification and prognosis.

Electrophysiological studies in the reinnervation, aberrant axonal regeneration.

Plexopathies and Radiculopathies

Brachial plexopathy and lumbosacral: Idiopathic, traumatic, post-radiation

Pathophysiology of Radiculopathies

Specific clinical situations

Electrophysiological alterations in radiculopathies. Regional Considerations

Value and Limitations of Electrophysiological Study

Intraoperative monitoring

Diseases of motor neurons and spinal cord

Amyotrophic lateral sclerosis, clinical considerations and electrophysiological diagnosis and involvement in the differential diagnosis with motor neuronopathy with anti-GM1 antibodies

Implications of EMG in the diagnosis and assessment of: Poliomyelitis-Post-polio syndrome; viral infections of motor neurons [8].

2nd focal neuron syndromes: Monomyelic amyotrophy, Syringomyelia

Congenital and hereditary neuropathies

Clinical pathophysiology and etiopathogenic advances (molecular genetic studies) of neuropathies whose primary polyneurology

is the primary or predominant: hereditary sensory-motor neuropathy, neuropathy due to excessive pressure vulnerability, familial amyloidotic polyneuropathies, hereditary sensory and dysautonomic neuropathies, hereditary motor neuronopathies, bulb-spinal neuronopathy linked to the X chromosome. Electrophysiological studies based on diagnosis. Classification and nosological characterization. Neuropathies whose polyneuritic syndrome is accompanied by semiologic by affection of other systems (neurological or non-neurological) [9].

Acquired neuropathies

Physiology: Pathophysiology of conduction block, demyelination and axonal degeneration, electroneurographic quantification. Electrophysiological studies in different dysimmune neuropathies (AIDP, CIDP, multifocal motor neuropathy with conduction blockages) performance and limitations in diagnosis, subtype differentiation and prognosis.

Characterization of the different forms of diabetic neuropathy.

Differential features of EMG results in different toxic and metabolic neuropathies.

Neuromuscular transmission disorders.

Pathophysiology of neuromuscular transmission.

Electrophysiological study in postsynaptic origin processes (myasthenia gravis) its diagnostic performance in the different forms.

Study in processes of presynaptic origin (Eaton Lambert syndrome, Botulinum intoxication).

Clinical and electrophysiological characterization of the main congenital myasthenic syndromes.

Myopathies

Clinical and pathophysiology of genetic processes (Dystrophinopathies sarcoglycanopathies, channelopathies) and acquired (inflammatory, toxic, endocrine myopathies) that affect muscular function.

Development and application of quantitative EMG techniques, correlation and support to the indication of histological studies and their limitations.

Cranial neuropathy

Assessment and prognosis in facial paralysis.

Hemifacial spasm.

Syndromes with motor axonal hyperactivity

Central Nervous System:

Electrophysiological study in movement disorders (Tremor, myoclonus, cranio-cervical dystonia and spasm of the clerk ...).

Multisystemic atrophy.

References

- 1 Brown WF (1984) The physiological and technical basis of electromyography. Boston: Butterworth-Heinemann.
- 2 Brown WF, Bolton CF (1993) Clinical electromyography. Second edition. Boston: Butterworth-Heinemann.
- 3 Daube JR (1991) AAEM minimonograph 11. Needle examination in clinical electromyography: Muscle Nerve 14: 685-700.
- 4 Dumitru D (1995) Electrodiagnostic medicine. Philadelphia: Hanley & Belfus,
- 5 Hodgkin AL (1965) The conduction of the nerve impulse. The Sherrington lectures. Vol.7, Liverpool University Press. Liverpool.
- 6 Donald B. Sanders (1989) Electrodiagnosis in diseases of nerve and muscle. Principles and practice. Philadelphia, F.A.Davis 7: 500-501.
- 7 Liveson JA (1991) Peripheral neurology: Case studies in electrodiagnosis. Second edition. Philadelphia: F.A.Davis Company 36: 404.
- 8 Oh SJ (1993) Clinical electromyography: Nerve conduction studies. Second edition. Baltimore: Williams & Wilkins. Clin Neurophysico 97: 284.
- 9 Sumner AJ (1980) The physiology of peripheral nerve disease. Philadelphia: WB Saunders.