

Viable Primary Ectopic Pregnancy in the Uterosacral Ligament: A Case Report and Review of the Literature

Ala Aiob¹, Sharon Avisholm², and Jacob Bornstein^{1*}

- 1 Department of Obstetrics and Gynaecology, Galilee Medical Centre, Nahariya, Israel
- 2 Azrieli Faculty of Medicine, Bar-Ilan University, Safed, Israel

Abstract

Background: Uterosacral ligament implantation of primary abdominal pregnancies is an extremely rare form of ectopic pregnancy.

Methods and findings: We report the case of a rare spontaneous uterosacral ligament conception in a 34-year-old woman. This was the patient's third pregnancy, and she had no known risk factors for ectopic pregnancy. Vaginal ultrasonography revealed a viable ectopic pregnancy close to the left ovary. Laparoscopy found a conceptus implanted in the left uterosacral ligament. Tissue was bluntly removed and pathologically confirmed as chorionic villi.

Conclusion: The rarity of this condition signifies the need for reporting all cases to facilitate optimal clinical management, as well as to aid future research.

Keywords: Primary abdominal pregnancy; Ectopic pregnancy; Uterosacral ligament; Laparoscopy

Abbreviations: CRL: Crown-Rump Length; hCG: Beta-Human Chorionic Gonadotropin

*Corresponding author: Bornstein J

✉ mdjacob@gmail.com

Chairman, Department of Obstetrics & Gynaecology Galilee Medical Centre, Nahariya, Israel.

Tel: 97249107720

Citation: Aiob A, Avisholm S, Bornstein J (2021) Viable Primary Ectopic Pregnancy in the Uterosacral Ligament: A Case Report and Review of the Literature. *Gynecol Obstet Case Rep* Vol.7 No.1:3

Received: January 11, 2020; **Accepted:** January 25, 2021; **Published:** February 02, 2021

Introduction

An abdominal pregnancy is a pregnancy that is implanted outside the uterus, fallopian tubes, and ovaries on either the peritoneum of the pelvis or the abdominal cavity. It is a rare form of ectopic pregnancy. The uterosacral ligament is one of the rarest implantation sites, and only a small number of cases have been reported [1]. Abdominal pregnancies present in a manner similar to tubal ectopic pregnancies, and it is difficult to distinguish between the two using ultrasonography. Importantly, any delay in diagnosis and treatment may be life threatening.

Here we describe the unique case of an intact and viable abdominal ectopic pregnancy. An embryo of 7 weeks' gestation, exhibiting a pulse, was discovered on the left uterosacral ligament in a patient who had no risk factors for ectopic pregnancy. The pregnancy was diagnosed and treated with laparoscopic surgery. It is important to describe such extremely rare cases and increase understanding of their physiopathology and clinical presentation in order to improve diagnosis and management. We believe that laparoscopic findings are important in helping to explain the

pathophysiology of abdominal pregnancies in general and a left uterosacral ligament implantation in particular.

Case Report

A 34-year-old woman, para 2, in her third pregnancy for 7 weeks, presented to the emergency department with left lower abdominal pain that began a few hours prior and was associated with nausea. Previously, she had two uncomplicated vaginal deliveries, and she experienced a regular 28-day menstrual cycle with no symptoms of endometriosis. She reported no history of pelvic inflammatory disease and no past pelvic surgeries.

On admission, the patient was stable. Abdominal examination disclosed slight tenderness in the left lower quadrant. A pelvic examination was positive for tenderness above the left adnexa. Laboratory tests indicated low haemoglobin (11.3 g/dL) and elevated beta-human chorionic gonadotropin (hCG) (17483 mIU/mL). Ultrasonography showed no intrauterine gestation, an endometrial thickness of 16 mm, and normal right and left ovaries. However, to the left of the left ovary there was a gestational sac with a yolk sac and an embryo with a pulse and

crow-rump length (CRL) consistent with 7 weeks' gestation, according to the Hadlock curve (**Figure 1**). The gestational sac was located posterolateral to the cervix, adjacent to the left uterosacral ligament, and could be separated from the left ovary by gentle pressure (sliding sign) but could not be separated from the cervix in the same way.

After providing written consent, the patient underwent laparoscopy for evaluation and management. The laparoscopy revealed a hemoperitoneum of 200 ml which was subsequently drained. The uterus appeared normal, and both fallopian tubes and the ovaries were intact - without evidence of rupture or injury. However, the left adnexa appeared to have adhesions on the inner part of the broad ligament close to the uterosacral ligament. Upon closer examination, the left uterosacral ligament had a 2.5 cm mass that appeared to be an ectopic pregnancy (**Figures 2 and 3**). The conceptus was prized from the uterosacral ligament without the use of electrocautery or incision and sent

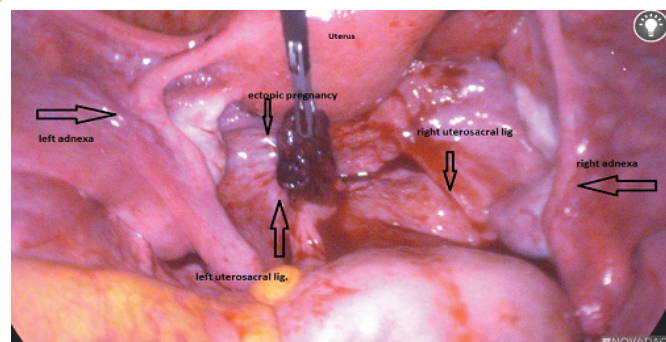


Figure 3 Laparoscopic image of posterior cul-de-sac, including the ectopic pregnancy removed from the left uterosacral ligament.

for pathological examination. Irrigation led to oozing of blood, which was successfully treated with diathermy.

The patient made a good recovery. A repeat test the day after surgery indicated that her beta-hCG had decreased to 5999 mIU/mL. It continued to decrease and became negative within 3 weeks of the surgery. The patient's 1-month follow-up physical and sonographic examinations were normal.

Discussion

Primary peritoneal pregnancy is rare, occurring in about 1 in 10,000 pregnancies [2], and accounts for approximately 1.4% of ectopic pregnancies [2-4]. Uterosacral pregnancy is one of the rarest implantation sites, and only a small number of cases have been described [1]. Mortality from abdominal pregnancy can be as high as 30% [5]. It is unclear whether abdominal pregnancy develops as a result of secondary implantation of an ovarian or fallopian tube pregnancy that has fallen into the peritoneum or is a result of fertilization of the sperm and egg in the peritoneal cavity and primary implantation of the embryo [6,7]. Studdiford [8] proposed the following diagnostic criteria for primary abdominal pregnancy:

- Normal ovaries and fallopian tubes without rupture or injury;
- Absence of an utero-peritoneal fistula; and
- Pregnancy located only on the peritoneum that began early enough to rule out secondary implantation.

The risk factors for abdominal pregnancy include fallopian tube pathology, previous pelvic inflammatory disease, endometriosis, *in vitro* fertilization, and multiparity [9]. Our patient did not have any of these risk factors. Based on laparoscopic and histological findings, our patient's pregnancy met all the criteria for a primary abdominal pregnancy. We found adhesions in the area of implantation that may be from a previously unreported risk factor, thus supporting the idea that this was a primary peritoneal pregnancy.

Based on the initial ultrasonography, we initially assumed that the patient had a left tubal ectopic pregnancy with a 7-week-old embryo. Laparoscopy was carried out because the patient had a

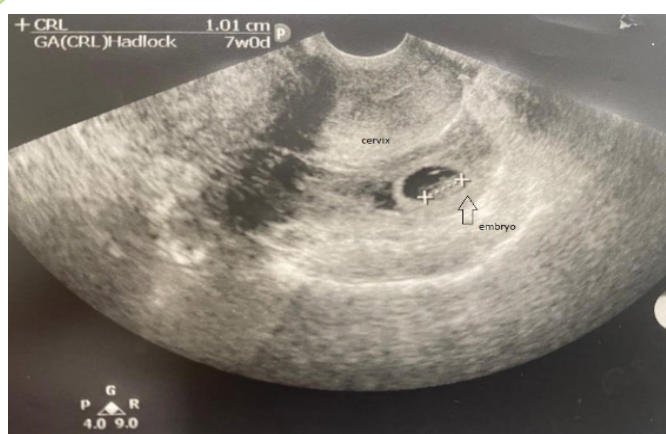

Figure 1 Transvaginal ultrasound image of the gestational sac with yolk sac and embryo located posterior to the cervix. Crown-rump length (CRL) is consistent with 7 weeks' gestation.

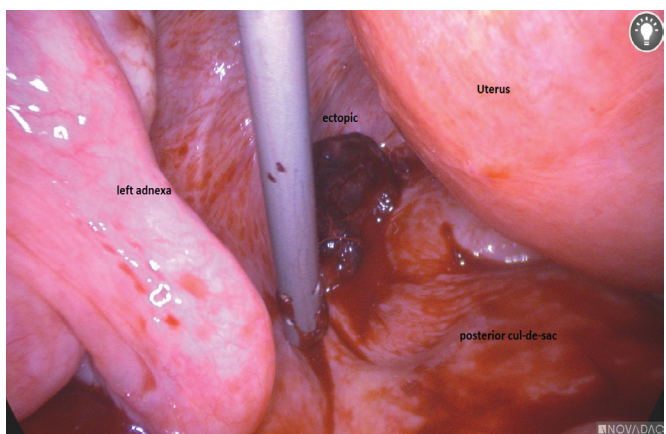


Figure 2 Laparoscopic image of unremarkable right and left fallopian tubes and ovaries, normal right uterosacral ligament, and left uterosacral ligament with the ectopic pregnancy.

Table 1 Uterosacral pregnancy – A review of the literature.

Characteristics	Shin et al. [10]	Lo & Lau [11]	Lo & Lau [11]	Gundabattula & Pochiraju [12]	Cheung & Rosenthal [13]	Dasari & Devi [14]	Abedin & Chadha [1]	Park & Shin [15]	Present Case
Age (years)	28	33	32	30	24	22	29	24	34
Obstetric formula	G2A1	G1P0	G4P2	G3P1		G2P1	G1P0	G2P0A1	G3P2
Risk factor	—	Endometriosis	—	—	—	IUD	Infertility; hysteroscopy 1 month prior to presentation; endometriosis; adhesions	NA	Adhesions
Weeks	8	6	7		—	7			7
Beta-hCG	—	—	—	5699 mIU/mL	—	—	6311 mIU/mL	-	17483 mIU/mL
Treatment modality	Laparotomy and surgical removal	Laparoscopy followed by laparotomy and suture for haemostasis	Laparoscopy and surgical removal	Surgical removal (hydro dissection) via laparotomy followed by parenteral MTX 50 mg/m2	Laparoscopy and surgical removal	Laparotomy and surgical removal	Laparoscopy and surgical removal	Laparoscopy and surgical removal	Laparoscopy and surgical removal
Preoperative diagnosis	Haemo-peritoneum and cystic mass in the posterior wall of the uterus. No gestational sac	Haemo-peritoneum and rupture ectopic pregnancy	Haemo-peritoneum and rupture ectopic pregnancy	Right tubal ectopic pregnancy	—	Haemo-peritoneum and rupture ectopic pregnancy	Haemo-peritoneum and rupture ectopic pregnancy	Haemo-peritoneum and rupture ectopic pregnancy	Left adnexal ectopic pregnancy
Side of implantation	L uterosacral ligament	R uterosacral ligament	L uterosacral ligament	R uterosacral ligament	R uterosacral ligament	R uterosacral ligament	L uterosacral ligament	R uterosacral ligament	L uterosacral ligament
Foetal pulse	—	No TVS	No TVS	20 ×16 mm echogenic R adnexal mass and 2 mm viable embryo	—	No TVS	6.9 × 4.6 × 4.7 cm complex L adnexal mass		Yolk sac and embryo with foetal activity CRL 6 weeks
Year	1999	1996	1996	2014	2004	2000	2020	2007	2020
Abdominal pain	Yes	Yes	Yes	Yes	Yes	Yes	Yes	Yes	No
Blood in the abdominal cavity	1000 mL and clot	1000 mL and clot	1000 mL and clot	1000 mL	—	2000 mL	1000 mL	—	200 mL

Abbreviations: A: Abortion; beta-hCG: Beta Human Chorionic Gonadotropin; CRL: Crown-Rump Length; G: Gravidity; IUD: Intrauterine Device; L: Left; NA: Not Applicable; P: Parity; R: Right; TVS: Transvaginal Ultrasound

high beta-hCG level, and the embryo had a pulse (**Figure 2**). These are both considered to be contraindications for methotrexate treatment, according to our hospital’s departmental protocol.

Primary peritoneal pregnancy can lead to serious complications, such as an intraperitoneal haemorrhage requiring blood transfusion, and it can be fatal. It is important for gynaecologists and other clinicians who treat pregnancy to be aware that sonograms do not always correctly diagnose a peritoneal pregnancy. Thus, it is important to maintain a significant level of concern, when an ectopic pregnancy is suspected and laparoscopy will be performed as treatment that the pregnancy may be of a different type than originally thought. It is imperative to perform pelvic and abdominal explorations in order to locate the pregnancy implantation site.

There is currently inadequate data about uterosacral pregnancy, its diagnosis, risk factors and optimal treatment, due to the rarity of this condition. In **Table 1**, we summarise a small number of case reports we found in the literature [10-15].

As shown, in six of the nine cases, the patient had no preoperative risk factors for ectopic pregnancy; however, the use of intrauterine devices and endometriosis were each associated with primary peritoneal pregnancy within the uterosacral ligament. Our patient did not have any of these known risk factors, but during the laparoscopy, she was found to have adhesions in the left adnexa, which may have been a factor that contributed to the development of a primary peritoneal pregnancy within the left uterosacral ligament.

These adhesions provide supporting evidence of an hypothesised

mechanism for primary peritoneal pregnancy in general, and a left uterosacral peritoneal pregnancy more specifically. The implantation in the left uterosacral ligament involves sperm that accumulates in this region due to the closeness of the fimbria to the uterosacral ligament which meets an ovum within the region, and implants in the uterosacral ligament.

In all the cases presented in the table, there were no preoperative diagnoses of peritoneal pregnancy. This indicates that there is currently a lack of reliable ways to make preoperative diagnoses of peritoneal pregnancy. Thus, surgeons need to maintain a greater level of caution and consider other implantation sites for ectopic pregnancy when a ruptured ectopic pregnancy is suspected, and laparoscopy is performed. In all of the cases shown in the table, except ours, management was urgent because of hemoperitoneum.

Management of ectopic pregnancy within the uterosacral ligament will vary depending upon the patient's condition, beta-hCG, gestational age and size, presence of a foetal pulse, and the surgeon's skill. It can be managed surgically, using laparoscopy or laparotomy, or pharmacologically, through administration of

methotrexate [10-15]. Surgical removal alone may be sufficient for definitive treatment.

Conclusion

In our case, we successfully used laparoscopy and blunt removal of the conceptus from the left uterosacral ligament and monitored the patient's beta-hCG values, without administering methotrexate. We have described a case of an ectopic pregnancy with foetal pulse, located on the left uterosacral ligament. The patient was treated by performing laparoscopic removal of the ectopic pregnancy alone, due to contraindications related to methotrexate administration, and was followed-up postoperatively. Primary peritoneal pregnancy is rare, and implantation on the uterosacral ligament is extremely rare. It is important to report cases in order to develop better understanding of the pathophysiology, and to determine optimal patient treatment and management practices.

Conflict of Interest

The authors declare that there is no conflict of interests.

References

1. Abedin Y, Chadha K (2020) Case of ruptured ectopic pregnancy in the uterosacral ligament and review of the literature. *Obstet Gynecol*. 2020; 5897341.
2. Atrash HK, Friede A, Hogue CJ (1987) Abdominal pregnancy in the United States: frequency and maternal mortality. *Obstet Gynecol*. 69(3): 333-337.
3. Dover RW, Powell MC (1995) Management of a primary abdominal pregnancy. *Am J Obstet Gynecol* 172(5): 1603-1604.
4. Fisch B, Peled Y, Kaplan B, Zehavi S, Neri A (1996) Abdominal pregnancy following *in vitro* fertilization in a patient with previous bilateral salpingectomy. *Obstet Gynecol* 88(4): 642-643.
5. Poole A, Haas D, Magann EF (2012) Early abdominal ectopic pregnancies: A systematic review of the literature. *Gynecol Obstet Invest* 74(4): 249-260.
6. Ludwig M, Kaisi M, Bauer O, Diedrich K (1999) A case report: The forgotten child - A case of heterotopic, intra-abdominal and intrauterine pregnancy carried to term. *Hum Reprod* 14(5): 1372-1374.
7. Varma R, Mascarenhas L, James D (2003) Successful outcome of advanced abdominal pregnancy with exclusive omental insertion. *Ultrasound Obstet Gynecol* 21(2): 192-194.
8. Studdiford WE (1942) Primary peritoneal pregnancy. *Am J Obstet Gynecol* 44(3): 487-491.
9. Tsudo T, Harada T, Yoshioka H, Terakawa N (1997) Laparoscopic management of early primary abdominal pregnancy. *Obstet Gynecol* 90(4): 687-688.
10. Shin JS, Moon YJ, Hwang YY (2000) Primary peritoneal pregnancy implanted on the uterosacral ligament. *J Korean Med Sci* 15: 359-362.
11. Lo KW, Lau TK (1997) Ectopic pregnancy in uterosacral ligament. *J Obstet Gynaecol* 23(5): 415-419.
12. Gundabattula SR, Pochiraju M (2014) Primary abdominal pregnancy in the uterosacral ligament with haemoperitoneum: A near miss. *J Clin Diagn Res* 8(5): OD08.
13. Cheung VY, Rosenthal DM (2005) Abdominal pregnancy. *J Minim Invasive Gynecol* 12(1): 9.
14. Dasari P, Devi S (2000) Primary peritoneal pregnancy: A case report. *J Obstet Gynaecol Res* 26(1): 45-47.
15. Kwon JY, Shin WM, Yoon JS, Hwang SJ, Park IY, et al. (2007) A case of abdominal pregnancy implanted on uterosacral ligament. *Korean J Obstet Gynecol* 50(7): 1027-1032.