

HIGHLIGHT ARTICLE

Updates in Management of Ampullary Carcinomas

Highlights from the "2014 ASCO Gastrointestinal Cancers Symposium".

San Francisco, CA, USA. January 16-18, 2014

**Preethi K John¹, Andromachi S Kougioumtzopoulou²,
Konstantinos N Syrigos³, Muhammad Wasif Saif¹**

¹Department of Medicine and Cancer Center, Tufts Medical Center. Boston, MA, USA.

²Radiotherapy Unit, Second Department of Radiology, Attikon General Hospital; ³Oncology Unit, Third Department of Medicine, University of Athens, Sotiria General Hospital. Athens, Greece

Summary

Ampullary carcinomas are rare malignancies representing less than 1% of all gastrointestinal cancers. Given the low incidence rate, there is scarcity of data regarding the survival benefit of the treatment options available. In the 2014 ASCO Gastrointestinal Cancers Symposium there were two abstracts that discussed the role of pancreaticoduodenectomy and adjuvant radiation therapy in ampullary carcinoma. The first study (Abstract #366) demonstrated a decline in morbidity and mortality over time for pancreaticoduodenectomy making it a reasonable option for successful treatment of ampullary carcinoma. The second study (Abstract #282) showed that adjuvant radiation therapy in patients with T2 tumors had improved median survival times compared to patients that did not receive radiation therapy.

What We Knew Before the 2014 ASCO Gastroenterology Cancers Symposium

Ampullary carcinomas are rare malignancies with an incidence of approximately six in one million [1]. These tumors represent approximately 6% of periampullary tumors and less than 1% of all gastrointestinal cancers [1, 2, 3]. However, the incidence rate of ampullary cancers has increased by about 1% every year over the past 30 years. Ampullary carcinomas originate from the ampulla of Vater, which is an opening in the first part of the duodenum where pancreatic and bile secretions enter the small intestine distal to the junction of the main pancreatic duct and the common bile duct. Periampullary tumors can originate from the bile ducts, intestines, or the pancreas [3]. Ampullary carcinomas can originate from intestinal epithelium or pancreaticobiliary ductal epithelium. The histopathological classification of ampullary

carcinomas is critical in determining prognosis. Studies have shown that the intestinal histological subtype has better survival rate compared to the pancreaticobiliary sub-type [2, 4].

The standard treatment for ampullary carcinoma has been complete surgical resection via pancreaticoduodenectomy. There are several surgical approaches for resection of ampullary tumors that include endoscopic resection as well as local ampullectomy [5]. Evidence suggests that pancreaticoduodenectomy has significantly improved survival rates in ampullary carcinomas with 5-year survival rates up to 39% [6]. A recent prospective trial in 2010 analyzed survival of 450 patients with ampullary tumors who underwent pancreaticoduodenectomy and found that the 5-year survival rate was 45% [5]. Since complication rates have ranged from 11.7% to 59%, the perioperative risk of the procedure is most concerning and must be carefully evaluated to make an informed decision [7]. Complications include pancreatic fistula, delayed gastric emptying, wound infection, abdominal abscess, cardiac event, and bile leak [5]. Perioperative mortality rates of pancreaticoduodenectomy have been high in the past but recent data have shown 30-day mortality rates ranging from 0 to 8% [7]. Given the rarity of ampullary carcinomas, data have been limited to small retrospective studies. However, advancing

Key words Ampulla of Vater; Neoplasms; Pancreaticoduodenectomy; Radiotherapy

Abbreviations SEER: Surveillance, Epidemiology and End Results

Correspondence Preethi K John

Department of Medicine and Cancer Center; Tufts University School of Medicine; Tuft Medical Center; 800 Washington Street; Boston, MA 02111; USA

Phone: +1-973.902.2654 ; Fax: +1-617.636.8538

E-mail: pjohn@tuftsmedicalcenter.org

technology has allowed for improved surgical techniques leading to improved mortality and morbidity rates.

There has been a lack of specific therapeutic protocols for adjuvant treatment of ampullary cancer. Although only supported by retrospective or small randomized studies, data indicate that adjuvant chemoradiation has improved survival outcomes. A retrospective study from Narang *et al.* compared surgery plus adjuvant chemoradiation with surgery alone for patients with ampullary cancer. The results of this study showed a benefit of adjuvant chemoradiation for node positive patients with an increase in median overall survival (32 vs. 16 months) [1]. An alternate option in the adjuvant setting is represented by chemotherapy given as monotherapy [8]. The data indicates that, for certain patients, this treatment approach has improved overall survival rates [9].

What We Have Learned at the 2014 ASCO Gastrointestinal Cancers Symposium

This paper summarizes the recent work presented at the 2014 ASCO Gastrointestinal Cancers Symposium regarding the survival advantage as well as morbidity/mortality of surgical and adjuvant radiation treatments for ampullary carcinoma. The purpose of this paper is to present the data of the two presented abstracts.

Pancreaticoduodenectomy (PD) for Periampullary Tumors: Results from Tata Memorial Centre (TMC) Over Two Decades (Abstract #366 [10])

Shrikhande *et al.* performed a retrospective study to evaluate the survival outcomes of pancreaticoduodenectomy for periampullary tumors over time. A total of 626 patients who underwent pancreaticoduodenectomy for periampullary tumors were studied. Morbidity and mortality were analyzed over a period of 22 years. The time period was divided as such: span A included patients from 1991 to 2001, span B included patients from 2003 to July 2009, span C included patients from August 2009 to

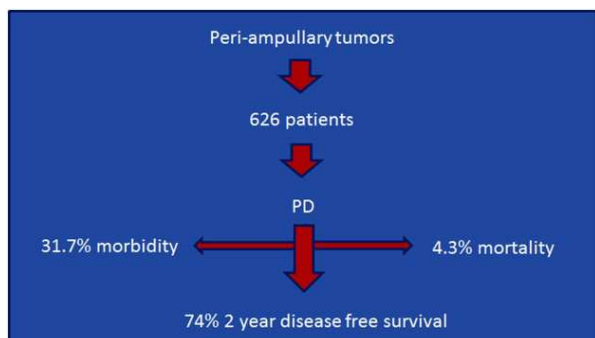


Figure 1. Morbidity, mortality, and survival of patients with periampullary tumors who underwent pancreaticoduodenectomy (PD). (Shrikhande *et al.*; Abstract #366 [10])

December 2012, and span D included patients from January 2013 to July 2013. The number of patients included in each span was 144, 206, 150, and 126 respectively. The most common site of tumor origin was the ampullary region which made up 67.5% of the cases. The results of this study are summarized in Figure 1. The morbidity rate was 31.7% and the mortality rate was 4.3%. The most common post-operative complication was pancreatic fistula at 12.4%. The data showed that the morbidity and mortality rates had declined over time. Overall 2-year disease free survival was found to be 74% for periampullary adenocarcinoma. The study shows an overall decline in morbidity and mortality of pancreaticoduodenectomy in periampullary adenocarcinoma which is likely due to experienced operating teams and the high volume of pancreaticoduodenectomy performed.

Role of Adjuvant Radiation Therapy in Ampullary Carcinoma: Propensity-Score Matched SEER Analysis (Abstract #282 [11])

Byun *et al.* presented the results of a retrospective study analyzing patients with ampullary cancer who received adjuvant radiotherapy. The origin of the data is the Surveillance, Epidemiology and End Results (SEER) database. The authors included patients with ampullary carcinoma who were treated with curative surgery. The precondition of including patients into the study was registration in the SEER database during the time period from 1998 to 2008. Parameters, such as age at diagnosis, race, TNM staging, histological subtype and overall survival, were used for analysis and were compared between patients who received radiotherapy and those who did not. Exclusion criteria were M1 disease and follow up less than 5 months. In order to estimate the effect of adjuvant radiotherapy and to eliminate selection bias, propensity score matching was used. A total of 1,782 patients were included in the study of which 25% received radiotherapy. Among radiotherapy patients, 65% had T3 or T4 tumors and 68% were node positive. The results of the study showed that adjuvant radiotherapy does not significantly improve median survival times if data is not adjusted for tumor stage. In contrast, the subgroup of patients who had T2 tumors and received radiotherapy had significantly improved median survival times.

Discussion

Given the rarity of ampullary carcinomas, there is scarce data in regards to pancreaticoduodenectomy and adjuvant radiation therapy. Despite this limitation, recent data have been pointing towards pancreaticoduodenectomy as the recommendation for surgical management of ampullary carcinomas. In the 2014 ASCO Gastrointestinal Cancers Symposium, the survival outcomes of pancreatico-

Table1. Take home points.

What we have known:	<ul style="list-style-type: none">• Pancreaticoduodenectomy is the primary surgical treatment for ampullary carcinoma• Initially thought to have a high morbidity/mortality rate• Other local surgical options such as trans-duodenal ampullectomy and endoscopic resection have higher recurrence rates• Adjuvant chemotherapy and radiation has been shown to improve survival outcomes in node positive patients with ampullary carcinoma
What we now know:	<ul style="list-style-type: none">• Morbidity/mortality rates have significantly decreased over time for pancreaticoduodenectomy• Factors contributing to decreased complication rates for pancreaticoduodenectomy include increasingly experienced surgical teams and advanced technology with improved surgical techniques• T2 stage ampullary tumors benefited from adjuvant radiation therapy with improved survival outcomes

duodenectomy in periampullary tumors were analyzed. This study is congruent with previous studies displaying evidence of declining morbidity and mortality rates for pancreaticoduodenectomy. This study also reported a high two-year disease free survival rate. A randomized controlled trial would provide stronger evidence for morbidity and mortality rates compared to this retrospective study. Another limitation is that the study took place at a single institution which limits the variability of patient population and hospital standard of care. Morbidity and mortality rates will differ across various institutions depending on the volume of pancreaticoduodenectomy cases as well as the experience of the surgical team. The high survival rate is likely because most of the tumors were of ampullary origin which has a better prognosis compared to pancreatic origin. Currently, other interventions include trans-duodenal ampullectomy or endoscopic ampullectomy. These interventions have less morbidity and mortality rates compared to pancreaticoduodenectomy. However, the disadvantage with these procedures is that patients have higher recurrence rates, require closer surveillance, and resection margins may not be clear [12]. The hope is that in the future there can be large randomized controlled trials to confirm the results from the current studies. There is much optimism that pancreaticoduodenectomy offers the best chance of survival in a patient with ampullary cancer.

In regards to adjuvant radiotherapy the gold standard has not yet been defined. One of the limitations of Abstract #282 [11] is the relatively small proportion of patients who actually received radiotherapy (490 out of 1,782). This is rather low given the heterogeneous study population. Furthermore, 75% of patients in the radiotherapy group had locally advanced disease. These patients have a high probability to develop loco-regional recurrence and distant metastasis which directly affects the end point of the study. In addition, it is not reported whether patients who received adjuvant radiotherapy received concurrent chemotherapy. Recent studies focusing on the effect of concurrent adjuvant radiation and adjuvant

chemotherapy showed that both treatment modalities have an impact on outcome [8].

Despite the above mentioned limitations, the presented study provides vital information to the literature concerning adjuvant treatment of patients with ampullary cancer (Table 1). According to the presented results, early stage tumors (T2) benefit from adjuvant radiotherapy. Multicenter prospective randomized trials which include the combination of chemotherapy and radiotherapy, may one day define the optimal adjuvant management for patients with these rare cancers.

Conflict of interest The authors have no potential conflict of interest

References

1. Narang AK, Miller RC, Hsu CC, Bhatia S, Pawlik TM, Laheru D, Hruban RH, Zhou J, Winter JM, Haddock MG. Evaluation of adjuvant chemoradiation therapy for ampullary adenocarcinoma: The Johns Hopkins Hospital-Mayo Clinic collaborative study. *Radiat Oncol.* 2011;28:126.
2. Gaspar B, Beuran M, Paun S, Ganescu R, Hostiuc S, Negoii I. Current strategies in the therapeutic approach for adenocarcinoma of the ampulla of Vater. *J Med Life.* 2013 Sep 15;6(3):260-5.
3. Albores-Saavedra J, Schwartz AM, Batich K, Henson DE. Cancers of the ampulla of Vater: Demographics, morphology, and survival based on 5,625 cases from the SEER program. *J Surg Oncol.* 2009;100(7):598-605.
4. Carter JT, Grenert JP, Rubenstein L, Stewart L, Way LW. Tumors of the ampulla of Vater: Histopathologic classification and predictors of survival. *J Am Coll Surg.* 2008;207(2):210-8.
5. Winter JM, Cameron JL, Olin K, Herman JM, de Jong MC, Hruban RH, Wolfgang CL, Eckhauser F, Edil BH, Choti MA. Clinicopathologic analysis of ampullary neoplasms in 450 patients: Implications for surgical strategy and long-term prognosis. *Journal of Gastrointestinal Surgery.* 2010;14(2):379-87.
6. Sommerville C, Limongelli P, Pai M, Ahmad R, Stamp G, Habib N, Williamson R, Jiao L. Survival analysis after pancreatic resection for ampullary and pancreatic head carcinoma: An analysis of clinicopathological factors. *J Surg Oncol.* 2009;100(8):651-6.
7. Kim RD, Kundhal PS, McGilvray ID, Cattral MS, Taylor B, Langer B, Grant DR, Zogopoulos G, Shah SA, Greig PD. Predictors of failure after pancreaticoduodenectomy for ampullary carcinoma. *J Am Coll Surg.* 2006;202(1):112-9.
8. Heinrich S, Clavien P. Ampullary cancer. *Curr Opin Gastroenterol.* 2010;26(3):280-5.

9. Neoptolemos JP, Moore MJ, Cox TF, Valle JW, Palmer DH, McDonald AC, Carter R, Tebbutt NC, Dervenis C, Smith D. Effect of adjuvant chemotherapy with fluorouracil plus folinic acid or gemcitabine vs observation on survival in patients with resected periampullary AdenocarcinomaThe ESPAC-3 periampullary cancer randomized TrialAdjuvant therapy and periampullary adenocarcinoma. JAMA. 2012;308(2):147-56.

10. Shrikhande VS, Mitra A, Sirohi B, Bal M, Goel M et al. Pancreaticoduodenectomy (PD) for periampullary tumors:

Results from Tata Memorial Centre (TMC) over two decade. J Clin Oncol 32, 2014 (suppl 3; abstr 366)

11. Byun J, Grover S, Michelle LH, Apisarnthanarax S. Role of adjuvant radiation therapy in ampullary carcinoma: Propensity-score matched SEER analysis. J Clin Oncol 32, 2014 (suppl 3; abstr 282)

12. Dittrick GW, Mallat DB, Lamont JP. Management of ampullary lesions. Current treatment options in gastroenterology. 2006;9(5):371-6.
