

# The Surgical Management of Non-Functioning Pancreatic Neuro-Endocrine Tumors

Toshihiko Masui, Takayuki Anazawa, Kyoichi Takaori, Shinji Uemoto

Department of Surgery, Kyoto University, Kyoto, Japan

## ABSTRACT

The incidence of pancreatic neuroendocrine tumors is increasing and the ratio of non-functioning tumors is gradually increasing due to progress in imaging technology. The definition of a non-functioning PNET is a tumor which presents without symptoms. These are potentially malignant and treatment is recommended according to size. The first choice for the treatment of a non-functioning pancreatic neuroendocrine tumor is resection. Localized, small, malignant non-functioning PNETs should be aggressively resected, while for small benign-appearing tumors the risks and the benefits of surgery should be carefully weighed. The surgical resection of liver metastases from non-functioning PNETs should be recommended if complete resection is possible. However, the benefit of surgical resection is limited compared to intra-arterial therapy if the tumor burden is high.

## INTRODUCTION

Pancreatic neuroendocrine tumors (PNETs) are classified into several categories including functioning or non-functioning, local or with distant disease, well differentiated or poorly differentiated, and sporadic or familial. Non-functioning PNETs constitute about half of PNETs in recent epidemiological studies in the world [1, 2]. A non-functioning PNET is defined as a tumor without specific symptoms due to elevated hormone levels. Although patients have no symptoms, most non-functioning PNETs pathologically express hormones such as insulin or glucagon although the contribution of this phenotype to the tumor character has not been elucidated. In addition, non-functioning PNETs often secrete chromogranin A, neuron specific enolase, pancreatic polypeptide, calcitonin, neurotensin or other peptides [3, 4, 5]. The biological characteristics of non-functioning PNETs is quite different from functioning PNETs and the surgical treatment should be considered according to these characteristics. In this review, we discuss the surgical treatment of non-functioning PNETs based on a number of classifying features.

### Localized PNETs

**Indication for resection:** Symptoms from non-functioning PNETs often include abdominal fullness or abdominal pain due to a large tumor at the time of

presentation. However, recent advances in imaging have led to an increase in incidentally identified small size non-functioning PNETs. Epidemiologic studies have shown that about half of all PNETs are non-functioning [1]. Non-functioning PNETs are considered to be potentially malignant, therefore several guidelines, including those of the NCCN, recommend resection [6]. However, resection of tumors less than 2 cm in diameter is still controversial. For example, Sadot *et al.* recommended observation in selected situations such as small tumors, which are incidentally discovered. The decision for further treatment should be made based on estimated surgical risk, site of the tumor and patient comorbidities [7]. In their study, case matched patients with small PNETs were retrospectively analyzed and they found no difference in overall survival between the groups. The observation group demonstrated no tumor growth or development of metastases during 44 months follow up. Although this study is a high-quality, case matched analysis, this is potentially a retrospective study and the median follow up is less than 5 years, lacking information regarding long term survival.

At the present time, most recommendations suggest that localized non-functioning PNETs should be resected and patients with other life-limiting comorbidities, high surgical risk, or widely metastatic disease should be evaluated on an individual basis, reserving observation only for select patients.

### Resection of Non-Functioning PNETs

The extent of resection and lymphadenectomy should be performed according to the tumor size (**Table 1**). Small tumors, less than 2.0 cm diameter, are candidates for local resection. Enucleation can be applied to small tumors in the periphery of the pancreas only when the main pancreatic duct is far enough from the tumor. However, we have to note that local resections, including enucleation, tend to have

Received July 23rd, 2017 - Accepted November 07th, 2017

**Keywords** Neuroendocrine Tumors; Non-functioning pancreatic endocrine tumor; surgery

**Abbreviations** PNETs pancreatic neuroendocrine tumors; VHL Von Hippel-Lindau syndrome

**Correspondence** Toshihiko Masui

Kyoto University, Department of Surgery

54 Shogoin, Kawaracho, Sakyo, Kyoto, Japan

**Tel** +81 (0)78 606-8507

**E-mail** tmasui@kuhp.kyoto-u.ac.jp

**Table 1.** Extent of resection of PNETs according to tumor size.

Tumor Size	Resection	Lymphadenectomy
<10 mm	local resection	sampling
10-20 mm	(enucleation or middle pancreatectomy)	Sampling with intensive examination of regional lymph node
>20 mm	typical pancreatectomy	standard

high morbidity compared to a standard pancreatectomy [8, 9]. Negative margins cannot be obtained after enucleation, although local resections are associated with a decreased long-term endocrine and exocrine insufficiency when compared to typical pancreatic resections. In determining the optimal surgical resection for small tumors, we should weigh the balance between the risks and the benefits of the procedure. When performing lymphadenectomy, several studies have shown that tumors with a diameter of 1.0 cm to 2.0 cm have lymph node metastases in 6 to 33% of at resection [10, 11, 12, 13]. This small but measurable risk should be taken into account when considering resection of the tumor.

Tumors more than 2 cm diameter should be resected with negative margins including adjacent organs and regional lymph nodes. Tumors of the head of the pancreas are generally treated with pancreaticoduodenectomy, while tumors of the body and tail are treated with distal pancreatectomy. Distal pancreatectomy includes splenectomy for complete lymphadenectomy, but the appropriate extent of the lymphadenectomy has not been elucidated [14]. Laparoscopic resection is recommended as far as negative margin and adequate lymphadenectomy can be guaranteed [15, 16].

In the case of locally advanced PNETs, aggressive surgical resection is recommended [17]. Previous reports showed the survival benefits of an aggressive resection of PNETs when the tumor grade is G1 or G2 and no residual macroscopic disease is left [18].

**Treatment of Patients with Familial PNETs**

About 10% of patients with PNETs have a genetic background such as Multiple Endocrine Neoplasia type 1 (MEN1) or Von Hippel-Lindau syndrome (VHL) [2]. The most common MEN1 neoplasm is parathyroid hyperplasia (98% of patients), followed by islet cell tumors of the pancreas (50%), and pituitary adenomas (35%) [19]. The surgical management of patients with MEN1 is similar to those with sporadic tumors, however, these patients tend to have synchronous and metachronous multi-focal NETs in the pancreas as well as duodenum resulting in the need for a complex therapeutic strategy. There may be multiple hyperplasia to adenoma of islets throughout the pancreas [20, 21], and surgical resection should be carefully decided. While only a minority of microadenomas acquire the potential to grow, larger pancreatic lesions may be genetically unstable, develop secondary mutations and develop into clinically relevant lesions [22]. Therefore, surgical resection is considered if the tumor larger than 1-2 cm in size, and/or if the tumor has a relatively rapid rate of growth over 6 to 12 months.

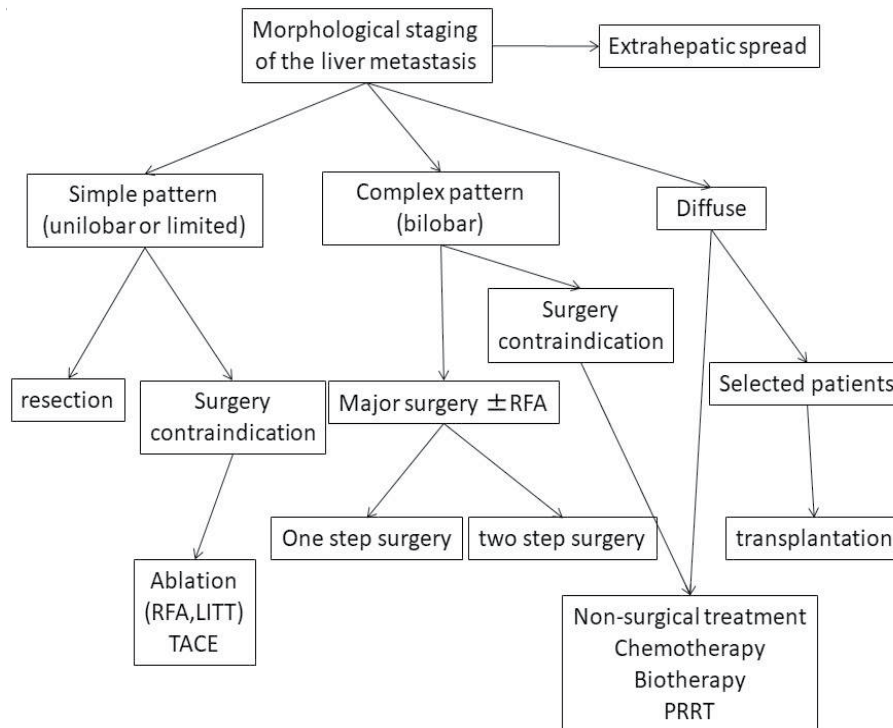
For patients with VHL, the life-limiting disease is usually a cerebellar haemangioblastoma or renal cell carcinoma [23]. Therefore, non-functioning PNETs in patients with VHL should be closely observed in relation to other lesions during progression of the VHL.

**Treatment of Non-Functioning PNETs with Metastases**

Surgical resection is generally proposed with curative intent in all patients with operable metastases from well differentiated PNETs. Most of the primary metastases of PNET reside in the liver, which is the main target of resection. There are two purposes for the resection. One is for treating symptoms, and the other is for survival. Most metastases from non-functioning PNETs are asymptomatic. However, some tumors secrete small but measurable amounts of hormones from metastatic sites and patients sometimes have symptoms due to these hormones. While debulking surgery may be useful for symptomatic metastases, only complete resection (R0 or R1) is associated with improved long-term survival, survival rates of 60–80% at 5 years may be achieved [24, 25, 26]. The long-term survival rate is approximately 30% when liver metastases are not resected [27, 28].

The extent of surgical resection is related to remnant liver function, the number and location of liver metastases, and the complexity of the liver resection (**Figure 1**). There are no prospective randomized controlled trials so far on this issue and bias in patient selection such as better performance status and less advanced disease could affect the reported outcomes. Mayo *et al.* performed a propensity matched analysis examining the relative efficacy of surgical management versus intra-arterial therapy (IAT) to determine factors which predict survival [29]. They observed that asymptomatic patients with a large (>25%) burden of liver disease benefited least from surgical management and IAT may be a more appropriate treatment strategy. Surgical management of liver metastases should be reserved for patients with low-volume disease or for those patients with symptomatic high-volume disease. They also found that the existence of extrahepatic disease in addition to liver metastases worsens overall survival, even after liver resection. The recurrence of metastases after resection is up to 100% with long-term follow-up [30, 31]. In this sense, resection of metastatic liver resection should be considered for selected patients with adequate performance status without life threatening comorbidities.

Recent advances in targeted therapy such as everolimus or sunitinib have prolonged progression free survival for about 11 months [32, 33]. Until now, there has been no randomized trial examining the appropriate category for resection of non-functioning metastatic tumors in comparison with such targeted drugs [34, 35].



**Figure 1.** Proposed treatment approach for liver-only metastases from neuroendocrine tumors (adapted from Ref [34, 35]).

LITT laser-induced thermotherapy; LMs liver metastases; RE radioembolization; RFA radiofrequency ablation; TAE transarterial embolization; TACE transarterial chemoembolization; 90Y yttrium-90

**CONCLUSION**

For non-functioning PNETs, localized, small, malignant tumors should be resected aggressively, while tumors smaller than 2 cm should be considered according to the surgical risk-benefit ratio. Surgical liver resection is generally proposed with curative intent for all patients with operable metastases, however, appropriate lymphadenectomy and the appropriate extent of resection for metastatic disease compared to other treatments are still to be elucidated.

**Conflicts of Interest**

The authors have declared that no conflicts of interest exist.

**References**

1. Kasumova GG, Tabatabaie O, Eskander MF, Tadikonda A, Ng SC, Tseng JF. National Rise of Primary Pancreatic Carcinoid Tumors: Comparison to Functional and Nonfunctional Pancreatic Neuroendocrine Tumors. *J Am Coll Surg* 2017; 224:1057-1064. [PMID: 27965134]
2. Ito T, Igarashi H, Nakamura K, Sasano H, Okusaka T, Takano K, et al. Epidemiological trends of pancreatic and gastrointestinal neuroendocrine tumors in Japan: a nationwide survey analysis. *J Gastroenterol* 2015; 50:58-64. [PMID: 24499825]
3. O'Toole D, Salazar R, Falconi M, Kaltsas G, Couvelard A, de Herder WW, et al. Rare functioning pancreatic endocrine tumors. *Neuroendocrinology* 2006; 84:189-195. [PMID: 17312379]
4. Falconi M, Plockinger U, Kwekkeboom DJ, Manfredi R, Korner M, Kvols L, et al. Well-differentiated pancreatic nonfunctioning tumors/carcinoma. *Neuroendocrinology* 2006; 84:196-211. [PMID: 17312380]
5. Kaltsas G, Androulakis, II, de Herder WW, Grossman AB. Paraneoplastic syndromes secondary to neuroendocrine tumours. *Endocr Relat Cancer* 2010; 17:R173-193. [PMID: 20530594]

6. Kulke MH, Shah MH, Benson AB 3rd, Bergsland E, Berlin JD, Blaszkowsky LS, et al. Neuroendocrine tumors, version 1.2015. *J Natl Compr Canc Netw* 2015; 13:78-108. [PMID: 25583772]
7. Sadot E, Reidy-Lagunes DL, Tang LH, Do RK, Gonen M, D'Angelica MI, et al. Observation versus Resection for Small Asymptomatic Pancreatic Neuroendocrine Tumors: A Matched Case-Control Study. *Ann Surg Oncol* 2016; 23:1361-1370. [PMID: 26597365]
8. Falconi M, Mantovani W, Crippa S, Mascetta G, Salvia R, Pederzoli P. Pancreatic insufficiency after different resections for benign tumours. *Br J Surg* 2008; 95:85-91. [PMID: 18041022]
9. Aranha GV, Shoup M. Nonstandard pancreatic resections for unusual lesions. *Am J Surg* 2005; 189:223-228. [PMID: 15720996]
10. Jutric Z, Grendar J, Hoen HM, Cho SW, Cassera MA, Newell PH, et al. Regional Metastatic Behavior of Nonfunctional Pancreatic Neuroendocrine Tumors: Impact of Lymph Node Positivity on Survival. *Pancreas* 2017; 46:898-903. [PMID: 28697130]
11. Gratian L, Pura J, Dinan M, Roman S, Reed S, Sosa JA. Impact of extent of surgery on survival in patients with small nonfunctional pancreatic neuroendocrine tumors in the United States. *Ann Surg Oncol* 2014; 21:3515-3521. [PMID: 24841347]
12. Curran T, Pockaj BA, Gray RJ, Halfdanarson TR, Wasif N. Importance of lymph node involvement in pancreatic neuroendocrine tumors: impact on survival and implications for surgical resection. *J Gastrointest Surg* 2015; 19:152-160; discussion 160. [PMID: 25118642]
13. Bettini R, Partelli S, Boninsegna L, Capelli P, Crippa S, Pederzoli P, et al. Tumor size correlates with malignancy in nonfunctioning pancreatic endocrine tumor. *Surgery* 2011; 150:75-82. [PMID: 21683859]
14. Conrad C, Kutlu OC, Dasari A, Chan JA, Vauthey JN, Adams DB, et al. Prognostic Value of Lymph Node Status and Extent of Lymphadenectomy in Pancreatic Neuroendocrine Tumors Confined To and Extending Beyond the Pancreas. *J Gastrointest Surg* 2016; 20:1966-1974. [PMID: 27714644]
15. Han SH, Han IW, Heo JS, Choi SH, Choi DW, Han S, et al. Laparoscopic versus open distal pancreatectomy for nonfunctioning pancreatic neuroendocrine tumors: a large single-center study. *Surg Endosc* 2017. [PMID: 28664429]
16. Xourafas D, Tavakkoli A, Clancy TE, Ashley SW. Distal pancreatic resection for neuroendocrine tumors: is laparoscopic really better than open? *J Gastrointest Surg* 2015; 19:831-840. [PMID: 25759075]

17. Haugvik SP, Labori KJ, Waage A, Line PD, Mathisen O, Gladhaug IP. Pancreatic surgery with vascular reconstruction in patients with locally advanced pancreatic neuroendocrine tumors. *J Gastrointest Surg* 2013; 17:1224-1232. [PMID: 23670519]
18. Fischer L, Bergmann F, Schimmack S, Hinz U, Prieß S, Müller-Stich BP, et al. Outcome of surgery for pancreatic neuroendocrine neoplasms. *Br J Surg* 2014; 101:1405-1412. [PMID: 25132004]
19. Giusti F, Marini F, Brandi ML. Multiple Endocrine Neoplasia Type 1. In: Pagon RA, Adam MP, Ardinger HH, et al., eds. *GeneReviews(R)*. Seattle (WA) 1993.
20. Kouvaraki MA, Shapiro SE, Cote GJ, Lee JE, Yao JC, Waguespack SG, et al. Management of pancreatic endocrine tumors in multiple endocrine neoplasia type 1. *World J Surg* 2006; 30:643-653. [PMID: 16680581]
21. Anlauf M, Schlenger R, Perren A, Bauersfeld J, Koch CA, Dralle H, et al. Microadenomatosis of the endocrine pancreas in patients with and without the multiple endocrine neoplasia type 1 syndrome. *Am J Surg Pathol* 2006; 30:560-574. [PMID: 16699310]
22. Triponez F, Dosseh D, Goudet P, Cougard P, Bauters C, Murat A, et al. Epidemiology data on 108 MEN 1 patients from the GTE with isolated nonfunctioning tumors of the pancreas. *Ann Surg* 2006; 243:265-272. [PMID: 16432361]
23. Hes FJ, Hoppener JW, Luijt RB, Lips CJ. Von hippel-lindau disease. *Hered Cancer Clin Pract* 2005; 3:171-178. [PMID: 20223044]
24. Sarmiento JM, Heywood G, Rubin J, Ilstrup DM, Nagorney DM, Que FG. Surgical treatment of neuroendocrine metastases to the liver: a plea for resection to increase survival. *J Am Coll Surg* 2003; 197:29-37. [PMID: 12831921]
25. Elias D, Lasser P, Ducreux M, Duvillard P, Ouellet JF, Dromain C, et al. Liver resection (and associated extrahepatic resections) for metastatic well-differentiated endocrine tumors: a 15-year single center prospective study. *Surgery* 2003; 133:375-382. [PMID: 12717354]
26. Chamberlain RS, Canes D, Brown KT, Saltz L, Jarnagin W, Fong Y, et al. Hepatic neuroendocrine metastases: does intervention alter outcomes? *J Am Coll Surg* 2000; 190:432-445. [PMID: 10757381]
27. Touzios JG, Kiely JM, Pitt SC, Rilling WS, Quebbeman EJ, Wilson SD, et al. Neuroendocrine hepatic metastases: does aggressive management improve survival? *Ann Surg* 2005; 241:776-783; discussion 783-775. [PMID: 15849513]
28. Kianmanesh R, O'Toole D, Sauvanet A, Ruzsniowski P, Belghiti J. Surgical treatment of gastric, enteric pancreatic endocrine tumors. Part 2. treatment of hepatic metastases. *J Chir (Paris)* 2005; 142:208-219. [PMID: 16335893]
29. Mayo SC, de Jong MC, Bloomston M, Pulitano C, Clary BM, Reddy SK, et al. Surgery versus intra-arterial therapy for neuroendocrine liver metastasis: a multicenter international analysis. *Ann Surg Oncol* 2011; 18:3657-3665. [PMID: 21681380]
30. Scigliano S, Lebtahi R, Maire F, Stievenart JL, Kianmanesh R, Sauvanet A, et al. Clinical and imaging follow-up after exhaustive liver resection of endocrine metastases: a 15-year monocentric experience. *Endocr Relat Cancer* 2009; 16:977-990. [PMID: 19470616]
31. Saxena A, Chua TC, Sarkar A, Chu F, Liauw W, Zhao J, et al. Progression and survival results after radical hepatic metastasectomy of indolent advanced neuroendocrine neoplasms (NENs) supports an aggressive surgical approach. *Surgery* 2011; 149:209-220. [PMID: 20674950]
32. Yao JC, Shah MH, Ito T, Bohas CL, Wolin EM, Van Cutsem E, et al. Everolimus for advanced pancreatic neuroendocrine tumors. *N Engl J Med* 2011; 364:514-523. [PMID: 21306238]
33. Raymond E, Dahan L, Raoul JL, Bang YJ, Borbath I, Lombard-Bohas C, et al. Sunitinib malate for the treatment of pancreatic neuroendocrine tumors. *N Engl J Med* 2011; 364:501-513. [PMID: 21306237]
34. Steinmuller T, Kianmanesh R, Falconi M, Scarpa A, Taal B, Kwkkeboom DJ, et al. Consensus guidelines for the management of patients with liver metastases from digestive (neuro)endocrine tumors: foregut, midgut, hindgut, and unknown primary. *Neuroendocrinology* 2008; 87:47-62. [PMID: 18097131]
35. Kennedy A, Bester L, Salem R, Sharma RA, Parks RW, Ruzsniowski P, et al. Role of hepatic intra-arterial therapies in metastatic neuroendocrine tumours (NET): guidelines from the NET-Liver-Metastases Consensus Conference. *HPB* 2015; 17:29-37. [PMID: 25186181]