

Successful Percutaneous Intervention for Chronic Total Occlusion of Left Subclavian Artery

Vishwanath Hesarur*

Department of Cardiology, Jawaharlal Nehru Medical College, KLES Dr Prabhakar ore Hospital and Medical Research Centre, KLE University, Belagavi, Karnataka, India

Abstract

Introduction: Subclavian artery stenosis is most commonly caused by atherosclerotic disease. Surgical treatment is associated with high morbidity and mortality. Intervention is generally reserved for the management of symptomatic patients who present with upper limb ischemia, Vertebrobasilar symptoms and subclavian steal syndrome. Endovascular stenting is preferred over surgery because of high success rate, less invasive and minimal complications.

Case report: Here we report a case of 56-year-old female patient with history of hypertension and diabetes presented with dizziness, vertigo and left arm claudication with use of her left upper extremity since last six months. She was diagnosed as a case of subclavian steal syndrome.

Treatment: Patient underwent successful Percutaneous Transluminal Angioplasty (PTA) of the left subclavian artery with marked improvement of symptoms at follow-up. Patient was monitored with Duplex ultrasound of left subclavian artery, measurement of BP and examination of pulse at each visit.

Conclusion: PTA is an effective and safe with high success rate, less invasive and minimal complications when compared to surgery for the treatment of symptomatic subclavian artery stenosis. However, regular clinical and duplex ultrasound assessment of subclavian artery is necessary after angioplasty for monitoring restenosis.

Keywords: Subclavian steal syndrome; Percutaneous transluminal angioplasty; Subclavian artery stenosis; Intervention; Atherosclerotic disease

*Corresponding author:

Vishwanath Hesarur

✉ drvishwanathesarur@yahoo.com

Assistant Professor, Department of Cardiology, Jawaharlal Nehru Medical College, KLES Dr Prabhakar Kore Hospital and Medical Research Centre, KLE University, Belagavi, Karnataka, India.

Tel: 0831 247 0732

Citation:

Hesarur V (2017)
Successful Percutaneous Intervention for
Chronic Total Occlusion of Left Subclavian
Artery. Interv Cardiol J. Vol.3 No.3:29

Received: October 25, 2017; **Accepted:** November 23, 2017; **Published:** November 30, 2017

Introduction

Subclavian artery stenosis is most commonly caused by atherosclerotic disease. Stenosis typically occurs in the first part of the subclavian artery proximal to the origin of the vertebral artery extending from the ostium to the origin of the vertebral artery. The incidence of left subclavian artery stenosis is far higher than that of right subclavian artery stenosis.

Intervention is generally reserved for the management of symptomatic patients who present with upper limb ischemia, Vertebrobasilar symptoms and subclavian steal syndrome. Endovascular stenting is preferred over surgery because of high

success rate, less invasive and minimal complications. Here we report a case of 56-year-old female patient presented with subclavian steal syndrome that we successfully treated with percutaneous transluminal angioplasty (PTA).

Case Report

A 56-year-old female patient with history of hypertension and diabetes presented with dizziness, vertigo and left arm claudication with use of her left upper extremity since last six months.

Physical examination

Inability to measure BP on left arm with absent left radial pulse

and right upper limb BP was 160/80 mmHg. There were no signs of ischemia in left upper extremity.

Investigations

Electrocardiogram showed sinus rhythm with no ST-T changes, transthoracic echocardiography revealed good biventricular function with type 1 diastolic dysfunction. Coronary angiography showed mild single vessel disease. Aortic arch angiography and selective left subclavian angiography revealed total occlusion of left ostio-proximal subclavian artery (**Figure 1**).

Procedure

The procedure was performed under local anaesthesia. The right femoral artery and left brachial artery were accessed percutaneously with 8F and 6F introducer sheaths, respectively. A preprocedural loading dose of Aspirin 325 mg and 600 mg of clopidogrel was given. Intravenous heparin 100 IU/kg and antibiotic were given.

Ostia of left subclavian artery was engaged by using JR 7F guiding catheter. Check angio showed total occlusion. A 6F shuttle sheath was used to cannulate the vessel and placed distal to the occlusion. The lesion was crossed retrogradely using 0.014 × 190 cm cross-it 200 and placed in proximal descending aorta (**Figure 2A**). Lesion was predilated using 3.5 × 15 mm balloon at 8 atm pressure (**Figure 2B**). Check angiogram through JR guiding catheter established good antegrade flow with no dissection (**Figure 2C**). Using another 0.014 × 180 cm BMW wire crossed the lesion antegradely and the cross-it 200 wire removed (**Figure 2D**). An 8 × 32 mm INVATEC scuba stent was deployed across ostio-proximal subclavian artery (**Figure 2E**) with a good angiographic result (**Figure 2F**).

Post procedure course was uneventful. The patient was discharged after three days with Aspirin 150 mg OD, Clopidogrel 75 mg BD and Rosuvastatin 20 mg OD.

Follow-up

Patient was followed up at 1, 3, 6 months and one year. Patient reported marked improvement of symptoms. At each visit, patient was monitored with Duplex ultrasound of left subclavian artery, measurement of BP and examination of pulse.

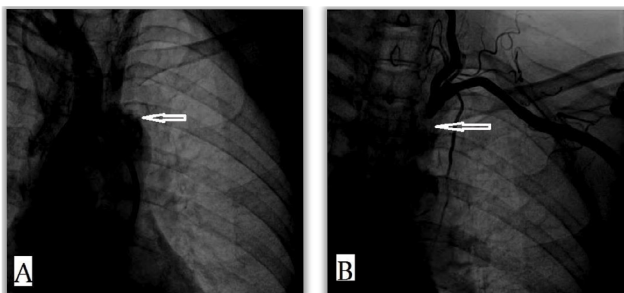


Figure 1 Aortic arch angiography showing (A) selective left subclavian artery (B) and total occlusion (arrow) of left ostio-proximal subclavian artery.

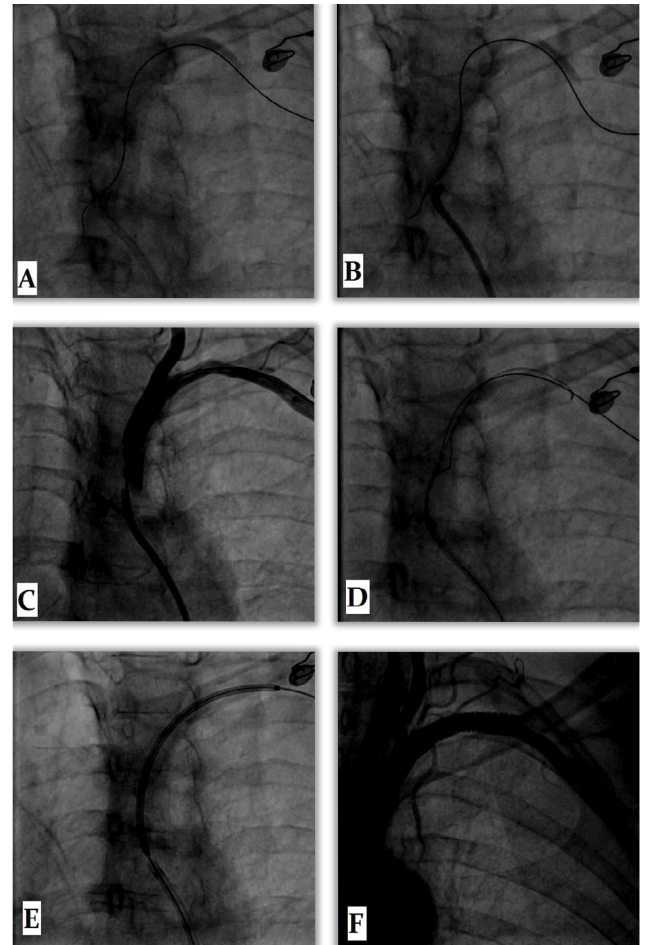


Figure 2 (A) Lesion crossed retrogradely (B) Predilatation of lesion (C) Good antegrade flow (D) BMW wire crossed antegradely (E) Stent Placement and (F) Final result.

Discussion

Atherosclerosis is the most common cause of subclavian stenosis and, thus, steal syndromes, irrespective of the clinical manifestation [1-3]. However, other causes include large artery vasculitis, thoracic outlet syndrome, and stenosis after surgical repair of coarctation of aorta or tetralogy of Fallot.

The presence of subclavian stenosis is associated with increased total mortality (hazard ratio, 1.40) and cardiovascular disease mortality (hazard ratio, 1.57) [2] and with an increased risk of cerebrovascular ischemic events related to progressive carotid stenosis and compromised collateral pathways. Thus, subclavian artery stenosis is a cardiovascular risk marker and requires aggressive secondary prevention.

Even asymptomatic subclavian artery stenosis is associated with increased risk of morbidity and mortality related to underlying atherosclerotic disease burden in other vascular beds [2-4].

Symptomatic patients with proximal subclavian artery occlusive disease can be successfully treated either surgically or percutaneously [5,6-12].

First case report of subclavian angioplasty was done by Bachman and Kim in 1980 [13]. After this report, percutaneous intervention of subclavian disease has grown persistently, becoming the mainstay of therapy. Balloon angioplasty and stenting can be performed when stenting is unlikely to compromise the vertebral circulation. Technical success of the percutaneous approach can be achieved in >90%, with 5-year patency rates of 85% [12]. Complications during subclavian artery intervention are stroke (<1%), dissection, access site complications (0% to 5%) like hematoma formation, thrombosis and pseudoaneurysm formation.

The major long-term risk of subclavian artery intervention is restenosis. Stenting appears to have significantly reduced the rate of restenosis, from 15% to 20% with angioplasty to 0% to 10%. The treatment for restenosis will depend on its etiology. Failure to cover the ostium or inadequate stent expansion may be treated with repeat angioplasty and, sometimes, re-stenting. Alternatively, surgical revascularization using an extra thoracic

approach (carotid–subclavian, axillo-axillary) is a reasonable option in a symptomatic patient who is an operative candidate.

Conclusion

PTA is an effective and safe with high success rate, less invasive and minimal complications when compared to surgery for the treatment of symptomatic subclavian artery stenosis. However, regular clinical and duplex ultrasound assessment of subclavian artery is necessary after angioplasty for monitoring restenosis.

Conflict of Interest

The author(s) declare(s) that there is no conflict of interest regarding the publication of this paper.

Informed Consent

Written informed consent was obtained from patient for publication of this case report and accompanying images.

References

- 1 Ochoa VM, Yeghiazarians Y (2011) Subclavian artery stenosis: A review for the vascular medicine practitioner. *Vasc Med* 16: 29-34.
- 2 Aboyans V, Kamineni A, Allison MA, McDermott MM, Crouse JR, et al. (2010) The epidemiology of subclavian stenosis and its association with markers of subclinical atherosclerosis: The Multi- Ethnic Study of Atherosclerosis (MESA). *Atherosclerosis* 211: 266-270.
- 3 Labropoulos N, Nandivada P, Bekelis K (2010) Prevalence and impact of the subclavian steal syndrome. *Ann Surg* 252: 166-170.
- 4 Clark CE, Taylor RS, Shore AC, Ukoumunne OC, Campbell JL (2012) Association of a difference in systolic blood pressure between arms with vascular disease and mortality: A systematic review and meta-analysis. *Lancet* 379: 905-914.
- 5 Rogers JH, Calhoun RF (2007) Diagnosis and management of subclavian artery stenosis prior to coronary artery bypass grafting in the current era. *J Card Surg* 22: 20-25.
- 6 Babic S, Sagic D, Radak D, Antonic Z, Otasevic P, et al. (2012) Initial and long-term results of endovascular therapy for chronic total occlusion of the subclavian artery. *Cardiovasc Intervent Radiol* 35: 255-262.
- 7 Burihan E, Soma F, Iared W (2011) Angioplasty versus stenting for subclavian artery stenosis. The Cochrane database of systematic reviews. CD008461.
- 8 De Vries JP, Jager LC, Van den Berg JC, Overtoom TT, Ackerstaff RG, et al. (2005) Durability of percutaneous transluminal angioplasty for obstructive lesions of proximal subclavian artery: Long-term results. *J Vasc Surg* 41:19-23.
- 9 Filippo F, Francesco M, Francesco R, Corrado A, Chiara M, et al. (2006) Percutaneous angioplasty and stenting of left subclavian artery lesions for the treatment of patients with concomitant vertebral and coronary subclavian steal syndrome. *Cardiovasc Intervent Radiol* 29: 348-353.
- 10 Salam TA, Lumsden AB, Smith RB (1994) Subclavian artery revascularization: A decade of experience with extrathoracic bypass procedures. *J Surg Res* 56: 387-392.
- 11 Song L, Zhang J, Li J, Gu Y, Yu H, et al. (2012) Endovascular stenting vs. extrathoracic surgical bypass for symptomatic subclavian steal syndrome. *J Endovasc Ther* 19: 44–51.
- 12 Wang KQ, Wang ZG, Yang BZ, Yuan C, Zhang WD, et al. (2010) Long-term results of endovascular therapy for proximal subclavian arterial obstructive lesions. *Chin Med J (Engl)* 123: 45-50.
- 13 Bachman DM, Kim RM (1980) Transluminal dilatation for subclavian steal syndrome. *AJR Am J Roentgenol* 135: 995-996.