

# SMARCA4-Deficient Undifferentiated Uterine Sarcoma: A Case Report

Murakami I<sup>1</sup>, Tanaka K<sup>1\*</sup>,  
Shiraishi J<sup>2</sup> and Yamashita H<sup>3</sup>

## Abstract

A rare subset of aggressive SMARCA4-deficient uterine sarcomas has been recently proposed, with only a few cases having previously been described. We describe a case of SMARCA4-deficient uterine sarcoma with aggressive behavior in a patient who underwent surgery. A 57 year-old women presented with abnormal vaginal bleeding and a large mass protruding through the cervix. On histopathological examination, the tumor was composed of epithelioid cells displaying prominent rhabdoid morphology reminiscent of epithelioid sarcoma that infiltrated around normal glands in a vague leaf-like architecture. The tumor cells were large and epithelioid with prominent nucleoli and abundant mitotic activity. Immunohistochemical staining revealed loss of SMARCA4, CD34, WT-1, and claudin-4 with retained SMARCB1 and cyclin D1. The tumor was diagnosed as SMARCA4-deficient uterine sarcoma. The patient died of the disease 7 months after surgery. We herein present this case with a literature review.

**Keywords:** Immunohistochemical Stain; Prognosis; SMARCA4; SMARCB1; Uterine Sarcoma

**Received:** March 15, 2021; **Accepted:** April 16, 2021; **Published:** April 23, 2021

## Introduction

Inactivation of SMARCA4, a member of the SWI/SNF chromatin remodeling complex, has recently been proposed to occur in a rare subset of undifferentiated uterine sarcomas with rhabdoid morphology and aggressive behavior [1,2]. Because of its unique clinicopathological, morphological, and molecular features, SMARCA4-deficient uterine sarcoma may be a new uterine sarcoma type [3]. However, to our knowledge, fewer than 20 cases of SMARCA4-deficient uterine sarcoma have been reported in the literature to date. In this study, we present a rare case of SMARCA4-deficient uterine sarcoma and a concise review of the imaging and clinicopathological presentation of patients with SMARCA4-deficient uterine sarcoma.

## Case Report

A 57-year-old G<sub>0</sub>P<sub>0</sub> woman presented to our department with chronic vaginal bleeding that had started 6 months previously and acute heavy vaginal bleeding that had occurred over the past 2 days. Computed tomography (CT) of the chest, abdomen, and pelvis demonstrated an enlarged lobular uterus with a large midline pelvic mass and retroperitoneal and pelvic lymphadenopathy. Magnetic resonance imaging (MRI) of the pelvis with contrast

- 1 Department of Obstetrics and Gynecology, Toho University Ohashi Medical Center, Tokyo, Japan
- 2 Department of Pathology, National Hospital Organization Tokyo Medical Center, Tokyo, Japan
- 3 Department of Obstetrics and Gynecology, National Hospital Organization Tokyo Medical Center, Tokyo, Japan

\*Corresponding author: Kyoko Tanaka

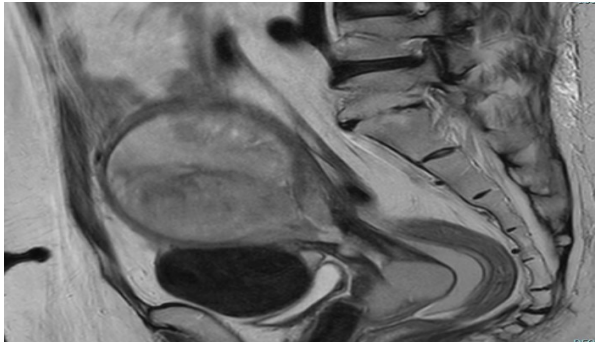
✉ kyoko.tanaka@med.toho-u.ac.jp

Department of Obstetrics and Gynecology, Toho University Ohashi Medical Center, 2-22-36 Oohashi, Meguro-Ku, Tokyo 153-8515, Japan.

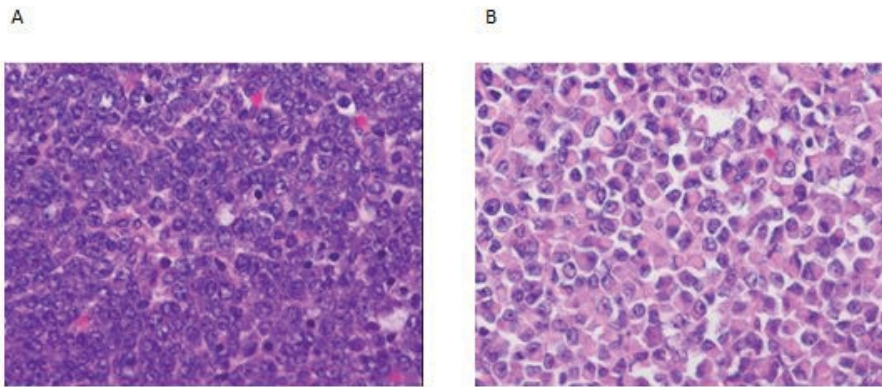
Tel: +81-3-5433-3060; Fax +81-3-5433-3061

**Citation:** Murakami I, Tanaka K, Shiraishi J, Yamashita H (2021) SMARCA4-Deficient Undifferentiated Uterine Sarcoma: A Case Report. *Gynecol Obstet Case Rep* Vol.7 No.4:128

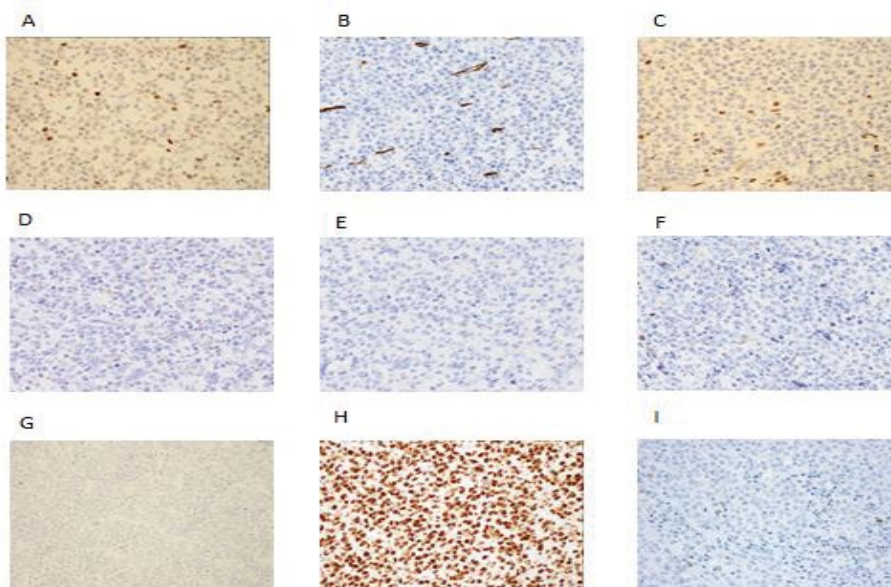
confirmed a large uterine mass suspicious of malignancy, with a metastatic ovarian tumor with multiple likely metastatic pelvic and retroperitoneal lymph nodes (**Figure 1**). The patient underwent a hysterectomy, bilateral salpingo-oophorectomy, and removal of the peritoneal dissemination. Grossly, a 14 cm mass arose from the endometrium that invaded through >90% of the myometrial thickness and extended to the parametrial and paracervical resection margins. Microscopically, the tumor was composed of epithelioid cells displaying a prominent rhabdoid morphology reminiscent of epithelioid sarcoma that infiltrated around normal glands in a vague leaf-like architecture (**Figure 2**). There was extensive lymphovascular invasion. The tumor had metastasized to the bilateral ovaries. Immunohistochemistry showed that loss of SMARCA4, negativity for CD34, SMARCA2, SALL4, cytokeratin AE1/AE3, WT-1, and claudin 4. SMARCB1 and cyclin D1 were positively stained (**Figure 3**). The tumor was



**Figure 1** Sagittal magnetic resonance imaging showing a large heterogeneous mass centered within the uterus and cervix (solid arrows). The mass showed mixed signal intensity on T2-weighted images, heterogeneous enhancement with increased signal intensity on DW1, and decreased signal intensity on ADC maps.



**Figure 2** Tumor cells were atypical yet monomorphic, with prominent nucleoli and large nuclei, and were composed of discohesive rhabdoid cells. Abundant mitotic activity was evident (200x, A, B).



**Figure 3** Immunohistochemistry showed negativity for SMARCA4 (A) CD34 (B) SMARCA2 (C) SALL4 (D) cytokeratin AE1/AE3 (E) WT-1 (F) and claudin-4 (G) SMARCB1 (H) and cyclin D1 (I) were positively stained (200x).

diagnosed as SMARCA4-deficient uterine sarcoma. The patient received several courses of doxorubicin (Adriamycin) but died of the disease 7 months after surgery.

## Discussion

Uterine sarcoma is a rare type of uterine cancer that is estimated to account for between 3% and 5% of all neoplasms of the uterine corpus [4,5]. The incidence of uterine sarcoma ranges from 1.55 to 1.95 per 100000 women per year [5]. Uterine sarcomas are classified into two groups: mesenchymal tumors, and mixed epithelial and mesenchymal tumors [4,5]. SMARCA4-deficient uterine sarcoma is a newly discovered undifferentiated uterine mesenchymal malignancy with unique clinicopathological features [4]. Patients with SMARCA4-deficient uterine sarcoma often present with vaginal bleeding [2,6]. Moreover, SMARCA4-deficient uterine sarcoma shares many clinicopathological features of small cell carcinoma of the ovary, including young age, aggressive clinical behavior, morphological resemblance to the large cell variant of small cell carcinoma of the ovary, and loss of SMARCA4 expression.

The clinical manifestations of SMARCA4-deficient uterine sarcoma are non-specific, and imaging is usually required for diagnosis. However, the imaging characteristics of SMARCA4-deficient uterine sarcoma have not been described. MRI should be performed to assess the local invasion of the lesion. T2-weighted MRI is considered superior to CT and ultrasonography for detecting myometrial invasion [7,8]. MRI may show a heterogeneous signal-intensity endometrial mass with low-intensity bands scattered in areas of myometrial involvement and intramyometrial worm-like nodular extensions, indicating myometrial and lymphovascular invasion of the tumor [7]. CT is mainly required for disease staging of distal metastasis [9].

Diagnosis of SMARCA4-deficient uterine sarcoma is usually based on morphology, loss of SMARCA4 staining demonstrated by anti-SMARCA4 antibody, and retained/intact SMARCB1. The distinction between undifferentiated endometrial carcinoma and SMARCA4-deficient uterine sarcoma is important, because a previous study reported the possibility of anti-PD-1 immunotherapy use in SMARCA4-deficient uterine sarcoma [10]. Lack of SWI/SNF complex expression detected by immunohistochemical staining is a necessary but not a sufficient

requirement for the diagnosis of SMARCA4-deficient uterine sarcoma [11]. On histology, SMARCA4-deficient uterine sarcoma typically shows diffuse sheets of medium-to-large epithelioid cells with areas of rhabdoid morphology, corded architecture with stromal hyalinization, and focal phyllodiform architecture [12]. Immunohistochemistry could be helpful in diagnosing SMARCA4-deficient uterine sarcoma. SMARCA4-deficient uterine sarcoma is frequently negative for WT-1. Moreover, SMARCA4-deficient uterine sarcoma lacks significant epithelial marker expression, including keratin, epithelial membrane antigen (EMA), cytokeratin 7 (CK7), and claudin-4, which differentiates it from endometrioid carcinoma [2]. Claudin-4 has recently been shown to be a marker of epithelial differentiation, and may remain expressed in undifferentiated and poorly differentiated carcinomas that have rhabdoid morphology; however, claudin-4 is negative in small cell carcinoma and SWI/SNF-deficient sarcoma [13]. This finding suggested that it may be an effective marker to distinguish it from rhabdoid carcinoma. Endometrial stromal tumors show strong staining of CD10 and cyclin D1, which are not found or are rarely found in SMARCA4-deficient uterine sarcoma [14]. Kolin et al. [2] suggested that when faced with a poorly differentiated uterine sarcoma with rhabdoid cells, claudin-4, cyclin D1, and SMARCA4 immunohistochemistry could be used if genomic studies are not available.

## Conclusion

In conclusion, SMARCA4-deficient uterine sarcoma defines a highly aggressive subset of undifferentiated endometrial carcinomas with rapid disease progression. Efforts should be pursued to standardize the care of patients with SMARCA4-deficient uterine sarcoma, perhaps with practice guidelines. We anticipate that population-level data such as these will be the first step in this process.

## Acknowledgment

We thank H. Nikki March, PhD, from Edanz Group (<https://en-author-services.edanz.com/ac>), for editing a draft of this manuscript.

## Conflict of Interest

No potential conflicts of interest relevant to this article are reported.

## References

- 1 Lin DI, Allen JM, Hecht JL, Jonathan KK, Nhu TN, et al. (2019) SMARCA4 inactivation defines a subset of undifferentiated uterine sarcomas with rhabdoid and small cell features and germline mutation association. *Mod Pathol* 32: 1675-1687.
- 2 Kolin DL, Dong F, Baltay M, Neal L, Laura M, et al. (2018) SMARCA4-deficient undifferentiated uterine sarcoma (malignant rhabdoid tumor of the uterus): A clinico-pathologic entity distinct from undifferentiated carcinoma. *Mod Pathol* 31: 1442-1456.
- 3 Ferreira J, Félix A, Lennerz JK, Oliva E (2018) Recent advances in the histological and molecular classification of endometrial stromal neoplasms. *Virchows Arch* 473: 665-678.
- 4 Momeni-Boroujeni A, Chiang S (2020) Uterine mesenchymal tumours: Recent advances. *Histopathol* 76: 64-75.
- 5 Trope CG, Abeler VM, Kristensen GB (2012) Diagnosis and treatment of sarcoma of the uterus: A review. *Acta Oncol* 51: 694-705.
- 6 Kolin DL, Quick CM, Dong F (2020) SMARCA4-deficient uterine sarcoma and undifferentiated endometrial carcinoma are distinct clinicopathologic entities. *Am J Surg Pathol* 44: 263-270.
- 7 Huang YT, Huang YL, Ng KK, Lin G (2019) Current status of magnetic

- resonance imaging in patients with malignant uterine neoplasms: A review. *Korean J Radiol* 20: 18-33.
- 8 Santos P, Cunha TM (2015) Uterine sarcomas: A clinical presentation and MRI features. *Diagn Interv Radiol* 21: 4-9.
  - 9 Huang YL, Ueng SH, Chen K (2019) Utility of diffusion-weighted and contrast-enhanced magnetic resonance imaging in diagnosing and differentiating between high- and low-grade uterine endometrial stromal sarcoma. *Cancer Imaging* 19: 63-65.
  - 10 Jelinic P, Ricca J, Van Oudenhov E, Narciso O, Taha M, et al. (2018) Immune-active microenvironment in small cell carcinoma of the ovary, hypercalcemic type: Rationale for immune checkpoint blockade. *NCI J Natl Cancer Inst* 110: 787-790.
  - 11 Köbel M, Hoang LN, Tessier-Cloutier B (2018) Undifferentiated endometrial carcinomas show frequent loss of core switch/sucrose non-fermentable complex proteins. *Am J Surg Pathol* 42: 76-83.
  - 12 Clement PB, Scully RE (1990) Mullerian adenosarcoma of the uterus: A clinico-pathologic analysis of 100 cases with a review of the literature. *Hum Pathol* 21: 363-381.
  - 13 Schaefer IM, Agaimy A, Fletcher CD, Jason LH (2017) Claudin-4 expression distinguishes SWI/SNF complex-deficient undifferentiated carcinomas from sarcomas. *Mod Pathol* 30: 539-548.
  - 14 Oliva E, Young RH, Amin MB, Clement PB (2002) An immunohistochemical analysis of endometrial stromal and smooth muscle tumors of the uterus: a study of 54 cases emphasizing the importance of using a panel because of overlap in immunoreactivity for individual antibodies. *Am J Surg Pathol* 26: 403-412.