



Pelagia Research Library

European Journal of Experimental Biology, 2014, 4(2):182-187



Self mutilation in a traumatized cymric cat

Davood Sharifi^{1*} and Habib Golezardy²

¹Department of Veterinary Surgery and Radiology, Faculty of Veterinary Medicine, University of Tehran, Tehran, Iran

²Lavasan Specialized Veterinary Poly-Clinic, Lavasan, Iran

ABSTRACT

A case of 10 months old of a Cymric male cat, with 2.450 Kg/body weight, which was horribly had traumatized by accident was presented for plegia and in coordination in cyanotic condition, for diagnosis and systemic support. The radiographic interpretation from thoracic and lumbosacral region revealed multiple fractures of left wing of pelvic bone, dislocation of left hip joint, separation of left tuber coxae and complete separation of pelvic symphysis. Clinical checked up showed, the few minutes scratches on both legs skin and missing completely left paw, due to his aggressive behaviors and self mutilation a day before surgery were noticed. The pelvic internal fragmental alignment was done. The cat regained full consciousness after 6 hours, and then showed inclination for drinking and food tasting. The weak groaning intermediate sound used to be heard during recovery period, despite of repeated analgesic medication, the cat was left in the cage with control ambient temperature in soft bedding, due to unknown reason cat started to show very unexpected aggressive behaviors and tried to self mutilate himself, sudden projecting bleeding from right paw and severe agitation, leading to severe hypovolemia and dyspnea. Cyanotic oral mucosal and rigidity of limbs muscles, and ultimate death of the cat.

Keywords: Cat, mutilation.

INTRODUCTION

Self mutilation is quite a rare thing to see in cats. It can be an extension of over grooming or the expression of deep stress and in some cases a neurological disorder, environmental distributing behavior, allergic to flea bites and even psychological thing, which sounds like a horrible topic. Cats are like human in a lot of ways, but they have less need for social interaction than humans do. Some time they may have a life of stress with other cats [1-3]. Cats have a unique set of nerve responses around their mouths that make them highly adapted predators. They are custom made to attack their food. Cats in stressful environments can manifest this urge on themselves by self-mutilation. It can become an obsessive-compulsive disorder (OCD) [4-6]. Thus their natural aggression becomes self-directed and these problems can worsen. Treatment for OCD involves medications or means giving them something else to do, instead of hunting, stalking, and pouncing on their own bodies and amusing them for chewing, sometime offering them a rawhide chew or even a beef bone with a bit of meat still attached. But it should be differentiated from Feline hyperesthesia syndrome (FHS) has been variously called rolling skin disease, neuritis, twitchy cat disease, and atypical neurodermatitis. In some cases, the behaviors demonstrated can include those mimicking estrus or biting at

the tail, flank, anal or lumbar areas (sometimes with resultant barbering and self-mutilation) [7-9]; or skin rippling and muscle spasms/twitching (usually dorsally), often accompanied by vocalization, running, jumping, hallucinations and self-directed aggression. Not all cats exhibiting these behaviors self-mutilate, but those that do can exhibit a range of mutilation from excessive licking, to plucking (trichotillomania), barbering, biting, and chewing that lead to skin lesions. Regardless of the degree of behavioral change, the literature reports so far coded indicated that it is difficult to distract the cat from the behavior. The behavior sequence can vary. Cats might twitch and then focus on a part of the body to lick or chew. Or they might be grooming, start to twitch, and then exhibit more furious behaviors. Painful and dermatological causes must be ruled-out before even considering the possibility of a behavioral disorder. Environmental and social stresses have been associated with these disorders and range from readily apparent (skin conditions including food allergy, atop, or fleas, the addition or loss of another cat, intercat aggression, the addition or loss of a human with attendant changes in attention); to indiscernible exogenous cues. Cats may also perceive truly endogenous cues and anxiety can be the result of altered neurochemistry/neurotransmission and can therefore also be endogenous [10-14].

METHODS AND RESULTS

A case of 10 months old Cymric male horribly traumatized due to accident, with 2.450 kg/body weight, was presented for plegia and incoordination in cyanotic condition for clinical checked up, diagnosis and systemic support. The radiographic interpretation from thoracic and lumbosacral region revealed multiple fractures of left pelvic bone, dislocation of left hip joint, separation of left tuber coxae and complete separation of pelvic symphysis (Figure 1).

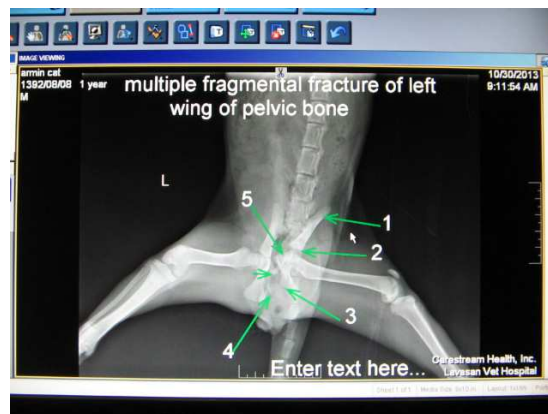


Figure- 1. Radiography of pelvic showing complete separation of left wing of pelvic

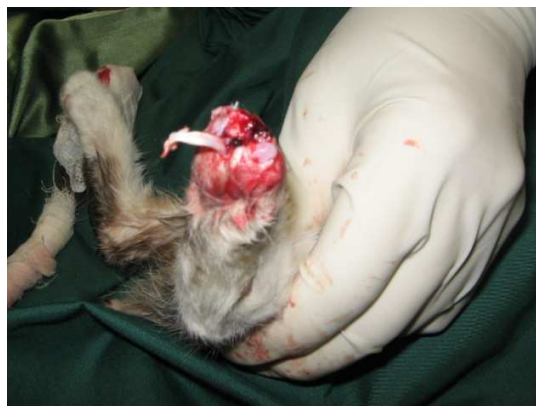

Figure- 2. Self mutilation of left paw before surgery

The few minute scratches on both legs skin and missing completely left paw (Figure 2) due to his aggressive behaviors and self mutilation a day before surgery were noted.

The pelvic internal fragmental alignment was done by aligning the larger fragment of left greater ilium, using 8 holes finger bone plate and additionally a single 3 cm cancellous full threaded screw to stabilize the both ilium to the first sacral vertebral bone (Figure 3), using 8 holes finger bone plate and additionally a single 3 cm cancellous full threaded screw was used to stabilize the both ilium to the first sacral vertebral bone (Figure 4).

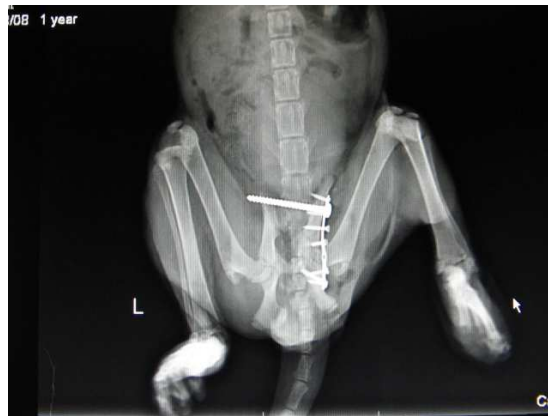

Figure- 3. Internal alignment of separated left wing of pelvic

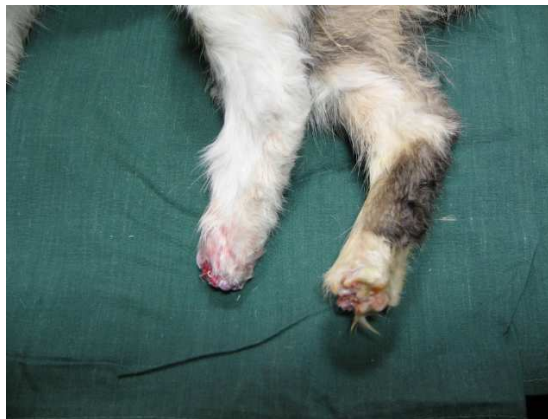

Figure- 4. Self mutilation of right paw after recovery

The cat was supported with fluid therapy (100 ml, slow I.V) Tramadol (50mg/1ml, Tehran Chemie Pharmaceutical Co. Tehran. Iran), Clemastine (2 mg/2 ml, Mino Pharmaco-Co) Furosemide (lasix, 2 mg/kg tid, Abouraihan Pharma. Co Tehran. Iran) and Cefzolib (Cefazolin, 20 mg/kg IV bid; Jaber-eben Hayan, Tehran, Iran).The recovery was supported using heating pad. The cat regained full conscious after 6 hours, then showed inclination for drinking and food .The cat was left in the cage with control ambient temperature with soft bedding, due to unknown reason cat started to show unexpected aggressive behaviors and tried to self mutilate again itself, severe bleeding from right paw which was eaten up by cat itself (no trace of paw pieces found) leading to severe hypovolemia, following vital organ hypoxia and death of the cat. (Figures 4, 5).

DISCUSSION AND CONCLUSION

There is no fundamental difference between man and the higher animals in their mental faculties. The lower animals, like man, manifestly feel pleasure and pain, happiness, and misery. All animals are believed to be imbued with an innate drive for self-preservation. The term is synonymous with “self-injury” [1-3] and the most common form of self-harm is skin-cutting but self-harm also covers a wide range of behaviors including, but not limited to,

burning, scratching, banging or hitting body parts, interfering with wound healing, hair-pulling (trichotillomania) and the ingestion of toxic substances or objects [2,4,5]. Behaviors associated with substance abuse and eating disorders are usually not considered self-harm because the resulting tissue damage is ordinarily an unintentional side effect [6,14,15].

The influence of rearing history on the development of self-harm among primates. What that means is that there's no evidence that the way one grows up or is parented (yes there are parallels to monkey and human parenting and psychological development) affects whether an individual turns to self-harm to cope with anxiety. But the single most common denominator among animals that self-harm is isolation social isolation. Primates bite themselves, parrots pull out their feathers and dogs and cats lick themselves. Such self-injurious behavior tends to occur in emotionally disturbing situations, particular those over which the individual has little or no control.

Monkeys, birds, people and pets are all very social creatures. Preening and self-grooming is one way animals and people cope with anxiety. Self-touch is soothing but a poor substitute for contact with others [16,17]. Self-injurious behavior is notoriously difficult to treat. It's compulsive behavior that defies behavioral interventions largely because a psychologist or therapist can't be present 100% of the time to remind people to replace their harmful habit with a helpful one. That's one reason why drug therapies are so popular. They are effective, with beta blockers being the most effective because they block the mood enhancing endorphins that are released during injury. Those who self harm are addicted to it behaviorally and physiologically [18-20]. Self-harm is not limited to humans. Captive non-human animals, such as birds, horses and monkeys, are also known to participate in self-harming behavior [20]. Self-harm in non-human mammals is a well-established but not widely known phenomenon. Its study under zoo or laboratory conditions could lead to a better understanding of self-harm in human patients [20]. Scientists have noted for years that primates in captive situations are prone to self-mutilation, especially if kept in solitary conditions. Rhesus macaques may bite themselves and many studies have been done attempting to explain this behavior. Scientists think that self-injury in primates may occur when the subject is extremely bored. A bored animal may pace and offer stereotypical behavior that eventually involves biting at their own flesh being seen in this case. Primates that are extremely frustrated may also present self-harming behaviors. If the animal cannot escape or attack when something or someone induces fear, it may bite itself in the same spot repeatedly. These injuries will start small and eventually become obvious [21-23]. Sometimes the animals may even lose limbs because the damage is so severe. Some animals in our homes may even self-mutilate. Parrots are known for over-preening, feather plucking and even picking open their flesh with their beaks. Feather plucking is often a symptom of boredom. Parrots are highly intelligent creatures and with nothing to do but preen, they eventually get overzealous. Moments of high stress can also trigger plucking. However, just like with Scheiderman and her hair pulling, sometimes the reason why a parrot plucks remains a mystery and a difficult behavior to overcome. Zoo or laboratory rearing and isolation are important factors leading to increased susceptibility to self-harm in higher mammals, e.g., macaque monkeys [20,24,25]. Lower mammals are also known to mutilate themselves under laboratory conditions after administration of drugs. In dogs, canine obsessive-compulsive disorder can lead to self-inflicted injuries, for example canine lick granuloma. In horses, in addition to biting the flanks, self-mutilation sequences can include seemingly uncontrollable violent behavior. From horse to horse, the sequence and form can vary, but most typically includes spinning in circles, bucking, and kicking out with one or both back legs while nipping at the flank, shoulders, or chest. In extreme cases, the horse can violently lunge its body or head into a wall or other solid object. More rarely, a horse might "throw itself" to the ground (from standing to lateral recumbency). A single episode can last from a few seconds to several minutes, uninterrupted. The horse can work up lather and steam in cool weather. Episodes usually occur in a series separated by a few seconds to a few minutes over a period of minutes, to hours. The total daily time spent self-mutilating can vary from a few seconds to an hour or more. In addition to bite wounds, the most common injuries are to the legs and feet from the spinning and kicking since self-mutilation occurs in other animal species and a variety of human psychopathologic syndromes, it's probably too early to conclude that any of the self-mutilation seen in horses represents the same pathology as Tourette's in people. In other species, the trend in clinical veterinary behavior has been to label self-mutilative behavior "obsessive-compulsive disorder", or OCD [26].

Breeders of show mice have noticed similar behaviors. One known as "barbering" involves a mouse obsessively grooming the whiskers and facial fur off of themselves and cage-mates. Other behaviors include scratching ears so severely, that large sections are lost. Different etiological and predisposing factors being suggested and reported by owners and scientific papers, genetical and gender differences, toxic drugs administration, autonomic nervous system stimulation, even generating alternative behavior, long term cage poisoning, and organic brain diseases being

suggested as positive factors for self mutilation in animal even in cats. Chronically self-mutilation such as chewing tail for years. Initially may be due to allergies and treated may be with steroid injections. Even it leads to nerve damage in tail showing little sensation; only tingling. Suggested option is to remove tail, because in continuation the cat may chew it due to the nerve damage. Although tail chewing can be caused by allergies, this behavior can be a symptom of a few other conditions. Because of the chronic nature and the severity of cat's condition, but it should be differentiated from possibility of feline hyperesthesia syndrome (FHS). Hyperesthesia means "abnormally increased sensitivity of the skin". FHS is more common in oriental breed cats (Siamese, Abyssinian, and the like) and Oriental breed mixed. FHS generally manifests itself in cats between the ages of 1 and 4 years. Some vets believe feline hyperesthesia syndrome may be a form of obsessive-compulsive disorder that begins as a reaction to stress and anxiety in the cat's life. Others believe FHS is a form of seizure disorder because of the symptoms that precede an episode of self-mutilation including hallucinating, yowling, skin rippling, running and jumping, and muscle twitching, cats with FHS may show strange behaviors if touched, such as tail chasing or biting at the tail, flank and sides, to the point of self-directed aggression. FHS can cause extreme self-mutilation such as biting, licking, chewing, and plucking of the hair, primarily on the back and the tail. This illness is usually a "diagnosis of exclusion", meaning that your vet has to rule out any other physical illnesses that could cause this behavior. These other illnesses include allergies, skin diseases or external parasites (some cats react very strongly to flea bites, for example), and internal problems like back pain, arthritis, spinal problems, muscle diseases, nutritional deficiencies (particularly the B vitamin thiamine, which is very important to a healthy nervous system), or problems with the thyroid, kidneys or liver. Cats generally recover and adapt very well to amputations. They don't have the same kind of psychological issues humans do when they lose a limb. Self-mutilation behavior of one form or another has been described in many different species, including humans. Dog and cats lick and chew on their paws or tails. People do all sorts of things-pull out their hair, bite their fingernails or lips, scratch themselves, or deliberately inflict burns, cuts, or other wounds This behavior commonly is called flank biting or flank sucking [2,4,6,26]. The biting is one aspect of a cluster of behaviors called self-mutilation, because the horse likely will incur serious self-injury during these explosive episodes [26,27].

Acknowledgements

Authors wish to express sincere thanks for moral responsibility and financial support of Mrs. Tehrani, one the sincere pioneer and active member of Animal Care Society for adaptation and hospital expenses.

REFERENCES

- [1] Beaver BV, *Feline Behaviour: A Guide for Veterinarians*, W.B. Saunders Company, Sydney, **1992**.
- [2] Borchelt PL, Voith VL, *The Compendium on Continuing Education*, **1981**, 3, 730–738.
- [3] Bradshaw JWS, *The Behaviour of the Domestic Cat*, C.A.B International UK, **1992**.
- [4] Caro TM, *Behaviour* **1981**, 76, 3–24.
- [5] Feldman HN, *Animal Behaviour*, **1993**, 45, 13–23.
- [6] Klonsky ED, *Clinical Psychology Review*, **2007**, 27, 226–239.
- [7] Muehlenkamp JJ, *American Journal of Orthopsychiatry*, **2005**, 75, 324–333.
- [8] Fox MW, *The Behaviour of Domestic Animals*, Baillière Tindall, **1975**.
- [9] Hart BL, *Feline behaviour: A practitioner monograph*. Practice Publishing Co., California, **1980**.
- [10] Joshua JO, *Abnormal Behaviour in Animals*, W.B.Saunders Co., Philadelphia, London, Toronto, **1965**.
- [11] Swales M, *The Welcome Trust*, retrieved, **2005**, 5-26.
- [12] Jones IH, Barraclough BM, *Acta Psychiatrica Scandinavica*, **2007**, 58, 40–47.
- [13] Remmers JE, Gautier H, *Respiratory Physiology*, **1972**, 16, 351–361.
- [14] Schwartz S, *Canine and Feline Behavioural Problems*, Mosby, St Louis, **1997**.
- [15] Thorne C, *The Waltham Book of Dog and Cat Behaviour*, Pergamon Press, UK, **1992**.
- [16] Turner DC, Bateson P, *The Domestic Cat: The Biology of its Behaviour*, Cambridge University Press, **2000**.
- [17] Voith VL, *Modern Veterinary Practice*, **1981**, 951–953.
- [18] Johnson CP, Myers SM, *Pediatrics*, **2007**, 120, 1183–215.
- [19] Rossow I, Hawton K, Ystgaard M, *Archives of Suicide Research*, **2009**, 13, 340–348.
- [20] Bowen ACL, John AMH, *Counselling Psychology Quarterly*, **2001**, 14, 357–379.
- [21] Mueller K, Nyhan WL, *Pharmacology, Biochemistry and Behaviour*, **1983**, 18, 891–894.
- [22] Kies SD, Devine DP, *Pharmacology, Biochemistry and Behaviour*, **2004**, 79, 587–598.
- [23] Dodman NH, Normile JA, Shuster L, Rand W, *J Am Med Assoc*, **1994**, 204, 1212-1223.
- [24] Line SW, Hart BL, Sanders L, *J Am Med Assoc*, **1985**, 186, 249-251.

[25] Luescher UA, Mc Keown DB, Halip J, *Vet Med*, **1991**, 527-530.

[26] Curtis WD, *A practical guide to canine and feline neurology*, Wiley-Blackwell, **2003**.

[27] Jacquie R, *Problem-based feline medicine*, Elsevier Health Sciences, **2006**.