

CASE REPORT

Radiofrequency Ablation of Unresectable Pancreatic Carcinoma: Feasibility, Efficacy and Safety

Subodh Varshney¹, Ajit Sewkani¹, Sandesh Sharma¹, Sorabh Kapoor¹, Saleem Naik¹,
Abhishek Sharma¹, Kailash Patel²

Departments of ¹Surgical Gastroenterology and ²Radiology.
Bhopal Memorial Hospital and Research Centre. Bhopal, MP, India

ABSTRACT

Context Unresectable pancreatic cancer has a dismal prognosis. Palliative surgery and chemo-radiotherapy have not produced significant improvement in survival. We evaluated the safety and the efficacy of radiofrequency ablation for cytoreduction of unresectable tumors of the pancreas.

Case report Radiofrequency ablation was performed in three patients with histologically proven unresectable cancer of the pancreas: two females and one male; 48, 60, and 66 years of age (mean 58 years). The sizes of the pancreatic tumors were 5.0, 6.5, and 8.0 cm (mean 6.5 cm), respectively. Two patients underwent radiofrequency ablation during an open operation while one patient had percutaneous CT guided radiofrequency ablation. All had endobiliary stenting for obstructive jaundice. Partial necrosis (up to 3 cm) of the tumor was achieved in all cases. There was no major morbidity or mortality. Self-limiting minor complications occurred in two patients.

Conclusion Radiofrequency ablation is a local ablative method used with increasing frequency and may be used safely for cytoreduction in locally advanced inoperable pancreatic malignancies. Further studies are required to ascertain whether this can improve survival/quality of life alone or in combination with other therapies.

INTRODUCTION

Cancer of the pancreas is the fifth most lethal cancer in the world. Only 10% are confined to the pancreas at the time of presentation, 40% are locally advanced and another 50% have distant metastases [1]. The overall prognosis of unresectable pancreatic cancer is poor [2]. Palliative measures have not produced significant improvement in survival [3, 4]. Chemotherapy and radiation have minimal benefit in these patients [5]. Radiofrequency ablation (RFA) is being successfully used in the treatment of unresectable solid tumors in the liver [6, 7, 8, 9, 10], lung [11, 12], breast [13, 14], kidney [15], adrenal glands [16], spleen [17], prostate [18], bone [19], brain [20], and intrahepatic cholangiocarcinoma [21]. RFA of locally advanced pancreatic cancer as a cytoreductive means is a new treatment option with only a few studies found in the medical literature [22, 23].

We evaluated the feasibility, efficacy, safety and complications of radiofrequency ablation in unresectable pancreatic cancer.

PATIENTS AND METHODS

Between May 2001 and July 2003, three patients (two women and one man; 48, 60, and 66 years of age, (mean 58 years) with a large unresectable mass in the head or uncinate process of the pancreas underwent RFA. The sizes of the lesions were 5.0, 6.5, and 8.0 cm (mean 6.5 cm), respectively. All 3 patients presented with surgical obstructive

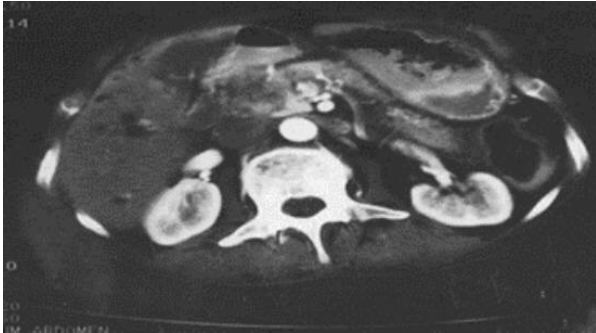


Figure 1. Pre radiofrequency ablation contrast enhanced computed tomography demonstrating large pancreatic head malignancy.

jaundice and abdominal pain. Contrast-enhanced computed tomography (CECT) of the abdomen and pelvis according to pancreatic protocol was performed in all 3 patients. The reason for unresectability was encasement and infiltration into the portomesenteric (superior mesenteric and/or portal vein) vessels in all 3 patients. In addition, one patient had a history of stroke and ischemic heart disease, rendering her unfit for any major operative procedure. Endobiliary stenting was carried out in all three patients to relieve jaundice. Histological confirmation of the diagnosis was obtained in all 3 patients before RFA (percutaneous CT-guided needle biopsy in two patients and biopsy during side viewing endoscopy in the third).

We used a Berchtold RF generator (Tuttlingen, Germany), generating 40-60 W of power. Radiofrequency needle was placed in the center of the tumor under CT guidance (n=1) or during open operation, under intra-operative ultrasound guidance (n=2). Approximately 4,200 W of energy was delivered using a saline perfused needle with the aim of producing a necrosis 3 cm diameter in the tumor. Intra-operative monitoring of the coagulated tissue was done with intra-operative ultrasound. All patients received antibiotics for seven days (ciprofloxacin 500 mg *bid* and metronidazole 400 mg *tid*). Patients were screened for development of pancreatitis by serial serum amylase and lipase at 24 and 48 hours after the procedure. Patients were discharged from the hospital on day five after the percutaneous approach and

on day 10 after the open procedure. A follow-up CECT of the abdomen was performed between two and four weeks after the procedure in order to evaluate the extent of the necrosis of the ablated area. (Figures 1 and 2).

RESULTS

Partial necrosis (up to 3 cm) was achieved in all cases of locally advanced cancer of the pancreas. There was no major procedure-related morbidity or mortality. Two patients had minor complications: self-limiting ascites in one patient (with normal ascitic fluid amylase) and a 2 cm asymptomatic pseudocyst in another patient which was seen on follow-up ultrasonography. Neither patient required any treatment. Two patients had reduced abdominal pain two weeks after the procedure.

Follow-up

One patient died following massive myocardial infarction one month after RFA. This patient had a history of ischemic heart disease and cerebrovascular accident. Another two patients survived for 9 and 11 months, respectively; they died from progression of the disease and widespread metastases.

DISCUSSION

Pancreatic cancer is the third most common gastrointestinal malignancy. It is a disease with an extremely poor prognosis. Large

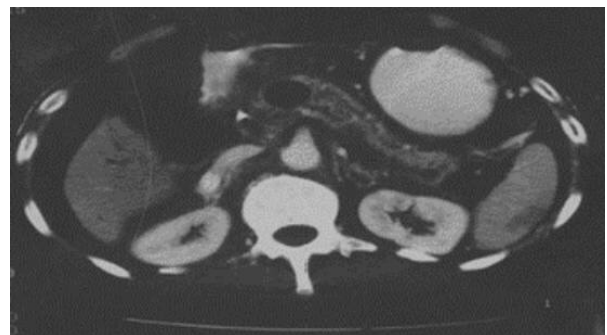

Figure 2. Post radiofrequency ablation contrast enhanced computed tomography demonstrating 3 cm diameter necrosed (non enhancing) area.

series of patients with pancreatic cancer suggest that only 5-22% are resectable at the time of presentation [1]. Median survival for unresectable pancreatic cancer is about 4-6 months [3]. Surgical resection is the only potentially curative treatment for pancreatic cancer. Porto-mesenteric involvement is a relative contraindication for resection. Morbidity and mortality after pancreatectomy with vascular reconstruction can be substantial, with no significant survival benefit [2]. Palliative R1 or R2 resectional surgery for locally advanced pancreatic cancer has not shown any survival benefit in larger series with survival ranging from 10.5-20 months [24]. Chemoradiation generally has minimal symptomatic improvement in these patients [4]. Trials of chemotherapy with or without radiotherapy have shown some improvement in symptoms and quality of life, without significant improvement in survival [25]. Side effects and complications from chemotherapy and radiotherapy should also be considered.

In all our patients, we were able to achieve cytoreduction by producing tumor necrosis 3 cm diameter. RFA has been commonly used for liver [6, 7, 8, 9, 10] and lung [11, 12] tumors where resection is not advisable or refused. RFA has also been used for small breast cancers [13, 14] and renal tumors [15]. The applications of RFA are slowly increasing and have been extended to cancers of the adrenal gland [16], spleen [17], prostate [18], bone [19], and brain [20].

A multi-institutional study published in 1990 shows the efficacy of hyperthermia in advanced or inoperable cancer of deep seated organs including the pancreas [22]. Matsui *et al.* [23] used RFA in 20 cases of unresectable pancreatic cancer and concluded that the procedure is safe but further trials are required to check the efficacy of the procedure. Falk *et al.* [26], in 77 patients having unresectable cancer of the pancreas, demonstrated that radiofrequency hyperthermia reduces the dose of chemotherapy, with an improvement in response to treatment. Goldberg *et al.* [27] studied the safety and efficacy of RFA in experimental models, and concluded that

RFA can be used in small neuroendocrine tumors and possibly palliation of unresectable pancreatic cancer. Date *et al.* [28] demonstrated the safety and efficacy of RFA in the normal pancreas of a porcine model. Elias *et al.* [29] reported two cases of multiple pancreatic metastases from renal tumors treated with RFA; unfortunately both patients developed severe necrotizing pancreatitis and died. The mortality in their series was probably due to multiple ablations which led to severe pancreatitis. Spillotis *et al.* [30] recently reported good results using RFA in five patients with inoperable pancreatic cancer.

RFA of pancreatic tumors has the danger of inducing various complications such as acute pancreatitis, a pancreatic fistula, pancreatic ascites, etc. No such complications were seen in our series because we ensured that the normal pancreatic tissue was not ablated, thus avoiding chances of acute pancreatitis and a pancreatic fistula. In our series, one patient died after one month from an unrelated cause and two survived for 9 months and 11 months. It is very difficult to comment on improvement in survival, because of the small numbers involved.

CONCLUSION

Our study on a small sample of patients demonstrated that RFA of unresectable pancreatic tumors is feasible and safe with minimum morbidity and mortality. The ablated area should be restricted within the tumor to avoid chances of acute pancreatitis or a pancreatic fistula. This method can be used as a cytoreductive measure in an adjuvant setting with the aim of better palliation in locally advanced pancreatic malignancies. Further studies of radiofrequency ablative cytoreduction therapy with or without chemotherapy and chemoradiation are warranted to study the benefit of RFA on survival and quality of life in unresectable pancreatic cancer.

Received November 12th, 2005 - Accepted November 25th, 2005

Keywords Catheter Ablation; Pancreas; Pancreatic Neoplasms

Abbreviations RFA: radiofrequency ablation; CECT: contrast enhanced computed tomography

Correspondence

Subodh Varshney
Department of Surgical Gastroenterology and
Clinical Nutrition
Bhopal Memorial Hospital and Research
Centre
Raisen Bypass Road, Karond
Bhopal, MP
India, 462038
Phone: +91-755.278.9940; +91-982.607.8994
Fax +91-755-278.9963
E-mail: subodhvarshney@rediffmail.com

References

1. Singh SM, Longmire WP Jr, Reber HA. Surgical palliation for pancreatic cancer. The UCLA experience. *Ann Surg* 1990; 212:132-9. [PMID 1695834]
2. Allema JH, Reinders ME, van Gulik TM, van Leeuwen DJ, de Wit LT, Verbeek PC, Gouma DJ. Portal vein resection in patients undergoing pancreatoduodenectomy for carcinoma of the pancreatic head. *Br J Surg* 1994; 81:1642-6. [PMID 7827892]
3. Sarr MG, Cameron JL. Surgical palliation of unresectable carcinoma of the pancreas. *World J Surg* 1984; 8:906-18. [PMID 6083677]
4. Hussain D, Khan MR, Azami R. Surgical palliation for unresectable pancreatic carcinoma. *J Pak Med Assoc* 2004; 54:601-4. [PMID 16104485]
5. Whittington R, Neuberg D, Tester WJ, Benson AB 3rd, Haller DG. Protracted intravenous fluorouracil infusion with radiation therapy in the management of localized pancreaticobiliary carcinoma: a phase I Eastern Cooperative Oncology Group Trial. *J Clin Oncol* 1995; 13:227-32. [PMID 7799024]
6. Varshney S, Sharma S, Pamecha V, Sewkani A, Jhawar L, Narkhede V, et al. Radiofrequency tissue ablation: an early Indian experience. *Indian J Gastroenterol* 2003; 22:91-3. [PMID 12839380]
7. Zhang Z, Wu M, Chen H. Percutaneous radiofrequency ablation of liver malignancies. *Zhonghua Wai Ke Za Zhi* 2001; 39:749-52. [PMID 16201185]

8. Huo TI, Huang YH, Wu JC. Percutaneous ablation therapy for hepatocellular carcinoma: current practice and future prospectives. *J Chin Med Assoc* 2005; 68:155-9. [PMID 15850062]
9. Jansen MC, van Hillegersberg R, Chamuleau RA, van Delden OM, Gouma DJ, van Gulik TM. Outcome of regional and local ablative therapies for hepatocellular carcinoma: a collective review. *Surg Oncol* 2005; 31:331-47. [PMID 15837037]
10. Lencioni R, Crocetti L. A critical appraisal of the literature on local ablative therapies for hepatocellular carcinoma. *Clin Liver Dis* 2005; 9:301-14. [PMID 15831275]
11. Simon CJ, Dupuy DE. Current role of image-guided ablative therapies in lung cancer. *Expert Rev Anticancer Ther* 2005; 5:657-66. [PMID 16111466]
12. Suh RD, Wallace AB, Sheehan RE, Heinze SB, Goldin JG. Unresectable pulmonary malignancies: CT guided percutaneous radiofrequency ablation – preliminary results. *Radiology* 2003; 229:821-9. [PMID 14657317]
13. Noguchi M. Minimally invasive surgery for small breast cancer. *J Surg Oncol* 2003; 84:94-101. [PMID 14502783]
14. Singletary ES. Feasibility of radiofrequency ablation for primary breast cancer. *Breast Cancer* 2003; 10:4-9. [PMID 12525756]
15. Boss A, Clasen S, Kuczyk M, Anastasiadis A, Schmidt D, Graf H, et al. Magnetic resonance-guided percutaneous radiofrequency ablation of renal cell carcinoma: a pilot clinical study. *Invest Radiol* 2005; 40:583-90. [PMID 16118551]
16. Wood BJ, Abraham J, Hvizda JL, Alexander HR, Fojo T. Radiofrequency ablation of adrenal tumors and adrenocortical carcinoma metastases. *Cancer* 2003; 97:554-60. [PMID 12548596]
17. Milicevic M, Bulajic P, Zuvella M, Raznatovic Z, Obradovic V, Lekic N, et al. Elective resection of the spleen- overview of resection technics and description of a new technic based on radiofrequency coagulation and dessication. *Acta Chir Iugosl* 2002; 49:19-24. [PMID 12587443]
18. Shariat SF, Raptidis G, Masatoschi M, Bergamaschi F, Slawin KM. Pilot study of radiofrequency interstitial tumor ablation (RITA) for the treatment of radio-recurrent prostate cancer. *Prostate* 2005; 65:260-7. [PMID 16015591]
19. Martel J, Bueno A, Ortiz E. Percutaneous radiofrequency treatment of osteoid osteoma using cool tip electrode. *Eur J Radiol* 2005. [PMID 15964164]
20. Gananadha S, Wulf S, Morris DL. Safety and efficacy of radiofrequency ablation of brain: a potentially minimally invasive treatment for brain

tumors. *Minim Invasive Neurosurg* 2004; 47:325-8. [PMID 15674746]

21. Chiou YY, Hwang JI, Chou YH, Wang HK, Chiang JH, Chang CY. Percutaneous ultrasound guided radiofrequency ablation of intrahepatic cholangiocarcinoma. *Kaohsiung J Med Sci* 2005; 21:304-9. [PMID 16089307]

22. Kakehi M, Ueda K, Mukojima T, Hiraoka M, Seto O, Akanuma A, et al. Multi-institutional clinical studies on hyperthermia combined with radiotherapy or chemotherapy in advanced cancer of deep seated organs. *Hyperthermia* 1990; 6:719-40. [PMID 2203848]

23. Matsui Y, Nakagawa A, Kamiyama Y, Yamamoto K, Kubo N, Nakase Y. Selective thermocoagulation of unresectable pancreatic cancers by using radiofrequency capacitive heating. *Pancreas* 2000; 20:14-20. [PMID 10630378]

24. Smeenk HG, Incrocci L, Kazemier G, van Dekken H, Tran KT, Jeekel J, et al. Adjuvant 5-FU-based chemoradiotherapy for patients undergoing R-1/R-2 resections for pancreatic cancer. *Dig Surg* 2005; 22:321-8. [PMID 16254431]

25. Ishii H, Okada S, Tokuyue K, Nose H, Okusaka T, Yoshimori M, et al. Protracted 5-fluorouracil infusion

with concurrent radiotherapy as a treatment for locally advanced pancreatic carcinoma. *Cancer* 1997; 79:1516-20. [PMID 9118032]

26. Falk RE, Moffat FL, Lawler M, Heine J, Makowka L, Falk JA. Combination therapy for respectable and unresectable adenocarcinoma of the pancreas. *Cancer* 1986; 57:685-8. [PMID 3943007]

27. Goldberg SN, Mallery S, Gazelle GS, Brugge WR. EUS-guided radiofrequency ablation in the pancreas: results in a porcine model. *Gastrointest Endosc* 1999; 50:392-401. [PMID 10462663]

28. Date RS, Biggins J, Paterson I, Denton J, McMahon RF, Siriwardena AK. Development and validation of an experimental model for the assessment of radiofrequency ablation of pancreatic parenchyma. *Pancreas* 2005; 30:266-71. [PMID 15782106]

29. Elias D, Baton O, Sideris L, Lasser P, Pocard M. Necrotizing pancreatitis after radiofrequency destruction of pancreatic tumors. *Eur J Surg Oncol* 2004; 30:85-7. [PMID 14736529]

30. Spiliotis JD, Datsis AC, Chatzikostas P, Kakeos SP, Christopoulou AN, Rogdaki AG, et al. Pancreatic cancer palliation using radiofrequency ablation. A new technique. *Cancer Ther* 2005; 3:379-82.