

(The abstracts are published as submitted by the authors)

ORAL COMMUNICATIONS

**Prophylactic Administration of Somatostatin (SS) or Gabexate (GM)
Does not Prevent Pancreatic Damage after ERCP.**

An Updated Meta-Analysis

Andriulli A, Leandro G, Caruso N, Ippolito A, Forlano R, Iacobellis A, Annese V

Gastroenterology, 'Casa Sollievo Sofferenza' and 'De Bellis' Hospitals.

San Giovanni Rotondo and Castellana Grotte, Italy

Context In 2000 we produced a meta-analysis with positive effects of SS and GM administration in reducing post-ERCP injury.

Aims To update the meta-analysis by including 9 additional, randomized clinical trials (RCTs) of higher quality and larger sample size on the same topic, published over the past 6 years. **Results** In 9 RCTs on SS, 1,213 patients were controls and 1,144 treated with SS, only the incidence of hyperamylasemia (36% vs. 31%, respectively; OR=0.73, CI: 0.60-0.89; NNT=15, CI: 9-41; publication bias = 11) was significantly reduced, whereas that of pancreatitis (7.3% vs. 6.1%; OR=0.83, CI: 0.60-1.14), and pain (11% vs. 9.0%; OR=0.78, CI: 0.56-1.07) was not. A sensitivity analysis was carried-out on schedules of drug administration: a bolus infusion of SS proved effective in reducing pancreatitis (12% vs. 3.2%; OR=-0.08; CI: -0.03 to -0.13), whereas an infusion <6 h (6.3% vs. 8.0%), or an infusion >12 h (6.2%

vs. 3.1%) were not. In 5 RCTs, 1,117 controls and 1,102 GM-treated patients were included. Incidence of pancreatitis (5.7% vs. 4.8%), hyperamylasemia (40% vs. 38%), and pain (10% vs. 8.8%) did not differ. By subgrouping data according to schedules of GM administration, a <6 h and a >12 h infusion proved ineffective: 6.1% vs. 6.0%, and 5.1% vs. 2.8%. **Conclusion** The benefit of SS in reducing post-ERCP hyperamylasemia is of no clinical value as the major outcome (post-ERCP pancreatitis) was unaffected. The beneficial effect of a single bolus of SS, but not of a short- or long-term infusion, is inconsistent with the timing of insurgence of pancreatic damage, reported to start at the time the procedure is being carried out. This updated meta-analysis disproves the value of both SS and GM as prophylactic measure for post-procedural pancreatic damage.

**Intraductal Papillary Mucin-Producing Tumors (IPMT) of the
Pancreas: Role of MR in Predicting Malignancy**

**Baltieri S¹, Graziani R¹, Manfredi R¹, Tognolini A¹, Cicero C¹, Salvia R², Pederzoli P²,
Pozzi Mucelli R¹**

¹Department of Radiology and ²Department of Surgical and Gastroenterological Sciences,
University of Verona. Verona, Italy

Context Preoperative assessment malignancy of intraductal papillary mucinous tumors

(IPMT) of the pancreas is often difficult. We analyse the MR role in identifying malignant

IPMT. Aim To determine those MR imaging criteria of IPMTs are indicative of malignancy. **Methods** 33 consecutive patients with histologically-proven IPMT, both of the main pancreatic duct (MPD) and of the side branches (SB), were retrospectively enrolled in this study. All patients underwent Gd-enhanced MR imaging and MRCP. Qualitative image analysis included: presence/absence of pancreatic duct dilation; type of duct involved (MPD/SB/both); site of ductal dilation in relation to pancreatic gland (head, body, tail) to pancreatic ducts (MPD/SB/both); dependant/non-dependant endoductal filling defects; ductal wall enhancement; vascular infiltration (tumor adhesion $<$ or $>180^\circ$), liver metastases, and ascites. Quantitative image analysis included: maximal diameter of the MPD/SB. All patients underwent surgery. Tumors were subdivided in malignant or benign according to the surgico-pathologic examination. A multivariate statistical analysis was performed to identify those parameters that have higher likelihood to indicate malignancy. **Results**

Ductal dilation was observed in all patients. The dilation involved MPD in 9/33, SB in 6/33, both ducts in 18/33. Ductal dilation was localized in head in 5/33 patients, in body-tail in 13/33 patients and in both sites in 15/33 patients. Overall, endoductal filling defects were observed in 25/33: 12/25 in the MPD and 7/25 in the SB, 6/25 in both ducts. Dependant endoductal filling defects were observed in 15/25; ductal wall enhancement was observed in 19/33 with nodular pattern in 14/19 and diffuse pattern in 5/19. Vascular adhesion was noted in 10/33: $>180^\circ$ in 8/10 and $<180^\circ$ in 2/10; liver metastasis were present in 2/33 and ascites in 1/33. The mean size of MPD was 32 mm (range: 10-120 mm) of the SB 28 mm (range: 10-50 mm). Dilation of the MPD in the tail or diffuse as well as ductal wall enhancement were significantly associated with malignancy ($P<0.05$, respectively). **Conclusion** The main distinctive features of malignancy are dilation of the MPD in the tail and ductal wall enhancement.

Pancreatic Surgery in Italy

Balzano G, Capretti G, Zerbi A, Rocchetti S, Milani F, Di Carlo V

Pancreas Unit, Department of Surgery, S. Raffaele Scientific Institute, Milan, Italy

Context A volume/outcome relationship for pancreaticoduodenectomy has been demonstrated in various studies. **Aim** To evaluate if pancreatic surgery in Italy is characterised by a volume/outcome relationship like in other Western Countries. Outcome was measured by operative mortality and postoperative stay. **Methods** Analysis of data from the nationwide database of the Italian Ministry of Health on inpatient discharges. In 2003, 2,933 patients underwent pancreatic surgery in Italy. To analyse only standardised procedures, 352 operations were excluded because of: 1) equivocal codification, or 2) diagnosis of acute pancreatitis/trauma. The analysis was therefore made on 2,581 patients. Data were stratified according to different operations and

to the pancreaticoduodenectomy (PD) volume of the hospital. Volume stratification was made by 4 categories, with the following criteria: 2 hospitals with a very high PD volume were grouped, because they could not be considered homogeneous with the others (+68% and +107% PD with respect to the 3rd hospital for PD volume); the other 3 categories were obtained by dividing the remaining hospitals in tertiles: low-volume ≤ 5 PD, medium-volume 6-13 PD, high-volume 14-51 PD. Analysis was made by logistic regression and Mann-Whitney test. **Results** There were 1,576 PD, 472 left pancreatectomy (LP), 180 derivative operations (DO), 127 total pancreatectomy (TP) and 226 other resections. Overall mortality rate was 7.1%. Mortality by

operation was: 8.1% after PD, 2.8% after LP, 2.8% after DO, 17.3% after TP, 6.6% after other resections. Stratifying by hospital volume, mortality was related to volume, either considering PD ($P<0.001$, $OR=1.54$), and considering altogether the remaining pancreatic surgery ($P<0.01$, $OR=1.47$). Mortality after the single operations by volume were (from low- to very high-volume): PD: 12.4%, 7.8%, 5.9% and 2.6%; LP: 2.6%, 3.8%, 2.7% and 0%; DO: 5.1%, 3.2%, 0% and 0%; TP: 18.2%, 23.7%, 13.2% and 0%; other resections: 9.9%, 8.3%, 7.7% and 0%. Also mean postoperative stay (days) was inversely related to volume for every operation (PD: 22, 22, 21, 18 days; LP: 14,

14, 15, 12 days; DO: 14, 11, 11, 10 days; TP: 21, 19, 25, 17 days; other resections: 19, 19, 21, 13 days); when comparing the 2 high-volume hospitals with the remaining ones, the reduction of stay was significant for each operation. If all patients could receive the same treatment quality of patients treated at the 2 high-volume hospitals, 78% of death would be prevented (145 patients/year), and 8,204 days/year of hospital stay would be saved. **Conclusions.** Italian data confirm the clear volume-outcome relationship for pancreatic surgery. Strategies must be developed to define a number of 'excellence pancreatic surgery centres', where referring pts with pancreatic diseases.

The Chimera of Radicality in Pancreatic Cancer Resection

Beneduce AA¹, Balzano G¹, Zerbi A¹, Reni M², Rocchetti S¹, Cereda S², Albarello L³,
Di Carlo V¹

Pancreas Unit, Departments of ¹Surgery, ²Oncology, and ³Pathology,
S. Raffaele Scientific Institute. Milan, Italy

Context Pancreatic cancer has a dismal prognosis even in patients undergoing resection. This is partially justified by the aggressive behaviour of this cancer: 70-80% of resected cases had metastatic lymphnodes, and margin invasion is reported in up to 50% of cases. **Aim** To describe the frequency and pattern of relapse in pancreatic cancer patients in which resection achieved an apparent radicality, namely patients with either negative resection margins (R0) and negative lymphnodes (N0). **Methods** Retrospective evaluation of prospectively collected data. Between January 1995 and December 2004 we performed 354 pancreatic resections for ductal pancreatic adenocarcinoma. Pathologic evaluation of resection margins was made by multiple axial sections after inking the specimen margins. 45 patients (12%) resulted R0-N0, but 7 of them were excluded because they had less than 10 nodes isolated in the surgical specimen (NX). Another patient was lost at follow-up at 12 months. The remaining 37 patients were the object of the study. Disease failure was assessed by CT scan

performed every 3-4 months after surgery, or when recurrent disease was suspected. Survival analysis was made by the Kaplan-Meier curves and log-rank test. **Results** Patients were treated by 31 pancreaticoduodenectomies and 6 distal pancreatectomies. 97% of patients (36/37) were T3N0, and 3% (1/37) was T1N0. Despite the favourable histological pattern, only 38% of patients (14/37) are still disease free with a median follow-up of 58 months. (range: 24-130 months). Disease-free survival and overall median survival (MS) were 25 and 29 months, respectively with a 5-year survival of 32%. A recurrence of disease was detected in overall 62% of patients: 11 patients (30%) had local relapse and 15 patients (40%) had distant metastases (8% of them had both local and distant metastases). Stratifying the study group by age, tumour size, grading and adjuvant CT, tumour size <2.3 cm was a significant prognostic factor (MS: 54 and 24 months, $P<0.05$); and age >63 years was almost a significant favourable factor ($P=0.07$). When comparing the study group

with the remaining resected patients, there was a significant difference in disease-free and overall survival ($P < 0.001$), and in the overall recurrence rate (81% vs. 62%, $P < 0.05$), indicating that the advantage of R0N0 patients with respect of other patients is mainly in a longer disease-free survival, and less in the probability to survive to the disease. **Conclusions** Radicality is a chimera

in pancreatic cancer resection, since most of R0N0 patients will die of the disease. Even an accurate pathologic evaluation fails to certify the achievement of local radicality, since 30% of R0N0 patients had local recurrence. Furthermore, 40% of R0N0 patients had occult distant metastases at the time of resection.

Clinical, Radiological and Histological Findings in Patients with Intraductal Papillary Mucin Neoplasia

Bernardoni L, Katsotourchi A, Scattolini C, Bovo P, Vaona B, Pravadelli C, Ierace S, Frulloni L, Vantini I

Chair of Gastroenterology, University of Verona. Verona, Italy

Context Intraductal papillary mucinous neoplasms of the pancreas (IPMN) have recently been identify. Therefore, they have been increasingly recognized and their natural history differs from pancreatic adenocarcinoma (AC). IPMN may be misdiagnosed with chronic pancreatitis (CP).

Aim To analyze the clinical findings and the natural course of the IPMN. **Material and Methods** We enrolled patients with a diagnosis of IPMN based on histological or radiological findings, observed between 2000 and 2005. We collected epidemiological, clinical, biochemical, radiological and histological data from all patients enrolled.

Results None of the IPMN patients was heavy drinker (more than 80 g alcohol/day) and only 17% smoked 14 ± 7 cigarettes/day. The clinical onset of the diseases was epigastric pain (35%), acute pancreatitis (39%), whereas 22% of patients were asymptomatic. The mean age at the diagnosis of IPMN was significantly different in symptomatic (59.4 ± 12.5 years) vs. asymptomatic patients (68.6 ± 8.8 years) ($P = 0.021$). The lesion(s) were localized in the head of the pancreas in 45% of patients, in the body-tail in 42%, whereas in 13% of cases the lesion involved all the Wirsung's duct. Radiologically, the IPMN was main-type in

39% of patients, branch-type in 44% and mixed in 17%. Single lesion was observed in the large part of patients (70%). Calcifications were founded in 18% of patients, more frequently in smokers (46%) than in non smokers (12%) ($P = 0.021$). The diameter of the lesion was in mean 2 ± 1.1 cm and 90% of patients showed a lesion less than 3 cm. Mural nodules suggestive for degeneration were observed in 18% of patients and correlated with histologic finding and with mortality. Surgical resection was performed in 26 patients. We observed mild-moderate dysplasia (MD) in 57% of patients, severe (SD) in 14% and AC in 24%. All patients with MD had normal CA 19-9, whereas 33% of pts with SD and 40% with AC had pathological serum levels of CA 19-9 ($P = 0.069$). 8 patients died during the follow-up, 3 of whom did not undergo surgery for local invasion of IPMN. 4 of the remaining 5 patients died within 4 years from the surgical resection. Serum levels of CA 19-9 were significantly higher in patients who died (106 ± 99 U/mL) vs. who did not (21 ± 41 U/mL) ($P < 0.0001$). **Conclusions** Clinical and epidemiological data from patients with IPMN differ from chronic pancreatitis. Serum levels of CA 19-9, radiological and histologic findings are prognostic factors for death.

Portal vs. Systemic Venous Drainage in Pancreas Transplantation Alone

Boggi U, Vistoli F, Del Chiaro M, Signori S, Croce C, Mosca I, Sgambelluri F, De Lio N, Amorose G, Marchetti P, Rizzo G, Mosca F

Division of General and Transplant Surger, Regional Referral Center for Pancreatic Diseases, University of Pisa. Pisa, Italy

Context Portal drainage (PD) of pancreas grafts has been associated with improved metabolic profile and fewer rejection episodes than systemic drainage (SD). These advantages, although not finally proven, would be especially useful in pancreas transplant alone (PTA) recipients. **Methods** Between December 2000 and May 2006 the venous effluent of 69 PTA was managed by PD (n=49) or SD (n=20). Exocrine secretions were drained in the small bowel in all but two recipient bladder drained. The two groups were well matched for all baseline characteristics and managed with equivalent immunosuppressive regimens. **Results** The rate of delayed endocrine pancreas function was 0 in the SD group vs. 2.0% in the PD group. Six grafts were lost in the early post-transplant course due to vascular thrombosis (2 SD vs. 1 PD) and humoral rejection (0 SD vs. 3 PD). One further graft was lost to arterial thrombosis 6 months after PTA. The initial hospital stay averaged 19 days in the SD group and 20 days in the PD group.

Relaparotomy rate (<3 months) was 25.0% in SD vs. 16.3% in PD. At the longest follow-up all but one recipient (PD, CMV infection) are alive and well. The overall incidence of infection was 10.0% in SD vs. 12.2% in PD. After a mean follow-up period of 12.0 months 5 acute rejection episodes (25.0%), all steroid resistant, occurred in SD and 2 grafts were lost due to chronic rejection. Equivalent figures for PD, after a mean follow-up period of 34.7 months, were 7 acute rejections (14.3%), 6 steroid resistant, and 5 grafts lost to chronic rejection. Glycemic control was excellent in both groups, but fasting serum insulin levels were significantly lower in PD. Patient survival at 1 and 2 years was 100% (SD) vs. 97.8% (PD) at either time points. Equivalent figures for insulin independence were 83.6% and 75.2% (SD) vs. 89.6% and 85.2% (PD). **Conclusions** Either routes of venous drainage are suitable for PTA, although more recipients experience rejection with SD (25.0%) as compared with PD (14.3%).

Surgical Complications in the Modern Era of Pancreas Transplantation

Boggi U, Vistoli F, Del Chiaro M, Signori S, Moretto C, Sgambelluri F, Perrone V, Mosca I, Peri A, Amorose G, Marchetti P, Rizzo G, Mosca F

Division of General and Transplant Surger, Regional Referral Center for Pancreatic Diseases, University of Pisa. Pisa, Italy

Context Surgical complications (SC) in pancreas transplantation (PT) are relevant because they frequently result in graft loss and increase recipient mortality. **Methods** Between May 1996 and May 2006, a total of 232 PT were performed, including 121 simultaneous pancreas kidney transplants (SPKTx), and 111 solitary PT (SPTx).

Antithrombotic and antimicrobial prophylaxes were always instituted and tailored on individual needs. Venous effluent was created in the portal vein in most instances (52 SPKTx vs. 76 SPTx); drainage of exocrine secretions was enteric in 181 patients (87 SPKTx vs. 106 SPTx) and urinary in 39 recipients (34 SPKTx vs. 5 SPTx). SC were

defined as the need for relaparotomy (R) during the first 3 months after PT or during the initial hospital stay, if it was longer than 3 months. **Results** SC occurred in 14.2% of recipients (11.6% SPKTx vs. 17.1% SPTx) after a mean post-transplant period of 10.1 days (10.9 days SPKTx vs. 9.7 days SPTx). Thrombosis (4.1% SPKTx vs. 5.4% SPTx) and hemorrhage (4.1% SPKTx vs. 6.3% SPTx) accounted for most R. Duodenal segment leaks occurred in 1.7% SPKTx recipients and in 0.9% SPTx recipients. R had no impact on recipient mortality but was associated with decreased kidney graft survival in SPKTx recipients (P=0.008) and

poorer insulin independence in SPTx recipients (P=0.005). One- and 5-year patient survival for recipients with or without SC were 90.9% vs. 95.3%, and 90.9% vs. 91.4%, respectively. Equivalent figures for kidney graft (SPKTx) was 61.5% vs. 95.3% (P=0.004), and 61.5% vs. 87.9% (P=0.004), respectively. Pancreas graft survival, at the same time points, was 51.5% vs. 93.1% (P=0.0001), and 39.2% vs. 81.4% (P=0.0001), respectively. **Conclusions** The impact of SC, consistently achieved below 15%, on graft survival remains high, but there seems to be less risk on recipient's life with prompt diagnosis and immediate R.

Apoptosis and Related Intracellular Pathways Strongly Supported Efficacy of Gemcitabine and Trichostatin A in Reducing Pancreatic Cancer Cell Growth

Bonora A¹, Donadelli M², Piacentini P², Cavallini A¹, Palmieri M², Pederzoli P¹
Biochemistry Unit, Departments of ¹Surgical Sciences and ²Neurological Sciences,
University of Verona. Verona, Italy

Context We recently reported a cooperative effect of combined treatment with gemcitabine (GEM) and trichostatin A (TSA) in inhibiting both *in vitro* and *in vivo* cell growth in pancreatic cancer. Being the resistance to GEM related to a defective expression of p53 gene in the apoptosis mechanisms, the association with histone deacetylase inhibitors, such TSA, enhances the degree of cell apoptosis and then the sensitivity to GEM. **Aim** We further evaluated intracellular associated mechanisms, like mitochondrial membrane potential ($\Delta\Psi_m$), reactive oxidative stress (ROS) and expression of pro-apoptotic genes, in order to assess whether these events support the efficacy of GEM-TSA combined treatment in enhancing apoptosis. **Methods** To analyze $\Delta\Psi_m$ a 2×10^5 suspension of T3M4 pancreatic cancer cell line was stained with 3,3-dihexyloxycarbocyanine, washed twice in PBS and then the uptake levels determined by flow cytometry. To assess the ROS degree, a similar cell suspension was

incubated with 2,7-dichlorofluorescein and analyzed by flow cytometry. The relative expression of pro-apoptotic genes was evaluated by RNA extraction, PCR amplification and gel analysis. **Results** TSA or GEM alone did not significantly reduce $\Delta\Psi_m$ as compared to control, whereas in association they led to a reduction of $\Delta\Psi_m$ in 60% of cells. ROS levels were roughly 2 fold increased by GEM but not further increased by combined treatment. However cell growth appeared to be reduced in 20% rate by TSA in presence of ROS induced by GEM. Proapoptotic isoforms of BIM gene were significantly upregulated, while antiapoptotic genes downregulated by TSA. Combined treatment significantly increased (with a 6-7 fold induction) mRNA expression of these genes. As regards molecular mechanisms generally associated with GEM resistance, the level of UMPH type II mRNA was significantly downregulated (with a 5 fold reduction), where the other mRNAs were not affected after 8 hours TSA treatment.

Conclusion Reduction of $\Delta\Psi_m$ suggested the involvement of mitochondrial pathways in the apoptosis induction. Relationship between free radicals and loss of $\Delta\Psi_m$ positively correlated ROS and sensitivity to GEM. Expression levels of proapoptotic *versus*

antiapoptotic genes are related with the cell response to GEM activity. These pathways appeared to underlie the apoptotic cell response to GEM and strongly support the combined efficacy of TSA and GEM in reducing pancreatic cancer cell growth.

Induction Irinotecan/Gemcitabine followed by Twice-Weekly Gemcitabine and Radiation in Locally Advanced Pancreatic Cancer

Boz G, De Paoli A, Innocente R, Rossi C, Tosolini GC, Pederzoli P, Talamini R, Trovò MG

Departments of Radiotherapy, Surgery, and Epidemiology, CRO. Aviano, Italy.

Department. of Surgery, General Hospital of Pordenone. Pordenone, Italy.

Endocrinology, University of Verona. Verona, Italy

Context Early clinical studies combining irinotecan (CPT-11) and gemcitabine (GEM) have yielded encouraging results. GEM administered via a twice-weekly schedule results in an enhanced radiation-sensitizing effect. **Aim** In an attempt to improve systemic control of disease and to impact on overall survival, investigators at several Centers are currently testing neoadjuvant chemotherapy strategies. This is a phase II study of induction CPT-11 and GEM followed by twice-weekly GEM and radiotherapy (RT). **Patients and Methods** 23 patients with cytological and/or histological evidence of unresectable pancreatic adenocarcinoma, entered the study. Median age was 58 years (39-69) and median Karnofsky score 90 (80-100). All patients received two cycles of induction CPT-11 (100 mg/m²) and GEM (1,000 mg/m²) on days 1 and 8 of each 3-week cycle. Three weeks later patients underwent RT at daily doses of 180 cGy, to a total dose of 54 Gy combined with bi-weekly GEM on Tuesday and Friday at a daily dose of 40 mg/m². Dose reduction or delay was

required with toxicity of grade II. **Results** All patients completed the neoadjuvant chemotherapy (CT)-RT treatment as scheduled whereas the scheduled concurrent RT-GEM treatment was completed by 2 patients only; the median number of GEM cycles was 8 (range: 3-12). Median follow-up time was 8 months and median survival time 14 months. Radiological confirmed response was: PR in 10 patients and NC in 10, 3 patients had progression of disease during treatment. 16 patients had a subjective PR. Hematological toxicity of grade III was observed in 1 patient and grade II in 11 patients. Gastrointestinal toxicity was grade III in 1 patient and grade II in 5 patients. **Conclusions** Induction CPT-11/GEM followed by twice weekly GEM and RT is feasible in patients with locally advanced pancreatic cancer, but with modest activity on local control and overall survival. Based on this experience, we would recommend to further explore induction CT by using other treatment schemes including novel agents.

Comparative Study between Balthazar Computed Tomography Severity Index and Morteale Modified Computed Tomography Severity Index for the Assessment of Acute Pancreatitis

Calculli L, Fisaletti M, Pezzilli R, Casadei R, Fantini L, Zanini N, Gavelli G

Department of Radiology, Department of Internal Medicine, and Department of Surgery,

Sant'Orsola-Malpighi Hospital, University of Bologna. Bologna, Italy

Context Balthazar criteria (CTSI) are largely used to assess the severity of acute

pancreatitis. However, it has been reported that the severity assessed clinically is better

that the use of radiological imaging assessment alone. Thus, it has been proposed a modified severity index for evaluating the acute pancreatitis [1]; this index (MCTSI) includes a simplified assessment of pancreatic inflammation and necrosis as well as an assessment of extrapancreatic complications. **Aim** This study was carried out to assess the correlation with patient clinical outcome and the two computed severity indexes. **Patients** Thirty-five consecutive patients (29 males and 6 females, mean age 57.0 years, range 18-88 years) diagnosed with acute pancreatitis during a 1-year period, underwent contrast-enhanced multidetector computed tomography within 1 week of the onset of symptoms. The pancreatitis was of biliary origin in 20 patients (57.1%), due to alcohol abuse in eight (22.9%), due to other causes in four (11.4%); the remaining three patients (8.6%) had no identifiable causes of the disease. According to the Atlanta criteria, 21 patients (60.0%) had a mild pancreatitis and 14 (40.0%) had a severe disease. Five of the

14 patients (35.7%) with severe disease were operated on for infected necrosis; three patients with severe disease (21.4%) died. **Methods** Statistical analysis was carried out using the Wilcoxon signed ranks test and the chi-squared test. **Results** According to the Atlanta criteria, mild acute pancreatitis had a CTSI of 1.8 ± 1.3 , and a MCTSI of 2.5 ± 0.9 , whereas the severe pancreatitis had a CTSI of 5.0 ± 2.9 and a MCTSI of 6.4 ± 2.1 . There was a high correlation ($P < 0.001$) between the individual values of the two imaging scores. However, MCTSI were able to detect better than CTSI the clinical severity of acute pancreatitis ($P = 0.04$). **Conclusions** The modified computed tomography severity index correlates more closely with patient outcome than the Balthazar computed tomography severity index.

1. Mortelet KJ, Wiesner W, Intriere L, Shankar S, Zou KH, Kalantari BN, et al. A modified CT severity index for evaluating acute pancreatitis: improved correlation with patient outcome. *AJR Am J Roentgenol* 2004; 183:1261-5. [PMID 15505289]

Are Well Differentiated Endocrine Tumours with Uncertain Behaviour Really Potentially Malignant?

Capitanio V¹, Zerbi A¹, Albarello L², Balzano G¹, Manzoni MF³, Capretti G¹, Di Carlo V¹
Pancreas Unit, Departments of ¹Surgery, ²Pathology, and ³Medicine,
San Raffaele Scientific Institute. Milan, Italy

Context Endocrine tumors classified as well differentiated with uncertain behaviour (WDET-U) represent a poorly characterized clinical-pathological entity; few information are available about their natural history. **Aim** To evaluate clinical behaviour and adequacy of surgical treatment in WDET-U. **Methods** 40 patients (25 female and 15 male; mean age 47.3 years) underwent pancreatic radical resection between 1987 and 2005 for unifocal, non-MEN associated WDET-U (according to WHO 2000 classification if present at least one of these four parameters: size > 2 cm, Ki-67 index $> 2\%$, angioinvasion, mitoses/10HPF > 2). An atypical pancreatic resection was performed in 47% of cases (enucleation in

30%, middle pancreatectomy in 12%, distal pancreatectomy with splenic preservation in 5%) whereas a typical resection in 53% (pancreatoduodenectomy in 28%, distal splenopancreatectomy in 25%). 40% were non-functioning tumors and 60% were functioning. Mean size was 3.8 cm (range 0.8-17.2 cm; > 2 cm in 67%). Ki-67 index was $< 2\%$ in 86% of cases, 2-5% in 11%, $> 5\%$ in 3%. Angioinvasion was present in 25% of cases. 13% of patients showed mitoses > 2 10HPF. In 33 cases only one of the 4 pathological parameters was present, in 6 cases two, in 1 case three. Mean follow-up was 87 months (range: 7-223 months). **Results** We observed distant relapse in 2

patients at 76 and 84 months, in the first case in the adrenal gland and in the second case in the liver. The first patient underwent a pancreatoduodenectomy; the pathological evaluation showed a size of 3.8 cm and angioinvasion was present; in the second patient a distal splenopancreatectomy was performed, tumor size was 4 cm, angioinvasion and 2 mitoses/10HPF were present. In both cases relapse was surgically removed; both patients are alive and disease-free at respectively 147 and 10 months after re-intervention. Recurrence was observed in 2/7 patients with more than one WHO

parameters and in 0/33 patients with only one parameter (P NS). Three patients died for reasons not related to the disease; all the other patients are alive and disease-free. **Conclusions** Endocrine tumors classified as WDET-U, though very low, have a malignant potential; the presence of >1 WHO parameter could represent a risk factor for this malignant potential. No local recurrence was found, therefore, atypical resection is indicated to treat WDET-U. A long-term follow-up (>5 years) is needed, because the onset of metastases occurred very late.

Aspirin and Risk of Pancreatic Cancer: A Systematic Review

Capurso G¹, Terrenato I², Moretti A¹, Koch M¹, Capurso L¹, Schunemann H², Delle Fave G¹

¹Digestive and Liver Disease Unit, II Medical School, University of Rome 'La Sapienza';

²National Cancer Institute Regina Elena. Rome, Italy

Context Pancreatic cancer is the fifth leading cause of cancer death in western countries, with some 40,000 deaths in Europe each year and a survival of less than 1% at 5 years after diagnosis. A better understanding of risk and protective factors for this neoplasm may inform decision about preventive efforts to reduce pancreatic cancer mortality. The expression of COX-2 seems upregulated in pancreatic cancer and in pre-invasive ductal lesions (PanIn) compared with normal pancreatic ducts. A number of studies on pancreatic cancer *in vitro* or animal models have demonstrated that inhibition of COX-2 activity is able to induce apoptosis, and to reduce cell proliferation and invasion. However, it is unclear from existing observational studies whether aspirin/NSAIDs use are protective against pancreatic cancer, and the evidence of the association of aspirin/NSAIDs with pancreatic cancer has not been systematically reviewed. **Aim** We conducted a systematic review to evaluate the relation between NSAIDs (including aspirin), and the risk of developing pancreatic cancer. **Methods** We searched PubMed, Embase, Scopus, the CDR and the reference list of identified papers and selected papers related

with our research question. I.e.: prospective (cohort: C) or retrospective (case-control: C-C) studies examining exposure to aspirin and/or NSAIDs and the incidence or mortality of pancreatic cancer. We defined 3 exposure categories (high, moderate and low), based on duration and dose of exposure. We calculated the pooled estimates (odds ratios, their 95% confidence interval (95% CI), and the associated P value) using the DerSimonian-Laird method, assuming a random effects model, and explored heterogeneity based on a priori hypotheses. **Results** We identified 7 studies fulfilling the inclusion criteria (4 C, 3 C-C). The studies enrolled 5,704 cancer patients between 1971 and 2000, and all but one were conducted in the US. We excluded one study from analysis as data regarding aspirin dose were absent. The pooled odds ratios in the 3 categories were 1.07 (95% CI: 0.70-1.62), 1.10 (95% CI: 0.87-1.39) and 0.92 (95% CI: 0.78-1.07) in the high, moderate and low exposure groups, respectively. There was an high unexplained heterogeneity in all analyses with I² ranging 63% to 79%. Restricting the analysis to aspirin use only, and analysing a priori hypotheses for heterogeneity, did not help explaining the

results. **Conclusions** Systematic review and meta-analysis did not help clarifying whether aspirin/NSAIDs consumption are a protective/risk factor for pancreatic cancer. The high heterogeneity and the high

exposition in controls may partially explain these results. There is need for better designed C-C or C studies, especially in Europe, to clarify this issue.

Evaluation of Elasto-Sonography for Pancreatic Masses Using Endoscopic Ultrasound

Carrara S, Arcidiacono PG, Mezzi G, Boemo C, Testoni PA

Division of Gastroenterology and Gastrointestinal Endoscopy, University Vita-Salute San Raffaele, Scientific Institute San Raffaele. Milan, Italy

Context EUS is an accurate technique for diagnosis of pancreatic masses, but it is sometimes difficult to distinguish between benign and malignant lesions. Some diseases, such as cancer, lead to a change of tissue hardness. Elastasonography (ES) is a reconstruction of tissue elasticity that provides additional information in the differential diagnosis. **Aim** To use ES to differentiate benign masses from cancer, adenocarcinoma (ADK) and neuroendocrine tumors (NET). **Methods** Between September 2005 and March 2006, 40 patients (23 M, 17 F), mean age 66 years, underwent EUS to study pancreatic masses. ES was performed with the SonoElastography module, integrated into the platform of the Hitachi EUB-8500 system. A linear array Pentax echoendoscope was used. All patients but one had EUS-FNA. We applied the Elastic Score to classify the patients: score 1, distortion for the entire low echo area (normal pancreas); score 2, non distortion on low echo area even for a part (fibrosis); score 3, distortion at the edge of low echo area (small ADK); score 4, no distortion for entire low echo area (NET); score 5, no distortion on low echo area and the surrounding (advanced ADK). The results were compared with the cytological analysis or surgical specimens. **Results** The results are summarized in the Table. The global

sensitivity and specificity of elastography for the differentiation between benign and malignant lesions were respectively 96.7% and 42.8% (low specificity, maybe because it is too operator-dependent; we need quantitative software to grade the pattern). The negative predictive value was 75%. **Conclusions** Although these are preliminary data, ES seems to add information in cases of non diagnostic biopsy and it can orientate the diagnosis and the follow-up.

Table. Correlation between Elastic Score and final diagnosis.

Elastic Score	No. of patients	Final diagnosis
1	1	Mild pancreatitis
2	4	2 pancreatitis 1 still waiting for final diagnosis 1 NET
3	15	3 pancreatitis 10 ADK 1 NET 1 IPMT
4	8	1 duodenal stromal tumor 1 chronic pancreatitis 5 NET 1 still waiting for final diagnosis
5	12	11 ADK 1 NET

Not All the Multifocal Cystic Lesions of the Pancreas Are IPMNs: Two Cases of Multifocal Serous Cystadenomas

Cavallini A, Salvia R, Germenia S, Serini P, Partelli P, Casarotto A, Pederzoli P

Department of General Surgery, 'GB Rossi' Hospital, University of Verona. Verona, Italy

Contexts Serous cystadenoma (SCA) is a well known benign neoplasm of the pancreas, usually unifocal; multifocal presentation is very rare with only 15 cases reported in literature. **Cases report** We present 2 cases of which 1 is a diffuse variant affecting the body, tail and a portion of the neck of the pancreas. This 53-year-old woman, previously underwent to distal pancreatectomy for a cystic lesion involving the body of the gland and classified as SCA. Three years thereafter, the same patient presented abdominal pain and an abdominal palpable mass at the physical examination; abdominal ultrasound (US) and computed tomography (CT) scans revealed a wide multiloculated cyst (7.5 cm in diameter) involving the pancreatic head; serous CA 19-9 was 185 U/mL. A pylorus preserving pancreaticoduodenectomy (PPPD) was performed and again a mucinocystic SCA was diagnosed. At the follow-up this patient lives without disease 9 years after the operation. The second case reported is a 32 years old woman with 3 cystic lesions involving respectively head (6 cm in diameter) body (1.9 cm) and tail (1.8 cm) of the pancreas, revealed by US with contrast and magnetic resonance imaging. No symptom was reported and serous tumor

markers were normal. In the suspicion of IPMN a PPPD was performed and a pancreogastroanastomosis was made in order to increase the possibility to follow by ERCP the pancreatic remnant. The post-operative course was uneventful and nine months after the operation clinical follow-up does not reveal any exocrine and endocrine pancreatic insufficiency. The final diagnosis was multifocal mucinocystic SCA. In this last case the research for von Hippel-Lindau (VHL) disease genetic mutations was negative. Interesting underline the medical history of this patient affected, during infancy, by acute myeloid leukaemia, underwent to total thyroidectomy 9 years before pancreatic surgery for papillary carcinoma and, finally, a parotidectomy was now performed for a parotid carcinoma. **Conclusion** The presence of pancreatic SCD with metachronous neoplasms is reported in literature. This feature should be kept in mind during the diagnosis and evaluation of patients with SCA. The histogenesis of SCA is not clear; multicentric tumors may be helpful in understanding histogenesis. We stressed the possibility of this rare presentation of SCA with the consequent differential diagnosis with IPMNs.

Monocyte Chemotactic Protein-1 Polymorphism Is Associated with Acute Recurrent Pancreatitis

Cavestro GM¹, Bertolini S¹, Okolicsanyi S¹, Sereni G¹, Frulloni L², Cavallaro L¹, Masselli E¹,
Protti A¹, Del Rio P⁴, Zanelli P³, Sianesi M⁴, Cavallini G², Franzè A⁵, Di Mario F¹

¹Department of Clinical Science, University of Parma. Parma, Italy. ²Surgery and Gastroenterology, University of Verona. Verona, Italy. ³Nephrology, Parma Hospital. Parma, Italy. ⁴Surgery, University of Parma. Parma, Italy. ⁵Gastroenterology, Parma Hospital. Parma, Italy

Context Pancreatitis is associated with an intense inflammatory response. Monocyte chemotactic protein-1 (MCP-1) is a

chemokine that plays a central role establishing and maintaining the inflammatory process. Polymorphism -2518

G of the regulatory region of monocyte MCP1 affects the level of expression of this chemokine increasing the inflammatory response. **Aim** To determine whether: 1) MCP1 2518 G allele is associated with the severity of acute pancreatitis (AP); 2) MCP1 2518 G polymorphism is associated to acute recurrent pancreatitis (ARP). **Methods** Determination of MCP1 2518 G polymorphism was achieved by PCR/RFLP in 101 patients affected from a single episode of biliary AP (59.4% male); 67 patients affected from ARP (61.2% male) and 73 healthy controls of the same ethnical group (56.3% male). The severity of AP and ARP was based upon the Atlanta criteria: 129 patients had mild pancreatitis (76.8%), 39 had severe pancreatitis (23.2%). **Results** MCP1 2518 G polymorphism is associated with ARP (Fisher's exact test, P=0.003, OR=2.74, 95% CI=1.42-5.30). The results are showed in the table. No association has been observed between MCP1 polymorphism and AP. No

association between MCP1 polymorphism and severity of AP was detected: 60 mild APs were A/G positive (50.4%); 5 mild APs were G/G positive (4.2%) and 54 mild APs were A/A positive (45.4%). 17 severe APs were A/G positive (45.9%); 2 severe APs were G/G positive (5.4%) and 18 severe APs did not present the G allele (48.6%). **Conclusions** MCP-1 polymorphism is associated with ARP. This polymorphism could increase the inflammatory response leading to a recurrence of the disease and possibly to chronic pancreatitis. In our series the MCP-1 2518 G allele is not associated with the severity of AP.

	MCP genotype A/A	MCP genotype A/G	MC genotype G/G
AP (n=101)	53 (52.5%)	46 (45.5%)	2 (2.0%)
ARP (n=67)	26 (38.8%)	35 (52.2%)	6 (9.0%)
Controls (n=73)	47 (64.4%)	21 (28.8%)	5 (6.8%)

CT Findings in Gene Mutation Associated Pancreatitis (GMAP) Compared to Obstructive Pancreatitis

Cicero C¹, Graziani R¹, Manfredi R¹, Motton M¹, Quattrocchi S¹, Frulloni L², Pozzi Mucelli R¹

Departments of ¹Radiology and ²Surgical and Gastroenterological Sciences, University of Verona. Verona, Italy

Context GMAP suspicious is clinical; certain diagnosis is confirmed by laboratory genetic tests. We assessed utility of CT findings in diagnosis of disease and follow-up of GMAP young patients with high risk of carcinoma. **Aim** To describe initial and follow-up CT imaging changes of pancreatic parenchyma and ducts in GMAP compared to obstructive pancreatitis (OP). **Methods** 22 patients with GMAP and 20 patients with OP were retrospectively included in this study. All patients underwent CT. Diagnosis of GMAP was confirmed by genetic test. Patients that previously underwent surgical procedures were excluded. Image analysis was independently performed by 2 radiologists.

Patients were subdivided in 2 groups according to time between symptoms onset and CT: Group A, less than 24 months; Group B, 25 months or more. Qualitative analysis: endoductal calculi structure and pancreatic parenchyma enhancement. Quantitative analysis: thickness of pancreatic parenchyma, diameter of main pancreatic duct (MPD), diameter of endoductal calculi. **Results** Group A: endoluminal calculi were present in 4/11 OP and in 1/9 GMAP; in both groups all calculi were calcified and homogeneous. Parenchyma enhancement was hypovascular in 6/9 GMAP and in 8/11 OP. Mean diameter of MPD was 5.4 mm in GMAP, 8.1 mm in OP. Thickness of parenchyma head, body,

and tail was 25.6, 16.9, and 15.7 mm, respectively in GMAP and 13.3, 12.7, and 8.6 mm, respectively in OP. Maximal diameter of endoductal calculi was 5 mm in GMAP, 13 mm in OP. Group B: endoluminal calculi were present in 8/9 OP and in 10/13 GMAP; 9/10 endoluminal calculi in GMAP (2/9 with central hypodense core 'bull's eye'), all calcified in OP. Pancreatic parenchyma enhancement was hypovascular in 10/13 GMAP and in 8/9 OP. Mean diameter of MPD was 11.7 mm in GMAP, 8.1 mm in OP.

Thickness parenchyma in head, body, and tail was 16.0, 14.8, and 12.6 mm, respectively in GMAP, 19.0, 14.8, and 11 mm, respectively in OP. Maximal diameter of calculi was 20.2 mm in GMAP and 18 mm in OP. **Conclusion** In early stage normal or enlarged parenchyma thickness, normal MPD, absence of endoluminal calculi are indicative of GMAP; in late stage "bull's eye" morphology and diameter of endoductal calculi suggest GMAP etiology. CT is useful for follow-up.

Pancreatic Carcinoma Cells Skew the Differentiation of Circulating CD34⁺ Progenitor Cells toward Endothelial Cells

David S, Colonna A, Carbone A, Scirelli T, Emanuelli G, Bellone G

Department of Clinical Physiopathology, University of Turin. Turin, Italy

Context New tumor blood vessels are formed by endothelial cells (EC) derived from pre-existing vessels in the tumor microenvironment. However, there is mounting evidence that bone marrow derived hemopoietic stem cells and endothelial progenitor cells mobilized by tumor and/or ischemia-induced signals may contribute to neovascularization. Pancreatic carcinoma is a biologically-aggressive malignancy that has a propensity to spread locally and metastasize distally. While not grossly vascular, this cancer exhibits foci of micro-angiogenesis and overexpresses the paramount pro-angiogenic factor VEGF, as well as additional mitogenic growth factors that are also angiogenic. **Aim** The study aimed to determine whether pancreatic carcinoma-derived soluble factors skew the differentiation of CD34⁺ cells from the myeloid lineage toward becoming EC. **Methods** The human pancreatic carcinoma cell line PT45, which produces high levels of VEGF (1,200 pg/mL), was used as model. Circulating CD34⁺ cells, isolated by an immunomagnetic method, were cultured in Iscove's medium containing SCF and GM-CSF or these two growth factors plus either VEGF or 30% of conditioned medium (CM)

of PT45 cells. After 28 day of culture, the expression of EC markers such as CD31, CD146, CD105, VE-cadherin and von Willebrand Factor (VWF) was analyzed by flow cytometry or immunohistochemistry. PT45 production of chemotactic activity for CD34⁺ was assessed using 96-well migration plate. In some studies, the tumor CM was first admixed with a neutralizing anti-VEGF antibody. **Results** PT45 cells released chemoattractant CD34⁺ cells, mainly through the tumor-derived VEGF. Moreover, cells developing from CD34⁺ cells cultured in the presence of SCF and GM-CSF plus either PT45 CM or VEGF were more spread out and in some areas were organized in long head-to-tail configurations, unlike control cultures. Flow cytometry analysis and immunohistochemistry demonstrated that the addition of PT45 CM to CD34⁺ cells, cultured under conditions that support myeloid cell development, induced skewing of the differentiation of a proportion (20-30%) of the CD34⁺ cells toward EC expressing CD31, CD146, CD105, VE-cadherin and VWF. **Conclusion** The results suggest that tumor-derived factors can mobilize circulating CD34⁺ cells in the tumor and skew the differentiation of these cells toward

endothelial cells, which may be incorporated in the vasculature. If vasculogenesis plays a significant role in tumor vascularization,

blocking this process may have an impact on the development of pancreatic cancer.

Distal Pancreatectomies: Laparoscopic Approach

Del Chiaro M, Croce C, Moretto C, Mosca I, De Lio N, Vistoli F, Signori S, Pietrabissa A, Boggi U, Mosca F

Division of General and Transplant Surgery, Regional Referral Center for Pancreatic Diseases, University of Pisa. Pisa, Italy

Context The minimally invasive laparoscopic approach to pancreatic resections has been increasingly employed in the recent years by pancreatic surgeons. In particular laparoscopic distal pancreatectomies (DP) are frequently performed for low grade malignancies of the pancreas. **Aim** To analyze the outcome of a series of laparoscopic distal pancreatectomies performed in a single institution. **Methods** From January 1999 to May 2006, at the Regional Referral Center for Pancreatic Diseases of the University of Pisa, laparoscopic distal pancreatectomy was attempted in 27 and performed in 24 (88.9%) patients. There were 19 (79.2%) females and 5 (20.8%) males; mean age was 51 years (range: 15-78 years). All patients were diagnosed with presumed neuroendocrine tumor (NET) or cystic neoplasm. The tumors were located in the body of the pancreas in 10 (41.7%) and in the tail in 14 (58.3%) cases. Eleven patients (45.8%) were asymptomatic, 2 (8.3%) had dyspepsia, 7 (29.2%) had pain, 4 (16.7%) had hypoglycemia. Fifteen patients (62.5%) received a DP with preservation of the spleen (with preservation of splenic vessels in 13 cases and of the gastric vessels in 2 cases) and 9 patients (37.5%) received a splenopancreatectomy. The pancreatic stump was managed by stapling transection in 18 cases (75%) and by harmonic shears transection with main duct ligation and mattress sutures in 6 cases (25%). **Results**

Mean operative time was 282 min. (range: 175-425 min); mean post-operative stay in this group of patients was 11 days (range: 4-29 days). There was no mortality. Seven patients (29.2%) developed post-operative complications. Six patients (25%) had pancreatic stump related complications including 2 fistulas (8.3%), 2 pseudocysts (8.3%) and 2 fluid collections (8.3%). Pancreatic stump related complications occurred in 6 patients (6/18; 33.3%) treated with stapler; no patients treated by main duct ligation and mattress suture (P=0.2) developed pancreatic stump related complications. Seven patients (29.2%) were definitely diagnosed with mucinous cystadenoma, 1 patient (4.2%) with pancreatic pseudocyst, 8 patients (33.3%) with serous cystadenoma, 8 patients (33.3%) with NET. Mean tumor size was 3.6 cm (range: 0.6-12 cm). Five-year actuarial survival rate in this group of patients treated with laparoscopic DP was 100%. **Conclusions** Laparoscopic DP is an useful technique for benign lesions or low grade malignancy. Post-operative morbidity rate is similar to open procedures; however pancreatic stump morbidity rate seems to be reduced by main duct ligation and mattress sutures as compared to stapling technique. Long term survival rate either for benign lesions or low grade malignancies seems to be the same of the open procedures.

Src Activity Regulates Adhesion, Spreading and Migration of Pancreatic Endocrine Tumour Cells

Di Florio A^{1,2,3}, Capurso G², Milione M², Panzuto F², Geremia R^{1,3}, Delle Fave G², Sette C^{1,3}

¹Department of Public Health and Cell Biology, University 'Tor Vergata'; ²Digestive and Liver Disease Unit, II Medical School, University 'La Sapienza'; ³Institute of Experimental Neuroscience, IRCCS 'Fondazione Santa Lucia'. Rome, Italy

Pancreatic endocrine tumours (PETs) are rare neoplasms, which are considered to be "indolent" but usually present with metastatic disease and exhibit poor response to standard medical treatments. There have been few attempts to investigate pathways responsible for PET cells growth and invasion, and to identify alternative therapeutic strategies. In a recent gene expression profile analysis of metastatic PETs we described the overexpression of src-like kinases, which may represent potentially promising candidates for therapy. We have therefore investigated the expression and function of this tyrosine kinases in PETs and PET cell lines. Western blot analysis indicated that src is the most abundant isoform expressed in the PET cell lines CM and QGP-1. Immunohistochemistry confirms expression of src in normal pancreatic islet cells and its overexpression and activation in PETs. The expression and activity of src in QGP-1 cells were comparable to those observed in the colon carcinoma cell line Colo205. Pharmacological inhibition by the src-kinase inhibitor PP2 strongly interfered

with adhesion, spreading and migration of both PET cell lines. Accordingly, the actin cytoskeleton was profoundly altered after inhibition of src whereas even prolonged incubation with PP2 exerted no effect on cell cycle progression and/or apoptosis of PET cells. A transient increase in tyrosine phosphorylation of a subset of proteins was observed in QGP-1 cells adhering to the plate, with a peak at 75 min after seeding, when approximately 80% of cells were attached. Inhibition of src caused a dramatic reduction in the phosphorylation of proteins with different molecular weight that were isolated from the cell extracts by anti-phosphotyrosine immunoprecipitation or pull-down with the SH2 domain of src. Moreover, we show that the docking protein p130Cas interacts with src and is a major substrates of the kinase in QGP-1 cells undergoing adhesion. Our results suggest that src plays a specific role during adhesion, spreading and migration of PET cells and may indicate therapeutic approaches directed to limiting the metastatic potential of these cells.

ERCP in Pancreatico-Duodenectomy Patients: A Single Tertiary Care Centre Experience

Familiari P, Mutignani M, Trincali A, Iacopini F, Spada C, Marchese M, Perri V, Costamagna G

Digestive Endoscopy Unit, Catholic University. Rome, Italy

Context Only scanty data on the feasibility and efficacy of ERCP in patients with prior pancreatico-duodenectomy (PD) are available. Identification and cannulation of hepatico- (H-J) or pancreatico-jejunosomy (P-J) is particularly challenging in patient with prior PD because of the length and sharp

angulations of the afferent limb. **Aim** To evaluate the feasibility, safety and efficacy of ERCP in patients with prior PD, from the experience of a single tertiary care centre. **Methods** Forty-three patients with prior PD (26 males, mean age 63±9.3 years, 22 Whipple resection, 21 pylorus-preserving

pancreatico-duodenectomy (PPPD)) who underwent attempted ERCP between 1988 and April 2006, were retrospectively identified from a prospectively collected database. **Results** A total of 65 procedures were performed. Indications for ERCP were: benign biliary strictures (n=10), malignant biliary strictures (n=8), biliary fistulas (n=8), bile duct stones (n=6), pancreatic duct dilation (n=6), pancreatic fistula (n=3), and recurrent cholangitis (n=2). The H-J or P-J were identified in 33/43 (76.7%) patients. Fifty-seven procedures were performed using a duodenoscope. In 4 cases, change to a frontal-viewing endoscope (FVE) was necessary to complete the procedure. In the remaining 8 procedures a FVE was used as first choice. Failure to reach the H-J or P-J occurred in 8 patients because of long and fixed limbs and to the presence of a jejunal stricture in 2 other cases, without any significant difference between Whipple or PPPD (18.2% vs. 28.6%). Overall ERCP success rate, defined as H-J or P-J identification, cannulation and

subsequent intervention was 72.1% (31/43 patients). In particular ERCP was successful in 67.6% and 88.8% of patients who underwent the procedure for a biliary or a pancreatic indication, respectively. ERCP was successful in 93.9% of patients in whom the H-J or the P-J were identified. Biliary stones extraction was performed in 9 patients; a biliary or pancreatic plastic stent was placed in 19 and 6 patients, respectively; pneumatic dilation of the H-J or P-J was done in 8 patients. Endoscopic procedure related morbidity was 1.5% with a patient who experienced respiratory failure. No procedure-related mortality occurred. **Conclusion** ERCP is feasible and safe in patients with prior PD, independently of the type of surgical intervention. Our study suggests that ERCP should always be first attempted in patients with a benign biliary or pancreatic complications. Due to the complex post-surgical anatomy, a high level of expertise is required and these patients should be managed only in referral centres.

The Search of the Stool and Blood *K-ras* Mutations In Patients With Pancreatic Mass. A Prospective Study

Fantini L, Barassi A, Melzi d'Eril GV, Tomassetti P, Pallotti F, Casadei R, Zanini N, Pezzilli R, Corinaldesi R

Department of Internal Medicine, Sant'Orsola-Malpighi Hospital. Bologna, Italy.

Department of Clinical Chemistry, University of Milan. Milan, Italy

Context It has been reported the usefulness of searching stool *K-ras* mutations in diagnosing malignant pancreatic mass. However, the data available are scarce and the papers published have not considered the entire spectrum of pancreatic disease forming mass. **Aim** We planned this prospective study in order to evaluate the presence of *K-ras* mutations in blood and feces for differentiating malignant from benign pancreatic masses. **Patients** Fifty consecutive patients (30 males, 20 females, mean age 67 years, range 34-91) with the abdominal mass of possible pancreatic origin admitted to the Department of Internal Medicine were enrolled in the present study.

The final diagnoses were as follow: pancreatic adenocarcinoma in 19 patients, malignant cystic tumor of the pancreas in three, pancreatic endocrine tumors in three, chronic pancreatitis in 13, complicated acute pancreatitis in six, benign congenital pancreatic mass in two and non pancreatic masses in the remaining four. **Methods** To all patients enrolled, after they have given their informed consent, a blood and stool specimens were obtained in the same day. After DNA isolation, PCR amplification was performed following the method by Nishikawa *et al.* [1]. Briefly, the region encompassing codon 12 of *K-ras* was

amplified using a mismatch primer creating a BstNI site for wildtype molecules. An aliquot of PCR product was digested with BstNI and analyzed by polyacrilamide gel electrophoresis followed by silver staining. If there was no mutation of *K-ras* codon 12, the full 107-bp PCR product was cleaved into 77 and 30-bp fragments. **Results** *K-ras* mutations were detected in none of the blood and stool specimens of the patients studied. **Conclusion** Our data clearly show that, at least in our experimental condition, the search of *K-ras*

mutations on blood and on stool is not useful for differentiating benign and malignant pancreatic masses. Further studies on different biological substances should be evaluated in order to find a simple useful genetic marker of pancreatic malignancy.

1. Nishikawa T, Maemura K, Hirata I, Matsuse R, Morikawa H, Toshina K, et al. A simple method of detecting *K-ras* point mutations in stool samples for colorectal cancer screening using one-step polymerase chain reaction/restriction fragment length polymorphism analysis. Clin Chim Acta 2002; 318:107-12. [PMID 11880119]

Genes Involved in Gemcitabine Activity: Pancreas Cancer vs. Primary Cell Cultures

Funel N¹, Giovannetti E³, Campani D¹, Pollina LE¹, Di Cristofano C¹, Mey V³, Menicagli M¹, Nannizzi S³, Morelli M¹, De Nisi MC¹, Danesi R³, Del Chiaro M², Boggi U², Del Tacca M³, Mosca F², Cavazzana A¹, Bevilacqua G¹

¹Division of Surgical, Molecular and Ultrastructural Pathology and ²Division of General Surgery and Transplantation, Department of Oncology, Transplants and Advanced Technologies in Medicine; ³Division of Pharmacology and Chemotherapy, Department of Internal Medicine; University Hospital of Pisa. Pisa, Italy

Context Recent data indicate that modulation of cellular enzymes of gemcitabine metabolism may influence drug activity, suggesting the need for a tailored treatment guided by gene expression analysis. **Aim** RNA expression of key genes involved in pharmacological treatment of pancreas cancer evaluated in tumor tissues and primary cell cultures. **Methods** From a series of 81 frozen pancreas cancer samples, 57 were submitted to laser microdissection (Leica ASLMD) and RNA extraction and 67 were available to set up primary cell cultures which were grown in RPMI 1640 (supplemented with 10% FCS, 1% L-Glu and 1% streptomycin) at 37°C, in 5% CO₂. Seven primary cell culture were obtained: PP78, PP109, PP117, PP147, PP161, PP103 and PP111. The 57 microdissected tumors and the 4 out of 7 primary cell cultures were evaluated by quantitative PCR analysis on the basis of

dCK, 5'-NT, CDA, hENT1 and RR1 gene sequence obtained from the GeneBank. **Results** The mRNA levels of the genes under study, analysed by Student t-test, were not significantly different comparing the 57 microdissected tumors with the 4 primary cell cultures (P=0.918), or matching the 4 microdissected tumors vs. their cognate cell cultures (P=0.619) or vs. all 57 tumors (P=0.728). **Conclusions** Similar results in the RNA expression were obtained from laser microdissected tissues and primary cell cultures, although in both techniques are selected only small quantities of cancerous cells picked up from different area of the tumor. Indeed, primary cell cultures, despite their realization is very low, may represent a valid tool to evaluate gene expression of critical determinants of anticancer drugs efficacy and predict different likelihood to respond to treatment.

Prevalence of Cystic Dystrophy of the Duodenal Wall in a Surgical Series of Chronic Pancreatitis

Gavazzi F¹, Zerbi A¹, Balzano G¹, Albarello L², Beneduce AA¹, Di Carlo V¹

Pancreas Unit, Departments of ¹Surgery, and ²Pathology, San Raffaele Scientific Institute, Milan, Italy

Context The cystic dystrophy of the duodenal wall has been recently reported as one of the etiologic obstructive factors of chronic pancreatitis (TIGAR-O classification system [1]). The rarity of this entity is thought to be related to a lack of awareness. **Aim** To assess the presence and the incidence of cystic dystrophy of the duodenal wall in a recent surgical series of patients with chronic pancreatitis. **Methods** We prospectively collected patients observed from October 2000 to November 2005 for chronic pancreatitis at our Surgical Department. There were 71 patients: 39 of them (55%) underwent surgery on the pancreatic gland. Eight patients were diagnosed at pathologic evaluation as affected by cystic dystrophy of the duodenum and represented the object of our study. **Results** They were 8 men, median age 48 years (range: 32-62 years). They represented 11% of all patients with chronic pancreatitis observed and 20.5% of operated patients. Six out of them were heavy drinkers and smokers. All of them presented with disabling pain and 2 of them with associated jaundice. The presence of cystic dystrophy of the duodenal wall was pre-operatively suspected in 6 out of 8 cases: endosonography

and CT scan revealed multiple cystic lesions in a thickened gut wall, with narrowing of the duodenal lumen. In one case both the imaging modalities suspected a pancreatic cancer. The last patient underwent surgery for symptomatic chronic pancreatitis without suspicion of cystic dystrophy. All eight patients underwent pancreaticoduodenectomy. Pathological examination showed the presence of cysts surrounded by inflammation and fibrosis in the duodenal wall, intermingled with pancreatic ducts and lobules and the presence of chronic pancreatitis in the proper pancreas. All the patients are asymptomatic and all well-being after a mean follow-up of 28 months (range: 9-48 months). **Conclusions** Cystic dystrophy of the duodenal wall represents a significant proportion of patients undergoing surgery for chronic pancreatitis. Pancreatoduodenectomy is the best option to cure this form, treating both duodenal and biliary obstacle and alleviating pain.

1. Whitcomb DC. Mechanisms of disease: advances in understanding the mechanisms leading to chronic pancreatitis. *Nat Clin Pract Gastroenterol Hepatol* 2004; 1:46-52. [PMID 16265044]

Multidetector Computed Tomography (MDCT) in the Evaluation of Vascular Involvement in Pancreatic Tumours: Accuracy of 2D vs. 3D Reconstructions to Assess Surgical Resectability

Gusmini S¹, Nicoletti R¹, Martinenghi C¹, Cappio S¹, Balzano G², Del Maschio A¹

Department of ¹Radiology and ²Surgery, Vita-Salute University, San Raffaele Hospital, Milan, Italy

Aim To evaluate the accuracy of MDCT to assess the vascular involvement in pancreatic tumours, comparing 2D and 3D reconstructions. **Materials and Methods** 58

patients, affected by pancreatic solid lesions underwent triple-phase 16 rows MDCT scan from January 2005 to January 2006. Two senior radiologists, experienced in pancreatic

pathology, analyzed 2D (multiplanar reconstructions, curved planar reconstructions) and 3D reconstructions (maximum intensity projection, volume rendering) of peripancreatic major vessels to assess surgical resectability, in double-blinded evaluation. The pattern used was: stage 0 (no touch between tumour and vessel); stage 1 (touch between tumour and vessel, bloodless surgical excision); stage 2 (vascular infiltration, bloody surgical excision or vascular resection, unresectable neoplasia). The infiltration of spleen vessels did not exclude surgical procedure. Resective (n=44) or palliative (n=14) surgical treatment was considered the gold standard. **Results** The accuracy of 2D and 3D reconstructions in the evaluation of vascular involvement was respectively of 93

and 88% (P NS). Underestimations of grade 2 (false negatives) were in 3 cases with 2D and in 6 cases with 3D reconstructions; overestimation of grade 1 (false positive) was in 1 case both with 2D and 3D reconstructions. Surgical pattern of grade 2 was expressed in 20/58 cases (34%); sensitivity of 2D and 3D reconstructions to assess vascular infiltration was respectively of 85 and 70% (P NS). High interobserver agreement was observed ($k > 0.75$). **Conclusions** MDCT showed an high accuracy in the evaluation of vascular involvement of pancreatic tumours; in particular 2D reconstructions, even if not significantly different, seem to be better than 3D, especially to assess peripancreatic major vessels infiltration.

Adjuvant Chemotherapy is Associated to Good Survival in Patients Underwent Extended Pancreaticoduodenectomy for Pancreatic Cancer

Iacono C¹, Cantore M³, Ruzzenente A¹, Verlato G², Facci E¹, Zugni C¹, Campagnaro T¹, Mambrini A³, Fontana M¹, Pachera S¹, Guglielmi A¹

Departments of ¹Surgery, and ²Medicine and Public Health, University of Verona. Verona, Italy.

³Department of Oncology, Massa Carrara Hospital. Massa, Carrara, Italy

Context Several types of adjuvant treatments have been proposed to improve survival in pancreatic cancer after surgery. **Aim** The present study aims at evaluating whether survival is increased in patients undergoing adjuvant chemotherapy (ADJCT) with respect to patients undergoing surgery alone. The rationale for this treatment is to combine local control of the disease, achieved by extended pancreaticoduodenectomy (EPD), with control of distant metastases, achieved by ADJCT. **Patients and methods** 84 patients underwent EPD from January 1994 to October 2005; 54 patients with ductal pancreatic carcinoma were included in this study. Twenty patients received ADJCT while 34 receive surgery alone. Fifteen of 20 patients received intra-arterial chemotherapy employing FLEC regimen (5-fluoruracil 750 mg/m², leucovorin 75 mg/m², epirubicin 45

mg/m², carboplatin 225 mg/m² administered every three weeks in to coeliac axis for three cycles), in 7 cases followed by systemic gemcitabine (at the dosage of 1 mg/m² on days 1, 8, 15 every 4 weeks for three months); five of 20 patients received others type of adjuvant treatments. **Results** The two groups were comparable for gender, age, grading, tumor size, stage, N status, and R0 or R1 resection. Median follow-up time was 16,5 months. The overall mean and median survival was 40.9 months and 18 months (range: 4-136 months), respectively, with actuarial 1-, 3- and 5-year survival rates of 70.4, 36.9 and 18.9%, respectively. ADJCT was well tolerated, with only one case of grade 3 nausea/vomiting, one patient had grade 3 anemia and leukopenia, and two patients had grade 3 thrombocytopenia. Significant difference in mean survival (47 vs.

30 months, $P<0.05$) and actuarial 5-year survival rates (52 vs. 10%, $P<0.05$) was seen in those who received ADJCT. ADJCT significantly influenced distant recurrence rate (45% vs. 85%, $P<0.05$) but it did not

reduced local recurrence rate (20% vs. 35%, $P=0.2$). **Conclusions** ADJCT is associated with long-term survival and decreased distant recurrence rates in patients with pancreatic cancers who have undergone EPD.

Endoscopic Treatment of Organized Pancreatic Necrosis (OPN) with Multiple Large-Bore Drainages

Iacopini F, Mutignani M, Familiari P, Tringali A, Spada C, Marchese M, Perri V, Costamagna G

Digestive Endoscopy Unit, Catholic University. Rome, Italy

Context Endoscopic treatment of OPN remains controversial since the necrotic material nearly always becomes infected after intervention or is not completely evacuated. **Aim** To examine the feasibility and clinical outcome of the endoscopic drainage of OPN by the insertion of multiple large (10 Fr) drainages that allow to flush and drain the collection. **Methods** 15 patients with OPN after acute necrotizing pancreatitis were endoscopically treated between 1990 and 2004 (5 cases between 2003 and 2004). Age was 56 ± 18 years, and 80% were males. Indications were: gastric-outlet syndrome in 7 patients, infected necrosis in 5 patients, and pain, cholestasis, and rapid increase in size in 1 patient, respectively. Collections had a median diameter of 10 cm (range: 6-15 cm), with a gastric or duodenal bulging in 10 and 5 cases, respectively. Collections were localized in the pancreatic head in 8 cases, body in 6 cases, and tail in one case. Naso-cystic drainage (NCD) with or without stents, both of 10 Fr, were placed in all cases to wash the cavity with a continuous infusion of saline solution. Success was defined as complete collection resolution. **Results** Transmural access to the collection was always performed with the Cremer diathermic cystotome and guide-wire passage. Drainage at the first procedure consisted in a single NCD in 10 patients and in two NCDs in 5 patients.

According to initial treatment, the time interval between the first and the second procedure was 5 and 10 days, respectively ($P=0.07$). Retreatment for ongoing/persistent infection was required by 5 (50%) patients treated with a single NCD, and by 1 (20%) patient treated with two NCDs. Moreover, endoscopic necrosectomy due to infection was necessary during the second procedure in 2 (20%) patients initially treated with a single NCD, and in one (20%) treated with two NCDs. Drainage after two procedures consisted in: two NCDs in 10 (66%) patients, and in the combination of one NCD plus two stents in 3 (20%) patients. A complete collection resolution was observed in 73% of patients, although surgery with arterial ligation was necessary in one patient for a massive intracystic hemorrhage from the necrotic tissue. Three patients died due to septic shock or acute renal failure. **Conclusions** Endoscopic transmural drainage may be a viable management option for patients with an organized and partially fluid pancreatic necrosis. Double large-bore naso-cystic drainages allow to maintain a high-flow continuous lavage that is essential to remove solid debris and to avoid infection. Placement of two NCDs from the first procedure seems to reduce the incidence of septic complications.

Autoimmune Pancreatitis as Prodromic Manifestation of POEMS Syndrome. Case Report

Lombardi G, Gallucci F, Menchise A, Suozzo R, Rabitti PG, Uomo G

Department of Internal Medicine and Department of Gastroenterology, Cardarelli Hospital.
Naples, Italy

Context Autoimmune disorders (such as thyroiditis, Sjogren syndrome, Crohn's disease, ulcerative colitis, connective tissue diseases) are often present in patients suffering from autoimmune pancreatitis, both at presentation or as anamnestic feature. Other patients develop autoimmune diseases during the follow-up. Association of autoimmune pancreatitis with POEMS syndrome has never been described in the literature. POEMS syndrome (also known as Crow-Fusake disease) is a rare disease characterized by polyneuropathy, organomegaly, endocrinopathy, M-protein, and skin changes; its pathogenesis is likely related to an autoimmune process as suggested by the relevance of neurologic and endocrinologic manifestations. **Case report** A 62-years-old female patient was admitted in November 2004 because of abdominal pain, fever, myalgias and CT scan feature of pancreatic mass. Diagnosis of autoimmune pancreatitis was made after an extensive work-up including also 3 fine needle aspiration biopsies. At that time, laboratory data showed alteration of aspecific serum tests of inflammation and an ANA titer of 1:80. Steroid treatment was started with good clinical and instrumental response. After 3 months the patient withdrew the steroid because of appearance of mild diabetes and then she deserted the follow-up program. In

December 2005 the patient was re-admitted in our Unit because of bilateral spontaneous leg pain accompanied by severe functional impairment, distal paresthesia, fever, continuous upper quadrant abdominal pain, papular lesions at the abdomen, trunk and legs, severe depression. Clinical, laboratory and instrumental features are consistent with distal axonal degenerative neuropathy (mixed type with prevalent damage of sensitive fibers), M-monoclonal component (IgGk-type) in the serum, multi-nodular thyroid struma with hormonal hypofunction, soft enlargement of the liver and spleen, and microcytic hyposideremic anemia. All these features together with the contemporary skin changes completed the diagnosis of POEMS syndrome. Pancreatic slight hyperenzymemia and dyshomogenous pancreatic head enlargement at magnetic resonance imaging were also present. Medical treatment was started with thyroid hormones and vitamin supplementation, and steroids (methylprednisone, 1 mg/kg BW, and then tapering schedules till 10 mg). Gradual improvement of neurological symptoms was achieved with normalization of serum pancreatic enzymes and disappearance of abdominal pain. Diabetes well controlled by oral agents also developed. At six-month follow-up no relevant symptoms are nowadays present.

PTPRG Expression Correlates with Tolerogenic Phenotype in Dendritic Cells Derived from Pancreatic Cancer Patients

Mafficini A¹, Bellone G¹, Bonora A², Crippa S², Vezzalini M¹, Della Peruta M¹, Scarpa A¹, Sorio C¹

¹Department of Clinical Physiopathology, University of Turin. Turin, Italy. ²Department of Surgical and Gastroenterological Sciences University of Verona. Verona, Italy

Context Dendritic cells, with their antigen presenting ability, are essential players at the

interface between the immune system and a developing cancer. Depending on their origin,

maturation state and stimulation by the surrounding milieu, different subpopulations of DC can either induce Th1 cells activation or immunosuppressive T cells development. It has been recently shown that monocyte-derived DC acquire a tolerogenic phenotype when cultured in conditioned medium from pancreatic cancer cells. Furthermore, iMo-DC generated from pancreatic carcinoma patients in advanced stages of the disease showed a similar pattern of features. **Aim** We investigated if the expression of PTPRG, a receptor-type phosphatase whose expression is modulated during mo-DC *in vitro* differentiation and activation, was affected in mo-DC from pancreatic cancer patients and if there is correlation between tolerogenic phenotype and PTPRG expression in these cells. **Methods** We measured by RT-QPCR the level of PTPRG mRNA expression in mo-DC from sex and age matched controls and subjects affected by advanced pancreatic cancer; in the same kind of cells, the ability to

induce proliferation and IFN- γ production in a mixed leukocyte reaction were measured. **Results** The level of PTPRG expression in mo-DC derived from pancreatic cancer patients showed a reduced capability to induce T cell proliferation. Immature mo-DC from control donors induced significantly higher IFN- γ production by T cells compared to immature mo-DC generated from patients (median 1,784 pg/mL, range 1,028-3,425 vs. median 1,045 pg/mL, range 521-1,507; P=0.006). This feature is associated to an increased expression of PTP γ in subject affected by pancreatic cancer (P=0.01). **Conclusion** We showed that in mo-DC derived from pancreatic cancer patients, the tolerogenic phenotype expressed by the cells strongly correlates with an up-modulation of PTPRG mRNA; this could imply a role for this receptor-type phosphatase in the modulation of DC behaviour and indicate a mechanism of immune suppression in patients with advanced pancreatic cancer.

Traditional Endoscopic EUS-Assisted vs. EUS only Drainage of Pancreatic Pseudocysts

Mangiavillano B, Arcidiacono PG, Carrara S, Mariani A, Masci E, Testoni PA

Division of Gastroenterology and Gastrointestinal Endoscopy, Vita-Salute San Raffaele University, San Raffaele Scientific Institute. Milan, Italy

Context A pancreatic pseudocyst (PP) is a cystic cavity within the pancreas surrounded by a granulation tissue wall. PP development is more commonly associated to acute or chronic pancreatitis. Therapeutic options are different but nowadays endoscopic treatment is considered the preferred technique. Echoendoscopy has recently been considered to overtake endoscopic part in PP treatment. **Aim** To assess the feasibility of endoscopic ultrasound (EUS) drainage of the PPs and to compare its feasibility, technical success and complications rates vs. EUS-assisted traditional endoscopic technique. **Methods** 14 patients (8 M; 6 F) undergone endoscopic PPs drainage with a median age of 55.7 \pm 21.5 years (range: 24-85 years) were retrospectively evaluated. Six patients were drained only by EUS; six patients with

traditional endoscopic EUS-assisted technique, and two underwent diagnostic EUS and thereafter drained by ERCP because Wirsung communication with the PP. **Results** The median PPs diameter was 8.8 \pm 3.6 cm (range: 1.8-5 cm). In all of the 6 EUS drained patients we had technical success. Five patients (83.3%) underwent plastic stent placement throughout the cysto-gastrostomy (CGS). Four (80%) were double pig-tail, and one plastic straight (20%). In the last patient, the PP was aspirated by needle. In the five patients with plastic stent the CGS was created by a cystotome (CT); only in one a bugia dilatator was also used. One patient (16.7%) had hemorrhage (the patient in which bugia was used). Four patients (80%) had a cyst regression at 3 months follow-up; one (20%) had a PP recidive at 2 months (patient

with straight stent). Of the 6 patients drained with traditional endoscopic EUS-assisted technique 4 (66.7%) had technical success while in 2 patients (33.3%) the previously positioned guide-wire under EUS guidance was displaced during the CT positioning with the duodenoscope. One patient (16.7%) had

hemorrhage. Of the 4 patients with technical success 3 (75%) had a cyst regression at 3 months follow-up. **Discussion** EUS PPs drainage is an efficacy and safety method if compared with traditional endoscopic EUS-assisted technique.

IL-6, a Creeping Foe: Further Insights into Its Autocrine Invasiveness Role in Pancreatic Cancer

Mao G¹, Marotta F², Liu T¹, Chui DH¹

¹Neuroscience Research Institute, Beijing University. Beijing PR China. ²Hepato-Gastroenterology Unit, S. Giuseppe Hospital. Milan, Italy

Context The lack of an appropriate targeted therapy against pancreatic cancer is also due to the poor knowledge of its mechanisms of invasiveness. **Aim** The purpose of this study was to gain further insights on the role of IL-6 as an autocrine invasive factor. **Methods** Invasion of PANC-1 in vitro was assessed by modified Albini's method. Graded concentrations of IL-6 were added to upper and lower culture compartments to check its invasiveness ability. Cells were then analysed by a repeat chemoinvasion assay in the presence of IL-6 to establish high-invasion (H cells) and low-invasion (L cells) clones. Flow cytometry analysis was performed to test the expression of IL-6 receptor on H-cells and L-cells together with a morphological and cell growth study (MTT assay). It was also examined the effect of anti-human IL-6 neutralizing antibody on H-cells. Possible interfering presence of bound IL-6 was minimized by a further immunoprecipitation

method. **Results** IL-6 addition determined a significant dose-dependent migration effect of cancer cells ($P < 0.005$) but only in the lower culture compartment. The expression of IL-6 receptor in H-cells was over two-fold the one of L-cells ($P < 0.01$) and they appeared spindle-shaped with multiple pseudopodia, unlike L-cells. The addition of H-cells derived medium (HDM) determined a 10- to 30-time increase of invading cells, either H- or L-cells, ($P < 0.001$) while the use of LDM caused a 3- to 6-time increase ($P < 0.05$). The treatment of HDM with anti-IL-6 antibody determined a 6-times decrease of IL-6 concentration ($P < 0.001$) and a 40% decrease of invading ability of H-cells. **Conclusion** In agreement with what recently suspected on the clinical ground, this study suggests that overexpression of IL-6 and its receptor seems to be highly linked to the invasiveness of PANC-1 prompting further interventional studies.

Common Polymorphisms in Th1 and Th2 Cytokine Genes and Susceptibility to Pancreatic Adenocarcinoma

Marasà L¹, Giacalone A^{1,2}, Crivello A², Marasà S¹, Forte GI², Giannitrapani L³, Lio D², Montalto G³

¹Pathology Unit, Ascoli Hospital; ²Clinical Pathology, 'Gruppo di Studio sull'Immunosenescenza', Department of Biopathology and Biomedical Methodologies, University of Palermo; ³Chair of Internal Medicine, University of Palermo. Palermo, Italy

Context Several studies implicate the inflammation as a significant risk factor in cancer development; in fact, it is evident an

increased incidence of pancreatic cancer in patients with chronic pancreatitis, when compared to the average population. Besides,

as recently demonstrated, microenvironment surrounding tumour highly resembles an inflammation site, with interaction among inflammatory cells and neoplastic cells that might facilitate tumour progression. Cytokines, chemokines, leukocytes, lymphocytes and macrophages, might contribute to neovascularisation, increasing of blood flow, vessel permeabilization immunosuppression and tumour metastasis. It is known that Th1/Th2 cytokine unbalanced production might be predisposing to different pathologies, cancer included. A prolonged inflammatory response (i.e. increase Th1 response) might allow that cells accumulating enough 'genetic hits' are promoted to neoplastic transformation. Studies have demonstrated that common polymorphisms in Th1 and Th2 cytokine genes can alter gene expression, modulate the balance between Th1/Th2 responsiveness, and, in some instances, influence susceptibility to cancer. **Aim** The aim of this study was to evaluate if an altered balance between Th1/Th2

responsiveness featured by polymorphisms in Th1 and Th2 cytokine genes, could be linked to pancreatic adenocarcinoma. **Methods** In this view, amplification refractory mutational system (ARMS-PCR) and restriction fragment length polymorphism (RFLP-PCR)-polymerase chain reaction methods were used to type TNF-alpha, IFN-gamma, IL12, IL18, TGF-beta1, IL10, IL4r and IL13 functional polymorphisms and score system based proinflammatory or anti-inflammatory profile constructed, comparing a small group of patients with sex and age matched healthy subjects. **Results** Here is reported the preliminary evaluation of the influence of combined of TH2-type (interleukin-10, IL4-receptor) and TH1 type cytokines (tumour necrosis factor a interferon g) genetic profiles on the susceptibility to pancreatic adenocarcinoma. Preliminary data seem to suggest that a prevalent proinflammatory profile might be predisposing to pancreatic adenocarcinoma.

Chronic Hyperamylasemia Unrelated to Pancreatic Diseases: Survey and Follow-up of 37 Patients

Menchise A, Gallucci F, Russo R, Balzano A, Rabitti PG, Uomo G

Department of Internal Medicine and Department of Gastroenterology, Cardarelli Hospital.
Naples, Italy

Context Almost all patients presenting hyperamylasemia undergo an expensive, long, difficult and often repeated diagnostic workup even this occurrence is not associated with symptoms or with known pancreatotoxic factors. **Aim** This study was addressed to assess the clinical characteristics of patients presenting with chronic hyperamylasemia unrelated to pancreatic diseases (CHUPD). **Patients** Data of all patients presenting with CHUPD admitted in our institution (in- and out-patients setting) starting from June 1997 to December 2006 were retrospectively reviewed. Thirty-seven patients were included into the study; median follow-up was 31 months (range 6-82 months; interquartile

interval 21-53 months). CHUPD was secondary to: macroamylasemia in 14 patients (37.8%; male 8, female 6; mean age 46.9±17.5 years), chronic benign pancreatic hyperamylasemia in 15 patients (40.5%; male 10, female 5; mean age 41.3±13.1 years), and salivary hyperamylasemia in 8 patients (21.6%; male 4, female 4; mean age 54.8±17 years). Gilbert's syndrome was present in 11 patients (7 with macroamylasemia) and hyperdyslipidemia in 7 patients (5 with chronic benign pancreatic hyperamylasemia). Diagnostic exams (all in the normal range) performed before our observation were: CA 19-9 serum level in 34/37 (91.8%); abdominal ultrasound in all patients (mean of 3 exams);

CT-scan in all patients (repeated in 25/37, 67.5%); ERCP in 19/37 (51.3%); abdominal MR in 11/35 (31.4%). Previous diagnosis in these asymptomatic patients were: chronic pancreatitis in 25 cases (67.5%); recurrent acute pancreatitis in 6 (16.2%); chronic recurrent pancreatitis in 3 (8.1%); 3 patients presented without a specific diagnosis.

Conclusions In clinical practice, the occurrence of an accidental unexplained hyperamylasemia very often allows to an unappropriate diagnostic workup due to the poor familiarity with CHUPD conditions which do not require any specific diagnostic test or treatment.

Pemetrexed and Irinotecan Combination as Second Line Salvage Chemotherapy for Advanced Pancreatic Cancer: An *In Vitro* Evaluation

Mercalli A¹, Sordi V¹, Di Carlo V², Reni M³, Piemonti L¹

¹JDRF Telethon Center for Beta Cell Replacement, ²Department of Surgery, ³Department of Oncology, San Raffaele Scientific Institute. Milan, Italy

Context Gemcitabine (GEM)-based chemotherapy is regarded as the standard treatment of pancreatic adenocarcinoma, but yields a very limited disease control. Very few studies have investigated salvage chemotherapy after failure of GEM or GEM-containing chemotherapy and preclinical studies attempting to widen the therapeutic armamentarium, not including GEM, are warranted. **Aim** To identify *in vitro* new drug combinations to be used as salvage chemotherapy in pancreatic cancer patients. **Methods and results** MIA PaCa2, CFPAC-1 and Capan-1 pancreatic cancer cell lines were treated with gemcitabine (GEM), fluorouracil (5-FU), docetaxel (DCT), oxaliplatin (OXP), irinotecan (CPT-11), pemetrexed (PMX) and raltitrexed (RTX) as single agent. PMX, inducing apoptosis with IC₅₀s under the C_{max} in the three lines tested and appeared the most effective drug as single agent. Based on these results, schedule- and concentration-dependent drug interactions (assessed using the combination index) of PMX/GEM,

PMX/DCT and PMX-CPT-11 were evaluated. The combinatory study clearly indicated the PMX and CPT-11 combination as the most active against pancreatic cancer. To confirm the efficacy of PMX-CPT-11 combination we extended the study to a panel of ten pancreatic cancer cell lines using clinically relevant concentrations (PMX 10 μM; CPT-11 1 μM). In eight of ten lines the PMX-CPT-11 treatment significantly reduced cell recovery and increased both the subG1 and caspase 3/7 fraction. After a 5-day wash-out period, an increased fraction of subG1 and caspase3/7 persisted in PMX-CPT-11 pretreated cell lines and a significant reduction in the clonogenicity capacity of the lines was evident. **Conclusion** The PMX and CPT-11 combination displays a strong schedule-independent synergistic cytotoxic activity *in vitro* against pancreatic cancer, providing experimental basis for its clinical testing as salvage chemotherapy in pancreatic cancer patients.

Correlation between Amylase Value in the Drains Fluid and Postoperative Pancreatic Fistula. Results of a Prospective Study on 137 Resected Patients

Molinari E, Bassi C, Crippa S, Mascetta G, Barugola G, Muselli P, Pederzoli P
Department of Surgery, University of Verona. Verona, Italy

Context There are many definitions of pancreatic fistulas in literature and the range of incidence reported is wide: from 2 to 30%. The significance of the amylase value in the drains and its correlation with the development of pancreatic fistula is still unclear. **Aim** The purpose of this study was to identify the value of amylases in the drains and in which post-operative day (POD) it is possible to predict the development of pancreatic fistula. **Patients and methods** In our Department a prospective study was done from April 2005 to February 2006 considering 137 patients who underwent a pancreatic resection (101 PPPD and 36 distal resection). In all patients the amylases value by drains was measured, together with the characteristics of fluid, the out-put, the amylases serum from POD#1 to POD#5 then in POD#7 and, if the drainages were not removed, in POD#9. The upper limit of normal serum amylase value in our hospital is 100 U/L. According to the international study group, pancreatic fistula was defined by clinical leak (Grade A, Grade B, Grade C) and when possible confirmed by fistulography. **Results** The most frequent

abdominal complication was pancreatic leak with a rate of 19.7% (27 cases), respectively in 15 patients (14.8%) after PPPD (10 cases with pancreaticojejunostomy and 5 with pancreaticogastrostomy) and 12 cases (33.3%) after a distal resection. Only one patient underwent a re-operation because of the pancreatic leak, the outcome was complicated by abdominal abscess and sepsis. All pancreatic fistulas occurred in a 'soft' pancreatic remnant. Patients with an higher level of amylases in POD#1 (mean of 19,800 U/L) developed a pancreatic fistulas while patients without a fistulas showed a mean level of amylase of 3,043 U/L ($P < 0.05$). We found only two pancreatic fistulas when amylases value in POD#1 was $< 5,000$ U/L (70^o percentiles) in both cases we performed a pancreaticogastrostomy. **Conclusions** Amylases value by drains in POD#1 seems to be a significant predictive factor of development of pancreatic fistulas after resection. No fistulas occur when the amylase value was $< 5,000$ U/L after PPPD with pancreaticojejunostomy or after distal resection.

Pancreatic Graft Sparing Total Duodenectomy

Mosca I, Perrone V, Del Chiaro M, Vistoli F, Signori S, Boggi U, Mosca F
Regional Referral Center for Pancreatic Disease Treatment, University of Pisa. Pisa, Italy

Context Enteric bleeding represents a significant complication after pancreas transplant, resulting in about 7% of cases. **Case report** A 32-year-old Caucasian woman with IDDM from the age of 14 underwent SPK in June 2003. In May 2005 she developed gastrointestinal bleeding and anemia, the grafts function remaining excellent. No apparent source of

gastrointestinal bleeding was identified by means of endoscopy and abdominal US was negative. Scintigraphic imaging following injection of 99mTc labelled red blood cells showed blood outflow at the donor's duodenum. Antiaggregation was then interrupted. Nevertheless the patient developed recurrent melanic stool. Therefore, a venting jejunostomy was performed on the

anastomotic loop for surveillance. The endoscopist was then able to detect multiple ulcerations of the donor's duodenum, apparently similar to those usually seen in IBD. However, bioptic samples of the ulcers did not show evidence of IBD or CMV inclusions and the patient never developed serological positivity for CMV. The patient was then treated conservatively. At discharge the patient was well, the serum levels of Hb stable, no evidence of recent bleeding or infection. In March 2006 the patient was again hospitalized for gastrointestinal bleeding from the jejunostomy. The endoscopic evaluation revealed a linear 0.4-inch long ulcer at about 4 inches from the jejunostomy, with evidence of recent bleeding. Pathological studies of the biopsies taken showed chronic inflammatory cells as well as lymphatic hyperplasia and Brunner's

gland hyperplasia. The patient underwent recurrent episodes of gastrointestinal bleeding which ultimately could not be treated endoscopically. We then performed relaparotomy with pancreatic graft sparing duodenectomy. The patient had main pancreatic duct and Santorini's duct anastomosed to the jejunum and closure of the jejunostomy. The pathological specimen was again negative for CMV inclusions but, by means of real time PCR, it was possible to retrace EBV genoma within the ulcer's bed. The patient was discharged in the 17th post-operative day. No evidence of gastrointestinal bleeding ever since, nor of infectious enteritis of the recipient's small intestine. **Conclusion** Recurrent donor's duodenum bleeding in SPK may effectively be treated by means of graft sparing duodenectomy, whenever conservative therapy fails to succeed.

Multifocal Intraductal Mucin-Producing Tumors of the Side Branches: MR Features and Evolution in Time

Motton M¹, Manfredi R¹, Graziani R¹, Tognolini A¹, Mehrabi S¹, Salvia R², Pederzoli P², Pozzi Mucelli R¹

¹Department of Radiology and ²Department of Surgical and Gastroenterological Sciences, University of Verona. Verona, Italy

Context Focal intraductal mucin-producing tumors (IPMT) of side branches (SB) are pancreatic neoplasms frequently non malignant; some authors suggest MR follow-up but others surgery resection. Multifocal IPMT-SB are 'poorly known' neoplasms probably non malignant: have we to choose between imaging follow-up (F/W) or surgery with total pancreatectomy? **Aim** To describe MRI/MRCP features of multifocal IPMT-SB, at diagnosis and their changes during follow-up. **Methods** 25 patients with multifocal IPMT-SB and at least 1 follow-up examination were retrospectively enrolled in the study. Diagnosis of multifocal IPMT-SB was confirmed by imaging findings including ERCP, EUS, CT and clinical course. Exclusion criteria: cystic lesions non communicating with main pancreatic duct

(MPD), IPMT of MPD and surgery. All patients underwent Gd-enhanced MRI/MRCP at diagnosis and follow-up, with a median follow-up time of 27.13 months. Qualitative analysis: mean number of dilated SB; presence/absence of communication with MPD; dependant endoductal filling defects; parietal nodules; ductal wall enhancement (nodular/diffuse); MPD endoductal filling defects; ascites. Quantitative analysis: maximal diameter of SB; length of the communicating duct; number of SB endoductal filling defects, maximal diameter of MPD (head/body-tail). **Results** At diagnosis: mean number of dilated SB was 7.4; communicating duct with MPD was visualized in 14/25; dependant endoductal filling defects were observed in 3/25; parietal nodules in 5/25; nodular ductal wall

enhancement in 6/25; MPD endoductal filling defects, ascites in 0/25. Quantitative analysis: mean maximal diameter of SB was 17.1 mm; mean length of CD was 6.4 mm; mean number of SB endoductal filling defects was 1.7; maximal diameter of MPD in head was 3.1 mm, in body-tail was 2.3 mm. At follow-up: mean number of dilated SB was 8.4; dependant endoductal filling defects were

observed in 3 patients; parietal nodules in 18 patients; nodular ductal wall enhancement in 8 patients; ascites in one patients. Mean maximal diameter of SB was 20 mm; maximal diameter of the MPD in head was 3.3 mm, in body-tail 2.6 mm. **Conclusion** MRI/MRCP is useful in diagnosis and in management of multifocal IPMT-SB.

The Plasma Renin-Angiotensin System in Human Acute Pancreatitis

Pezzilli R, Barakat B, Fantini L, Timpano A, Morselli Labate AM, Corinaldesi R

Department of Internal Medicine and Gastroenterology and Department of Emergency,
Sant'Orsola-Malpighi Hospital, University of Bologna. Bologna, Italy

Context Activation of the local pancreatic renin-angiotensin system (RAS) has been reported in experimental acute pancreatitis. At present, no data are available in humans. **Aim** To evaluate the plasma RAS in human acute pancreatitis. **Patients** Twenty-one patients with acute pancreatitis (13 males, 8 females, mean age 57.9 years, range 20-84 years) were studied within 24 hours of pain onset. None of the patients enrolled had arterial hypertension or other known diseases nor were they taking drugs capable of modifying the RAS. The pancreatitis was of biliary origin in 16 patients, due to alcohol abuse in three, due to pancreatic biopsy in one, and of unknown origin in the remaining one. According to the Atlanta criteria, 14 patients (66.7%) had mild acute pancreatitis and seven (33.3%) the severe form of the disease. **Methods** In all patients, plasma renin activity (reference range 0.2-2.8 ng/mL/h), plasma angiotensin I converting enzyme activity (reference range 65.8-114.4 U/L) and plasma aldosterone concentration (reference range 33-489 pg/mL) were determined immediately after hospital admission using commercial available kits. Serum amylase and lipase activities were also determined. Statistical analysis was carried

out using the Mann-Whitney and the Spearman rank correlation tests. **Results** Mean±SD plasma renin activity, angiotensin I converting enzyme activity, and aldosterone concentration were 0.73±0.84 ng/mL/h, 56.8±30.4 U/L, and 92.2±112.8 pg/mL, respectively. In particular, the plasma renin activity was above the reference range in one patient (4.8%); the plasma angiotensin I converting enzyme activity was above the reference range in one patient (4.8%) and below the reference range in 15 patients (71.4%); plasma aldosterone concentration was below the reference range in five patients (23.8%). No significant relationship was found between serum amylase or lipase activities and plasma renin activity, plasma angiotensin I converting enzyme activity or aldosterone concentration. Furthermore, no significant relationship was found between plasma renin activity, angiotensin I converting enzyme activity and aldosterone concentration and the severity of the disease. **Conclusions** The RAS may be impaired in patients with acute pancreatitis and it does not seem to be related to the severity of the disease.

The Sant'Orsola Algorithm for Pancreatic Cancer: An Interim Report

Pezzilli R, Casadei R, Calculli L, Santini D, Morselli Labate AM,
on behalf of NeoPan Study Group

Sant'Orsola-Malpighi Hospital, University of Bologna. Bologna, Italy

Context Pancreatic cancer still represents a diagnostic and therapeutic challenge and many efforts should be made in order to improve the survival of the affected patients. **Aim** To evaluate the clinical, diagnostic and therapeutic approach of consecutive patients with pancreatic neoplasms followed at our Institution. **Methods** A team involving medical and surgical specialists may represent a goal for the correct management of these patients; thus, in our University Hospital a specific team has been created and a diagnostic and therapeutic algorithm, based on the literature data, was released in April 2006 and was named NeoPan. This algorithm has been put into the Intranet pages of the website of our Hospital and a form has been prepared. All medical personnel, using the form, have communicated to one of us the data of the patients seen for suspected pancreatic cancer and the symptoms at presentation; the complete clinical data of the patients were then extracted from the electronically recorded charts. This is the annual interim report. **Results** One-hundred and forty-three patients were enrolled from March 2005 to May 2006. Eighty (55.9%) were hospitalized patients, 26 (18.2%) were from the day hospital, and 37 (25.9%) were outpatients. One or more reasons of admission of the patients were reported in 106 (74.1%) of the 143 forms sent. The reasons for admission were as follows: jaundice in 16 (15.1%) of the cases, jaundice and weight loss in seven (6.6%), jaundice, persistent abdominal pain and weight loss in ten (9.4%), abdominal pain and the finding of an abdominal mass diagnosed in other hospitals in 24 (22.6%), and a pancreatic mass diagnosed in other hospitals in 54 (50.9%). One reason was reported in 101 patients and two reasons in five of the patients. Complete

clinical and therapeutic data were available in 78 (54.5%) of the 143 enrolled patients. All 78 patients underwent imaging examination mainly consisting of a multidetector computed tomography scan; this examination was diagnostic in 70 cases (89.7%). A histological/cytological examination of the pancreatic mass was available in 54 (69.2%) of the 78 patients. The pancreatic neoplasms were confirmed in 45 (83.3%) of the 54 cases, not confirmed in eight (14.8%; chronic pancreatitis in two patients, carcinoma of the papilla in four, cancer of the biliary tree in one, and normal aspect of the pancreas in one), and the histological/cytological examination failed to produce a diagnosis in one case (1.9%). Serum CA 19-9 was determined in 72 cases (92.3%) and it was higher than the upper reference limit (37 U/ μ L) in 46 cases (63.9%). In the 50 patients with histological/cytological examination (47 with and three without neoplasia), the sensitivity of this marker was 57.4%, the specificity was 0%, the positive predictive value was 90.0% and the negative predictive value was 0%. On the basis of clinical and imaging data, 45 (57.7%) of the 78 patients were judged suitable for pancreatic resection and the resection was carried out in 34 (75.6%) of the 45 patients. The surgical morbidity occurred in five cases (11.1%) and the 30-day post-operative mortality was 2.2% (one case). Thirty-three of the 78 patients (42.3%) underwent adjuvant chemotherapy and eight of the 78 (10.3%) were judged suitable for neo-adjuvant chemotherapy which was carried out in seven of them. **Conclusions** A multidisciplinary approach optimizes the economic resources of our Hospital and increases the number of patients suitable for surgical resection of the pancreas.

Exhaled Breath Analysis in Chronic Pancreatitis

Pezzilli R, Morselli Labate AM, Fantini L, Casadei R, Zanini N, Calculli L, Corinaldesi R

Department of Internal Medicine and Gastroenterology, Sant'Orsola-Malpighi Hospital,
University of Bologna. Bologna, Italy

Context Human exhaled breath contains a wide range of molecules either present as gases or occurring in solubilized form in the humidity of the breath. **Aim** To evaluate whether breath analysis is able to differentiate chronic pancreatitis patients from healthy subjects. **Subjects** Thirty-one consecutive patients (25 males, 6 females; mean±SD age: 58±11 years, range: 37-78 years) with proven chronic pancreatitis were studied. The pancreatitis was of alcoholic origin in 22 patients, obstructive in 2 and of unknown origin in 7. The diagnosis of chronic pancreatitis was made according to the Rome-Marseilles criteria; it was based on clinical history and was confirmed by ultrasonography and/or contrast-enhanced computed tomography, magnetic resonance imaging and endoscopic retrograde cholangiopancreatography and/or histology. On the basis of fecal elastase-1 (ScheBo Tech, GmbH, Wettenberg, Germany; reference value: greater than 200 µg/g), 11 chronic pancreatitis patients had exocrine pancreatic insufficiency. No patients had pain at the time of the study. Thirty-one healthy subjects (9 males, 22 females; mean age 52±18 years, range: 25-78 years, P=0.251 vs. chronic pancreatitis patients) recruited from the medical staff were used as controls. **Methods.** After an overnight fasting, a breath sample from all subjects was obtained in the same controlled clean room according to the manufacturer instruction. The subjects exhaled into a vial that was crimped afterwards. An ambient air sample was also obtained immediately after each patient examination. The exhaled patient samples, as well as the ambient air samples, were

immediately stored at -20°C until analysis which was carried out using a mass spectrometer (Airsense, V&F Medical Development GmbH, Absam, Austria). Ninety-seven different substances were analyzed on the patients and ambient air samples. The data were expressed in ppb and were analyzed by means of the Mann-Whitney U-test. Two-tailed P values of less than 0.05 were considered statistically significant. **Results.** Considering the exhaled breath, 20 undefined substances with molecular masses 56, 84, 94, 95, 96, 97, 98, 99, 100, 101, 102, 104, 105, 106, 110, 112, 113, 114, 115, 116 were significantly lower in chronic pancreatitis patients than in the controls, whereas the substance with molecular mass 66 was significantly higher in chronic pancreatitis patients than in controls. Surprisingly, the ambient air collected was significantly different between chronic pancreatitis patients and controls as regards the same substances detected in the exhaled breath of the patients, except for substances with molecular mass 66 and 102. Finally, no significant differences were found in chronic pancreatitis patients between those with and those without pancreatic insufficiency. **Conclusions** The results of this study show that chronic pancreatitis patients exhaled some substances differently than healthy subjects. There is the need to identify these substances as well as to collect the exhaled breath in a closed circuit to prevent the possible biases due to ambient air. A provocative meal test coupled with this technique might be useful in order to evaluate exocrine pancreatic insufficiency in chronic pancreatitis patients.

Comparison between the Influence of the V39A Mutation and Ca²⁺ on Trypsinogen Cationic Protein (PRSS1) Activation Evaluated by Molecular Dynamic Simulation Technique

Pugliese L¹, Arduino C², Salacone P³, Salmin P², Gaia E³

¹S.A.F.AN. Bioinformatics. Turin, Italy. ²Medical Genetics, 'A.S.O. San Giovanni Battista'. Turin, Italy. ³Gastroenterology, 'A.S.O. San Luigi Gonzaga'. Orbassano (TO), Italy

Context and aim A number of experimental observations suggest that extra- as well as intra-cellular calcium concentrations play an important part in the initiation of pancreatic protease activation, but the intracellular signaling events that regulate this process are unknown. Mutations R122H and N29I in human trypsinogen-I have been recently associated with hereditary pancreatitis (HP). The R122H substitution is believed to cause pancreatitis by stabilizing trypsin against autolytic degradation, while the mechanism of action of N29I and other mutation has been unknown. In a recent study we have identified a novel PRSS1 mutation in seven subjects with chronic pancreatitis from three generations of an Italian family located in the exon 2. This mutation causes a valine to alanine substitution at codon 39 (V39A). **Methods** In the trypsin protein we have evaluated the effect of Ca²⁺ binding and of the presence of the V39A mutation on trypsinogen mobility. Molecular dynamic is a technique that allow to evaluate at atomic level the mobility of proteins. We applied

such a technique to evaluate the influence of Ca²⁺ binding and of the V39A mutation on the flexibility of trypsin. The human trypsin crystal structure at 2.2-Å resolution was the base for the construction of the protein models. We performed four molecular dynamics simulations in presence and absence of Ca²⁺ and of the V39A mutation and subsequently we applied the so-called essential dynamics analysis (ED) for extracting large concerted motions of backbone atoms from the MD trajectories. **Results** Our results indicate that Ca²⁺ binding and the presence of the mutation produce similar effects on the flexibility of the loop holding R122, where resides the first proteolytic site. **Conclusion** Since it has been experimentally proven that calcium binding induces and increased resistance to proteolysis of the loop holding R122, it may be argued that, even in absence of Ca²⁺, the V39A mutation influencing in a similar manner the flexibility of that loop, would induce an increased stability of the loop R122 and a greater resistance to proteolysis.

Pancreatic Intraductal Adenoma Pyloric Gland-Type with Intraductal Papillary Mucinous Neoplasm and Foci of Pancreatic Ductal Adenocarcinoma

Rizzo N¹, Arrigoni G¹, Albarello L¹, Zerbi A², Di Carlo V², Doglioni C¹

¹Department of Anatomy and Pathology, ²Pancreas Unit, Department of Surgery, Scientific Institute H. San Raffaele, HSR. Milan, Italy

Context Pancreatic intraductal tubular adenoma (ITA) of pyloric gland type is a rare benign tumor occurring mostly in the 5th-7th decade of life, affecting equally male and female patients. Only 12 cases have been described so far; 10 arose within the main

pancreatic duct, a single case was located at the junction of Santorini and Wirsung duct and another case in a branch of the dorsal pancreatic duct. This neoplasm is composed of packed tubular pyloric glands and morphologically resembles the pyloric gland

type adenoma of the gallbladder. All the reported cases were benign. **Case report** We report a case of an unusual ITA pyloric gland-type of the pancreas in a 72-year-old man; it was bifocal and it was located within a dorsal and ventral pancreatic branch ducts. The neoplasm was composed of two polypoid mass measuring 2.7 cm and 1 cm in diameter, located in the head and in the uncinate process respectively, protruding into the lumen of dilated pancreatic ducts. Microscopically the lesion in the uncinate duct was composed of packed tubular pyloric type glands only; the largest lesion in the

dorsal duct was composed by an ITA merging with an intraductal papillary mucinous tumor (IPMT) with varying degrees of dysplasia and with an associated invasive component showing tubular features, perineural and peripancreatic adipose tissue infiltration but no lymphnode metastasis. **Conclusion** This case indicates that: ITA may arise in the branch ducts; ITA can be associated with IPMT and invasive adenocarcinoma; extensive sampling of the surgical specimen is mandatory in every case of ITA in order to exclude a malignant component.

A Fast-Track Clinical Pathway Reduces Delayed Gastric Emptying after Pancreaticoduodenectomy

Rocchetti SI, Balzano G, Ortolano E, Beneduce AA, Zerbi A, Di Carlo V
Pancreatic Surgery, IRCCS San Raffaele Hospital. Milan, Italy

Context Delayed gastric emptying (DGE) is a well known postoperative complication of pancreaticoduodenectomy (PD), occurring in 4-57% of patients in different series and different centers. **Aim** To evaluate if a fast track clinical pathway including early removal of nasogastric tube was effective in decreasing the incidence of DGE in large series of patients undergoing PD. **Methods** Prospective evaluation of 128 patients undergoing PD from July 2004 to March 2006 (group A) treated with a fast track clinical protocol including postoperative peridural analgesia, early removal of nasogastric decompression (POD 1), early mobilization and early postoperative oral intake (liquid food from POD 3 and solid intake from POD 4 or 5 when tolerated) compared to a homogeneous group of 121 patients treated from January 2003 to June 2004, without fast track pathway (group B). Our usual definition of DGE is the need for a nasogastric tube or vomiting 10 days after operation. Statistical analysis was made with chi-square and Mann-Whitney tests. **Results** We observed 29 DGE in the group B (23.9%), 20 as single complication (16.5%) and 9 in association

with other intra abdominal complications (IAC) (7.4%), and 18 DGE in group A (14%), 7 alone (5.5%), and 11 with other IAC (8.5%), respectively. In both groups postoperative pancreatic fistula was the most frequent complication associated. The difference between the incidence of DGE non associated with other IAC in the two groups was statistically significant ($P < 0.01$). The median postoperative hospital stay was 15 days (mean 18.3 days; range 7-102 days) for group B and 13 days (mean 17 days; range 7-110 days) for group A ($P < 0.05$). The two groups have no significant difference in terms of mortality (3.3% group B and 3.9% group A), re-laparotomy (7.4% B and 10% A) and pancreatic fistula (25.6% B and 24.2% A, respectively) and there is a trend to significance in incidence of overall complications (63% group B and 54% group A). **Conclusions** Fast track clinical pathway is feasible also in patients undergoing major pancreatic surgery and is associated to a reduction in postoperative DGE and postoperative hospitalization. DGE without other IAC showed a marked decrease (5.5% vs. 16.5%), due to new postoperative

multimodal strategies avoiding the extensive use of nasogastric tube and promoting early

postoperative oral feeding.

Clinical Findings of Chronic Pancreatitis Associated with Gene Mutations

Scattolini C¹, Cavestro GM³, Graziani R², Manfredi R², Bernardoni L¹, Katsotourchi A¹, Pravadelli C¹, Ierace S¹, Frulloni L¹, Vantini I¹

¹Chair of Gastroenterology, ²Institute of Radiology, University of Verona. Verona, Italy.

³Chair of Gastroenterology, University of Parma. Parma, Italy

Context Mutations of CFTR gene, SPINK1 gene, and K8 gene have been associated with chronic pancreatitis (CP). The clinical outcome of CP associated with gene mutations (CPgm) seems to be different from CP secondary to other aetiologies (CPwt).

Aim The aim of this study was to compare clinical and radiological findings between CPGM and CP. **Material and methods** We collected clinical and radiological data from all CP patients referred to our Department between 2000 and 2005. All patients underwent genetic tests for 21 CFTR gene mutations, N34S mutation on the SPINK1 gene and G61C gene mutation on the K8 gene. We study 400 unrelated partners of cystic fibrosis patients as control group for CFTR gene mutations, and 200 blood donors as control subjects for K8 and SPINK1 gene mutations. **Results** We found 39 out of 143 (27.3%) patients with CPgm, of whom 23 (16.1%) with CFTR gene mutations, 11 (7.7%) with SPINK1 gene mutation and 7

(4.9%) with K8 gene mutation. The relative risk to develop CP was 5.29 (CI 2.64-10.6) for CFTR, 16.6 (CI 2.2-129.9) for SPINK1 and 10.24 (CI 1.25-84.2) for K8. The mean age at the onset of the disease was lower in CPgm (37.3±17.3 years) than in CPwt (44.4±12.3 years) (P=0.007). Female sex was significantly more frequent in CFTR patients (59%) than in SPINK1 (30%), K8 (17%) and CPwt (27%) (P=0.025). Heavy drinkers were more frequently found in CPwt (40%) than in CPgm (8%) (P<0.0001), as well as smokers (78% vs. 34%; P<0.0001). Pancreatic calcifications were less frequent in CFTR (50%) patients than in SPINK1 (90%) and K8 (83%) (P=0.053). Exocrine and endocrine pancreatic insufficiency appeared less frequently and later in patients with CFTR and SPINK1 than in K8 gene mutations and in CPwt. **Conclusions** Clinical and radiological findings and the evolution of the disease are different in CPgm vs. CPwt.

Stem Cell Features of Pancreatic Cancer Cell

Sordi V¹, Formicola R¹, Mercalli A¹, Melzi R¹, Balzano G², Zerbi A², Di Carlo V², Piemonti L¹

¹JDRF Telethon Center for Beta Cell Replacement, and ²Department of Surgery, S. Raffaele Scientific Institute. Milan, Italy

Context Several recent findings suggest that the capability to sustain tumor formation and growth exclusively resides in a small proportion of tumor cells, with stem cell properties. **Aim** The aim of the project is to understand whether pancreatic tumor cells

show features of stem cells. **Methods** Nineteen different ductal adenocarcinoma pancreatic cell lines were studied: Panc1, MIA PaCa2, PaCa44, PT45, PSN1, SK-PC1, PaCa3, Panc2, IMIM-PC1 from primary cancer; Capan1, Hs766T, CF PAC1; T3M4

from metastases; AsPc1, A818-4, HPAF from ascites; BI, PC, SW850 from unknown source. Primary culture of isolated human islets (as normal endocrine differentiated tissue) and normal human pancreatic duct epithelial cells (HPDE6-E6E7 cell line) were also tested as control. Stem surface marker expression was analyzed by flow cytometry, the potential to differentiate into adipocytes and osteoblasts was explored and gene expression of transcriptional factors of pancreas development (Pdx1, Ngn3, NeuroD, Pax6, Pax4, Nkx2.2, Nkx6.1, Isl1, Ptf1alpha, Hnf6, insulin, glucagon, synaptophysin, chromogranin B, GAD65, IA-2, Cytokeratin 19) was measured by quantitative real-time PCR. **Results** Pancreatic cancer cell lines present phenotype similar to that of mesenchymal stem cells; in fact they appear CD73⁺, CD105⁺, CD166⁺, CD49e⁺, CD117^{+/-}, Stro1^{+/-}, CD133^{+/-}, CD34⁻ and CD31⁻. In accordance with their phenotype, when cultured under appropriate conditions, tumor cell lines are able to differentiate into

osteoblasts and adipocytes. Pancreatic cell lines express genes of pancreas development normally silent in non neoplastic duct cell like Ngn3, NeuroD, Pax4, Ptf1a, GAD65. Pdx1, Isl-1 and Pax6 expression appear significantly higher in cancer cell than in non neoplastic duct cell, while Nkx2.2, Nkx6.1 and Hnf6 are down regulated. It is also evident that the expression is heterogeneous among cancer lines and dependent on the source: in particular metastatic cell lines express significantly higher level of CK19, Isl-1 and Nkx6.1 and lower level of Ptf1a than cell lines derived from primary tumor. The level of expression is lower than endocrine differentiated human pancreatic islet (at least three log less). **Conclusions** The analysis of transcriptional factors involved in pancreas development, the expression of stem cell markers and the capacity to differentiate in non epithelia tissues suggest that pancreatic cancer cells retain stem cell patterns of behaviour. (Supported by AIRC grant 2874 and MIUR grant 2005060022)

Role of PET/CT in the Management of Pancreatic Tumors

Sperti C¹, Pasquali C¹, Scappin S¹, Bissoli S², Chierichetti F², Liessi G³, Pedrazzoli S¹

¹4th Surgical Clinic, 'Istituto Oncologico Veneto', University of Padua. Padua, Italy. ²Nuclear Medicine and ³Radiology, Castelfranco Veneto Hospital. Castelfranco Veneto (TV), Italy

Context Positron emission tomography (PET) using fluorodeoxyglucose (FDG) has gained increasing importance in the diagnosis and staging of pancreatic cancer, but an exact anatomic delineation of PET findings is often difficult. The integrated PET/CT scanner provides a computed tomography (CT) and PET with subsequent image fusion in the same examination, improving the anatomic quality of PET findings. **Aim** The aim of the current study was to assess the influence of integrated PET/CT on the management of patients with suspected pancreatic tumors. **Methods** From January 2004 to March 2006, PET/CT examinations were performed in patients with suspected pancreatic tumors in addition to conventional work-up (serum CA 19-9 assay, abdominal US and/or CT, chest

X-ray). PET/CT examinations were conducted according to a standardized protocol following an injection of 350-450 MBq FDG. All PET/CT findings were confirmed by operative exploration, biopsy or follow-up. **Results** A total of 205 patients underwent PET/CT for diagnosis and staging of suspected pancreatic tumors (n=177) or during the follow-up after resection for pancreatic cancer (n=28). There were 91 males and 114 females (mean age of 61.3 years; range 37-82 years). 98 patients had a malignant tumor (97 adenocarcinomas and one lymphoma), while 79 patients had a benign disease (51 cystic tumor or intraductal mucinous tumors, 16 chronic pancreatitis, 12 other neoplasms). PET/CT correctly identified 96/98 malignant lesions (sensitivity and

positive predictive value of 98%): there were two false positive findings (chronic pancreatitis). In 15 patients PET/CT showed distant metastases not seen by conventional examination, and correctly identified as malignant 13 lesions with inconclusive findings on traditional imaging. Moreover, three patients had a simultaneous colon cancer at PET/CT examination. Of the 28 patients studied in the follow-up after resection of primary cancer, recurrent disease occurred in 17 of whom 11 were only

identified by PET/CT imaging. In one additional patient PET/CT correctly detected a second primary colon carcinoma. Finally, PET/CT findings changed the management in 43 patients (21%). **Conclusion** PET/CT altered the management of patients with suspected primary or recurrent pancreatic cancer in one fifth of patients. Therefore, PET/CT represents an important examination in the preoperative work-up of pancreatic adenocarcinoma.

Characterization of T Cell Responses against Shared Tumor Associated Antigens in Pancreatic Adenocarcinoma Patients

Tassi E^{1,5}, Gavazzi F², Zerbi A², Albarello L³, Balzano G², Braga M², Dellabona P^{4,5}, Di Carlo V², Protti MP^{1,5}

¹Unit of Tumor Immunology, ²2nd General Surgery, ³Pathology, ⁴Unit of Experimental Immunology, and ⁵Programma di Immunoterapia e Terapia Genetica dei Tumori', S. Raffaele Scientific Institute. Milan, Italy

Context Pancreatic adenocarcinoma (PA) is a highly aggressive, treatment refractory disease and the fifth cause of death from cancer. Median survival time is <6 months. New diagnostic and therapeutic strategies are needed. Immunotherapy represents one interesting experimental approach. Few defined tumor associated antigens (TAAs) are expressed in PA and very little is known on the PA immunogenic potential *in vivo*. **Aim** Final goal of our study is the development of a protocol of active immunotherapy in PA patients. Specific aims are to verify whether: i) shared TAAs exist in PA and if they are immunogenic *in vivo*, and ii) dendritic cells (DCs) pulsed with natural tumor peptides (NTPs) from allogenic PA induce *in vitro* anti-tumor specific T cells able to recognize the autologous tumor in PA patients. **Methods** *Ex-vivo* studies: CD4⁺ and CD8⁺ T cells from PA patients and healthy donors were purified, cultured for 5-10 days in the presence of MHC matched PA cells, and tested for cytokines release. *In vitro* studies: NTPs (mw 100-5,000 Dalton) were purified

from two primary PA tumor cell lines (DM, established in our laboratory and PaCa44, commercial). Autologous DCs pulsed with allogenic NTPs were used *in vitro* to stimulate CD8⁺ and CD4⁺ T cells from three healthy subjects and two patients (DM, BL). Activated CD8⁺ and CD4⁺ T cells were tested (proliferation, cytotoxic activity and cytokines release assays) to evaluate their tumor-specificity. **Results** *Ex-vivo* studies: preliminary results show the presence of CD4⁺ and/or CD8⁺ anti-PA specific T cells in three out of five patients studied. *In vitro* studies: NTPs pulsed DC induced CD4⁺ T cells, which recognize HLA-DR matched PA cells and tumor of different histology. Importantly, autologous DCs from one patient, pulsed with allogenic NTPs induced CD8⁺ and CD4⁺ T cells able to recognize and kill the autologous tumor. **Conclusions** These data strongly suggest the existence of shared TAAs among allogenic PA and that immunization with NTPs-pulsed DCs is a promising strategy to treat patients suffering from PA.

Pancreatic Massive Pleural Effusion in a Patient with Alcoholic Pancreatitis

Ventrucci M, Pozzato P, Venerato S, Vicari S, Cipolla A, Navarra G, Virzì S

Department of Internal Medicine and Gastroenterology and Department of Surgery,
Bentivoglio Hospital. Bologna, Italy

A 45-year-old man was admitted to the Gastroenterology Unit of our hospital on May 2005 because of the occurrence of painless pancreatic ascites and fever. His medical history revealed significant abuse of alcohol and cigarettes from the age of thirty, and an episode of acute abdominal pain with a relevant elevation of pancreatic enzymes in 2003. Abdominal US demonstrated massive fluid collection, a dilated Wirsung duct, a hypoechoic lesion of 1.5 cm in the body of the pancreas, and splenomegaly. Blood tests revealed a frank elevation of lipase and amylase, leukocytosis, and decreased albumin. Chest X-ray showed a right basal pleuritic inflammation. Contrast enhanced CT scan confirmed the US findings, revealing a small hypodense lesion indicating focal necrosis. Abdominal paracentesis was carried out (4 L of chylous liquid, rich in pancreatic enzymes: amylase 10,610 IU/L and lipase 12,200 IU/L) together with antibiotic, gabexate mesilate and octreotide treatment. The patient was discharged in apparently healthy conditions, but despite medical advice, went on drinking and smoking. On May 2006 he was readmitted to our hospital due to recent onset of pleuritic chest pain, dyspnea and coughing. At admission, the white cell count was 24,200/mL, C-reactive protein 2.5 mg/dL, and serum pancreatic amylase and lipase were 263 and 147 IU/L, respectively. Abdominal US showed fibrotic echo-texture pattern of the pancreatic gland, dilated main pancreatic duct, and a

pseudocyst of the head (4.1 cm) without ascites. A chest X-ray revealed a massive left pleural effusion with a partial collapse of the right middle and lower pulmonary lobes. Pleural fluid taken by thoracentesis was exudative and revealed high concentration of amylase (29,000 IU/L). Thoracentesis was complicated by large pneumothorax that was treated by chest tube insertion. Pneumothorax complication impeded performance of ERCP. Subsequent thoracoabdominal CT revealed a small left pleural effusion, and confirmed the pseudocyst in the pancreatic head without any apparent communication with the diaphragm and mediastinum. The patient was discharged with a long-term treatment of octreotide (0.1 mg subcutaneously *tid*) and a monitoring program which is in progress, based on abdominal US (the next within 30 days) and MR-cholangiopancreatography to ascertain if the pseudocyst is communicant with the pancreatic duct. This is a rare case of complicated alcoholic pancreatitis with a silent evolution towards pancreatic ascites and massive pleural effusion. The reasons for pleural involvement may be leakage of pancreatic fluid into the retroperitoneum and entry into the mediastinum or a pancreatic-pleural fistula. The choice of treatment (medical, US non operative, endoscopic or surgical) is still controversial. In this case, medical treatment was chosen because of the recent onset of the condition and the small size of the pancreatic pseudocyst.

Locally Advanced Pancreatic Cancer: Is There a Role for Neoadjuvant Chemo-Radiation? A Case Report and Literature Review

Zanini N, Casadei R, Angelelli B, Di Marco MC, Serra C, Piscitelli L, Minni F

Department of Surgical and Anesthesiological Sciences, Alma Mater Studiorum - University of Bologna, S.Orsola-Malpighi Hospital. Bologna, Italy

Context Pancreatic cancer resection represents the only chance of cure but it can

be performed only in localized cancer. Herein we report the case of a patient with locally

advanced pancreatic cancer who underwent neoadjuvant chemo-radiation therapy followed by surgical resection with no residual tumour (R0). **Case report** A 50-year-old man was referred to our team for the presence of jaundice. A CT showed a mass in the head of the pancreas with an encasement of at least 50% of the circumference of the superior mesenteric vein (SMV). The involvement of the SMV was considered a relative contraindication to surgery. The patient underwent an ERCP and a biliary stent was left in the common bile duct. Diagnosis of pancreatic ductal adenocarcinoma was done after a trans-abdominal US-guided fine-needle aspiration. A neoadjuvant chemo-radiation treatment was then offered to the patient who accepted. A pre-treatment staging PET showed an high metabolic activity area in the pancreatic head region and a quite similar area projected above the IV hepatic segment. The patient started 8 cycles of chemotherapy with gemcitabine and oxaliplatan then he underwent a chemo-radiation treatment of 6 week. A re-staging was then performed. CT revealed a decrease

of the size of the tumour. There was no involvement of the SMV. PET showed a completely remission of disease. In relation to these changes the patient was considered for surgical resection R0. A pylorus-preserving pancreaticoduodenectomy with tangential resection of the SMV was performed. Postoperative course was uneventful. Histological examination of the resected specimen showed microscopic ductal adenocarcinoma of the pancreas without neoplastic involvement of the lymph nodes; resection margins and vein wall tissue were cancer free (R0). At 19 months from diagnosis the patient is alive and well, and he remains free of recurrence or metastatic disease. **Conclusions** Even if, nowadays, neoadjuvant treatment is not a standard of cure in pancreatic cancer, studies have demonstrated local control in 87 to 100 percent of patients. According to the evidence of our and other cases we suggest to perform neoadjuvant chemo-radiation treatment in all patients affected by 'borderline resectable' pancreatic cancer.

Left Pancreatectomies and the Pancreatic Remnant: Stapler or Handsewn Closure?

Zanini N¹, Casadei R¹, Pezzilli R², Calculli L³, Fantini L², Ricci C¹, Grottola T¹, Minni F¹
Departments of ¹Surgical and Anesthesiological Sciences, ²Internal Medicine, ³Radiological and
Histocytopathological Sciences, Alma Mater Studiorum - University of Bologna,
S.Orsola-Malpighi Hospital. Bologna, Italy

Context Morbidity after left pancreatectomy remains high even in experienced centres ranging from 10 to 47%. Pancreatic fistula and leakage are the most common and dangerous complications. **Aim** The appropriate technique for closure of the pancreatic remnant is still debated: stapler or handsewn closure? **Methods** We retrospectively reviewed our data regarding 94 consecutive patients who underwent left pancreatectomies in our Institute since 1990. Post-operative mortality, morbidity and incidence of pancreatic fistula were evaluated

according to some prognostic factors (age, ASA score, hypertension, congestive heart failure, coronary artery disease, cerebrovascular disease, diabetes mellitus, COPD) and to pancreatic remnant treatment after left pancreatectomies (handsewn suture *versus* stapler suture). Data were evaluated using the Fisher's exact test. **Results** Overall post-operative morbidity and mortality were 20.2% and 2.1%, respectively (2 patients died during postoperative course for acute myocardial infarction). In 25 patients (26.6%) the pancreatic remnant was treated using a

stapler, in 69 patients (73.4%) the surgeon performed an handsewn closure. Eight patients (8.5%) developed a pancreatic fistula. All of them were conservatively treated with medical and/or radiological treatment. There was no significant difference in mortality, morbidity and incidence of pancreatic fistula for each prognostic factor analyzed. A fistula developed in 3 patients of 25 treated with a stapler (12.0%) and in 5 (7.2%) of the 69 patients in which an handsewn closure was

performed ($P=0.435$). **Conclusion** In this cohort of patients, co-morbidities are not linked to morbidity, mortality and incidence of pancreatic fistula. Despite the recent results published in worldwide literature which suggest the use of a stapler to treat the pancreatic remnant, in our cases the incidence of pancreatic fistula was higher, even if not statistically significant, in patients where a stapler closure was performed.

Pancreas Transplantation with Portal Drainage of Endocrine Secretion in the Treatment of Type 1 Diabetes

Zuber V, Socci C, Orsenigo E, Castoldi R, Parolini D, Gavazzi F, Panzeri F, Arru P, Polese M, Di Carlo V, Secchi A, Staudacher C
IRCCS San Raffaele Hospital. Milan. Italy

Context Results with pancreas transplants have improved significantly over the last few years due to refinements in surgical technique and an evolving immunosuppressive arsenal. **Aim** The aim of the study was to evaluate the outcome of pancreas transplantation with portal diversion of the insulin secretion in the treatment of type 1 diabetes. **Patients and methods** From July 1985 to May 2006 224 pancreas transplantations were performed in our Institute in diabetic (type 1) patients: 203 pancreas were transplanted simultaneously to the kidney (SPK), 6 pancreas were transplanted after kidney and 15 pancreas were transplanted alone. According to the different surgical technique we can divided this period in 3 eras: the period from 1985 to 1989 includes 36 segmental pancreas transplantation with occlusion of the duct by neoprene according to Dubernard's technique; the period 1990-1998 includes 75 duodenum-pancreas transplantation with bladder diversion of the exocrine secretion; in the period 1999-2006, 115 duodenum-pancreas

transplants were performed with enteric diversion. From 1998 we introduced the portal drainage of the endocrine secretion in pancreas transplantation. 25 patients received pancreas transplantation with portal diversion (22.5% of the patients transplanted from 1998). **Results** In the segmental pancreas group pancreas survival was 82%, 63%, and 15%, respectively at 1, 5 and 10 years. In the bladder diversion group, patient survival was 94%, 83%, and 73%, pancreas survival was 72%, 67%, and 65% at 1, 5 and 10 years. In the portal drainage group the patient survival was 100% at 6 years and the pancreas survival was 64% at 6 years. Nine grafts were removed early within the first days post-transplant: 5 grafts lost due to venous thrombosis (20%), 2 to primary non function (8%), one due to acute rejection (4%) and one to infection (4%). **Conclusions** Pancreas transplantation with portal drainage of the endocrine secretion is a valid technique in the treatment of type 1 diabetes.

POSTER SESSION

The Transcription Factor Pax6 in Human Pancreas and in Pancreatic Endocrine Tumors

Albarelo L, Fedele G, Piemonti L, Zerbi A, Di Carlo V, Doglioni C

Pancreas Unit, Scientific Institute Hospital San Raffaele, Milan, Italy

Context Pax6 belongs to the family of paired box genes that contain the hallmark paired box domain and a homeodomain. Pax6 is a transcription factor involved in the development of the central nervous system, the eye and the pancreas. Pax6 is expressed in developing and adult pancreas in mouse. Knockout pax6 mice fail to form islets. Pax6 expression in normal and neoplastic human pancreas has not yet been evaluated. **Aim** To evaluate Pax6 protein expression in developing and adult human pancreas and derived tumors. **Methods** Normal samples of fetal (12, 14, and 22 weeks), pediatric (1 and 4 years) and adult (25 and 55 years), formalin fixed-paraffin embedded pancreatic tissues were evaluated for Pax6 expression with an immunohistochemical technique. Two different antibodies, a monoclonal and a polyclonal one raised against different epitopes of Pax6, were utilized. Serial sections were immunostained for general neuroendocrine markers (chromogranin and synaptophysin). In order to evaluate coexpression, double immunostainings for insulin, glucagon, somatostatin, pancreatic polypeptide (PP) and Pax6 were performed. A large series of previously characterized pancreatic endocrine tumors (PET), including benign (n=43), borderline (n=35), well differentiated (WDEC: n=42) and poorly differentiated carcinomas (PDC: n=2) and

pancreatic ductal adenocarcinomas (n=40) were also immunostained with anti-Pax6 antibodies. **Results** Pax6 was expressed in the nuclei of the majority of pancreatic endocrine cells from the beginning of endocrine differentiation in the fetal pancreas till in the adult life. All insulin, glucagon and part of PP positive cells coexpressed Pax6. Somatostatin positive cells were negative for Pax6. Its reactivity was confined to the endocrine compartment; pancreatic acinar and ductal cells were negative. Both antibodies gave the same reaction pattern. No Pax6 immunoreactivity was observed in the ductal adenocarcinoma cases. Pax6 staining was present in 40 (51%) of benign and borderline PET cases and in only 5 (12%) of WDEC (P<0.001). PDC were negative. Pax6 expression was observed mainly in functioning tumors, with 65% of insulinoma cases strongly stained, whereas only 28% of non functioning PET were Pax6 reactive (P<0.01). **Conclusions** 1) Pax6 is expressed in developing and adult human endocrine pancreas; it is present in insulin, glucagons and part of PP cells; somatostatin positive cells are Pax6 negative. 2) Pax6 is expressed mostly in benign and borderline PET. 3) Most functioning tumors express Pax6. 4) Most WDEC and PDC show absent or reduced expression of Pax6. 5) Pax6 expression in PET is associated with a benign behaviour.

The Adequate Definition of Operative Mortality after Pancreaticoduodenectomy

Balzano G, Zerbi A, Gilardini C, Capitanio V, Gavazzi F, Scaltrini F, Polese M, Di Carlo V

Pancreas Unit, Department of Surgery, S. Raffaele Scientific Institute. Milan, Italy

Context An operative death after pancreaticoduodenectomy (PD) may occur

late in the postoperative period, due to persistent intra-abdominal complications and

prolonged intensive care unit treatment. An incorrect definition of the postoperative follow-up may underestimate the actual mortality after PD. **Aim** To assess the variability of the operative death rate after PD in a large group of patients by applying different definitions of postoperative follow-up. **Methods** English literature since 1990 was reviewed, considering articles reporting the operative outcome of at least 100 PD, looking for definitions of operative mortality. Five definitions of the postoperative follow-up period to consider operative mortality were identified in 75 articles: 30-day mortality (22 articles), 60-day mortality (2 articles), in-hospital mortality (25 articles), 30-day or in-hospital mortality (22 articles), and in-hospital plus 30-day after discharge (4 articles). **Results** The study group was made of 592 patients undergoing PD from 1995 to

2005. There were 20 in-hospital deaths occurring at 1-110 postoperative days. Two further patients died after being readmitted (decease at 24 and 41 days after PD). By applying the five definitions to the study group, the following death rates were recorded: 2.53% (15 patients), 3.38% (20 patients), 3.38% (20 patients), 3.54% (21 patients) and 3.72% (22 patients), respectively. The relative increase of mortality rate between the most limited and the most extensive definitions of postoperative follow-up was 32%. **Conclusion** Most articles reporting death rate after PD have inadequate definitions, that may underestimate the actual mortality up to 32%. An adequate definition should include in-hospital mortality (irrespective of the duration) and 30 days after discharge.

Role of Venous Drainage in Simultaneous Pancreas-Kidney Transplantation

Boggi U, Vistoli F, Del Chiaro M, Signori S, Moretto C, Mosca I, Croce C, Pugliese L, Sgambelluri F, Amorose G, Marchetti P, Rizzo G, Mosca F

Division of General and Transplant Surgery, Regional Referral Center for Pancreatic Diseases, University of Pisa. Pisa, Italy

Context Portal venous drainage (PD), as compared with systemic effluent (SE), improves the metabolic profile and reduces the occurrence of acute rejection episodes (ARE) of simultaneous pancreas-kidney transplant (SPKTx). **Methods** Data from 124 consecutive SPKTx were analyzed to determine the implication of venous drainage (PD vs. SE) on outcome, occurrence and severity of ARE, and metabolic profile. Overall, 52 SPKTx with PD were compared to 72 SPKTx with SE. The two groups were well matched for all donor and recipient baseline characteristics and managed with equivalent immunosuppressive regimens: low-dose steroids, basiliximab (54 SE vs. 51 PD) or thymoglobulin (18 SE vs. 1 PD; $P=0.0004$), cyclosporine (35 SE vs. 26 PD) or tacrolimus (37 SE vs. 26 PD), and

mycophenolate mofetil. **Results** The rate of delayed endocrine pancreas function was 8.3% in SE vs. 0% in PD ($P=0.03$). Equivalent figures for the kidney were 9.7% vs. 11.5%, respectively. Initial hospital stay averaged 37 days in SE vs. 29 days in PD. Overall, 14 recipients required 15 relaparotomy (12.1%) during the first 3 post-SPKTx months (SE 11.1% vs. PD 13.5%), including 4 allograft pancreatectomies (3.2%) due to vascular thrombosis (3 SE vs. 1 PD). One patient from either groups died from sepsis, although the overall incidence of infection was higher in SE (45.2%) vs. PD (19.2%) ($P=0.003$). Twenty-eight (38.8%) ARE were recorded in SE vs. 13 (25.0%) in PD. Glycemic control was excellent in both groups, but fasting serum insulin levels were significantly lower in PD. One-year patient

and kidney survival were equivalent in SE vs. PD (94.0% vs. 94.1% and 89.2% vs. 92.3%, respectively). Pancreas graft survival, on the contrary, was improved with PD (90.4%) as compared with SE (86.6%) (P=0.05).

Conclusions Our experience shows that PD is not detrimental for SPKTx recipients and can actually be associated with immunologic and metabolic advantages.

Contrast-Enhanced Endoscopic Ultrasound (CE-EUS) in the Evaluation of Pancreatic Masses

Carrara S, Arcidiacono PG, Mezzi G, Boemo C, Testoni PA

Division of Gastroenterology and Gastrointestinal Endoscopy, University Vita-Salute San Raffaele, Scientific Institute San Raffaele. Milan, Italy

Context EUS is an accurate technique for detection of pancreatic tumors, but differentiation between inflammatory masses and carcinoma may be difficult; moreover, neuroendocrine tumors (NET) show an ultrasonographic pattern sometimes similar to that of adenocarcinoma (ADK). The analysis of specific vascularity of a tumor can be an helpful tool for this differential diagnosis, being NET hyperperfused, while ADK shows an hypoperfused pattern. **Aim** To evaluate to role of CE-EUS in the diagnosis of pancreatic lesions. **Methods** We retrospectively reviewed all the cases performed from 2003 to 2006 in which ultrasonographic contrast medium (Sonovue, Bracco) was used to solve the doubt of a differential diagnosis. In 27 patients (18 men, 9 female; age 21-80 years; mean age 58 years) that underwent linear EUS (Pentax Prec Inst) because of a pancreatic mass, Sonovue (2.5 mL) was injected intravenously during the

examination. An EUS-guided FNA (Wilson Cook needle) was performed in every patient.

Results Ten patients showed typical hyperperfused solid lesions and they all had NET (sensitivity 100%). Four patients with solid homogeneous hyperperfused lesions had not NET at FNA: one had a lymphoid lesion, one a focal pancreatitis, one an IPMT and one a mucinous neoplasia (mostly solid, with cystic spaces). Thirteen patients had hypoperfused lesions: 8 had carcinoma, 2 had pancreatitis (one was an autoimmune pancreatitis), 3 patients had central hypoperfusion with peripheral hyperperfusion and the final diagnosis was pancreatitis. Specificity was 76%, while the negative predictive value was 100%. **Conclusions** CE-EUS provides additional information on vascularity of pancreatic lesions and is an important tool in the differential diagnosis of pancreatic masses.

Laparoscopic Distal Pancreatectomy in Children: Is It Feasible?

Cavallini A, Butturini G, Piccoli M, Boninsegna L, Armatura G, Melotti GL, Pederzoli P

General Surgery B, University Hospital 'GB Rossi'. Verona, Italy

Context Laparoscopic resection of benign tumors of the pancreas has been increasingly reported in adults; only four cases of partial laparoscopic pancreatectomy in children have been described in the English literature. **Case report** We described the case of an 11-year-old girl with a solid pseudopapillary tumor

(SPT) who was treated with a laparoscopic, spleen-preserving, distal pancreatectomy. Patient was in a supine position and we adopted an intraperitoneal approach with infragastric access to the pancreas which was resected using a linear stapler. The specimen was extracted in an endoscopic bag retrieval

system through a Pfannestiel incision. Operative time was 120 min and minimal blood loss occurred. The post-operative course was uneventful. Twenty-two months after the surgical operation, clinical follow-up (exocrine and endocrine pancreatic function as well) resulted normal. The functional and aesthetic results were satisfactory. **Conclusion** The technique used for our case

is simple and reproducible, was completed safely within a reasonable operative time, and yielded a good result. As experience with this technique continues to grow, laparoscopic distal pancreatectomy may well become the approach of choice in selected patients and seems to be ideal also for SPT in children, with the recommendation of a radical resection avoiding to break of the mass.

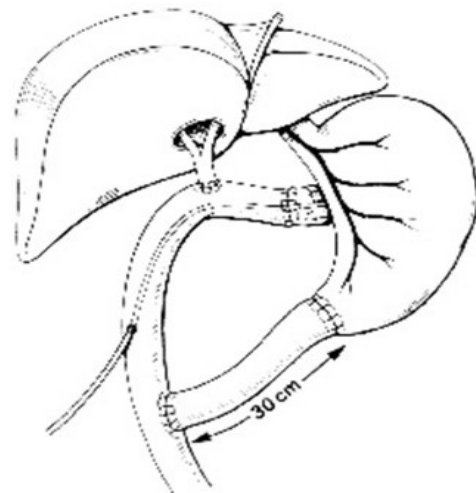
Reconstruction after Pancreaticoduodenectomy with a Double Jejunal Loop: Advantages and Technical Aspects of a Personal Technique

Chirletti P, Caronna R, Cardi M, Pittau G, Schiratti M, Romeo G, Tarantino E, Fanello G, Benedetti M, Marengo M, Sanna T, Spera G, Fusco G, Frantellizzi V

Emergency and Trauma 'B' Surgery, University of Rome 'La Sapienza', Umberto I Hospital. Rome, Italy

Context About pancreaticoduodenectomy three are the main points still discussed: extent of pancreatic resection, extent of gastric resection and need for a pancreatico-digestive anastomosis (closure of the duodenal stump, pancreatico-jejunal or pancreatico-gastric anastomosis). **Aim** The aim of the study is to underline the advantages of reconstruction after pancreaticoduodenectomy with a double jejunal loop, the impact on postoperative outcome and long-term functional results. **Patients and Methods** From 1995 and 2005, 40 patients underwent pancreaticoduodenectomy for pancreatic or periampullary cancer. The reconstruction was carried out by: gastric resection just above the pylorus with an end-to-side or end-to-end gastro-jejunal anastomosis (first jejunal loop); a Roux-en-Y T-T pancreatico-jejunal anastomosis leaving a silastic catheter in the Wirsung; hepatico-jejunostomy and jejuno-jejunostomy below the biliary anastomosis. **Results.** Post-operative mortality was 7.5%. Regarding the complications, we observed 4 biliary fistulas, mean duration 20 days (range 5-60 days) and 2 pancreatic fistulas with spontaneous healing in one and death in the other; and 9 wound infections. Postoperative 3-month re-evaluation showed weight gain in 24 patients with no other digestive symptoms (vomiting, fullness, dumping). No serious septic

complications were observed in all patients but one and also patients with biliary or pancreatic fistula tolerated early oral feeding. No jejunal peptic ulcers were noted in all patients after the gastric protonic pump inhibitors were discontinued. Fecal fats were evaluated in all cases for malabsorption 3 months after operation with low fat fecal levels. **Conclusion** A double loop reconstruction allows oral feeding without further complications even with biliary or pancreatic fistula. Resection of pylorus make oncological radicality possible and the gastro-jejunal anastomosis with the first jejunal loop maintain a better trophism of the pancreatic stump with better caloric intake, good gastric emptying and quality of life of the patients with pancreaticoduodenectomy.



Autoimmune Pancreatitis (AIP): Role of CT in the Diagnosis and Follow-up of the Disease

Cicero C¹, Graziani R¹, Manfredi R¹, Motton M¹, Baltieri S¹, Frulloni L², Pozzi Mucelli R¹
Departments of ¹Radiology and ²Surgical and Gastroenterological Sciences, University of Verona.
Verona, Italy

Context AIP is a mass-forming inflammatory lesion; clinical and cytological diagnosis is sometimes uncertain. CT is imaging modality useful to identifying AIP. **Aim** To describe the CT features of AIP and the CT changes after treatment. **Methods** 16 patients with AIP were retrospectively enrolled in this study. 8/16 had a positive history for ulcerative recto-colitis and 2/16 for autoimmune thyroiditis. Presenting symptoms were jaundice in 12/16 and abdominal pain in 4/16. None showed increased tumor markers (CA 19-9). The diagnosis of AIP was confirmed by pathologic examination of resected specimen 2/16, surgical 2/16 or biopsy 12/16; 14/16 underwent clinical follow-up after high dose steroid therapy. All patients underwent contrast-enhanced CT, at diagnosis. Furthermore CT was repeated after treatment with a mean interval:70 days (range 13-150 days). Image analysis was independently performed by 2 radiologists, and included: presence of calcification, parenchymal enlargement (focal/diffuse), pancreatic parenchyma vascularization (hypo/iso/hypervascular), presence/absence of delayed peripheral rim, pancreatic duct features (not

visualized/normal/enlarged), common bile duct (normal/enlarged). After treatment, CT features analyzed were: size of the pancreatic parenchyma (no change/reduced), size of common bile duct and main pancreatic duct (MPD) (no change/reduced), vascularization (no change/changed). **Results** None of the patients showed pancreatic calcification. 10/16 showed focal enlargement of pancreatic parenchyma and 6/16 diffuse enlargement. Both focal and diffuse disease appeared hypovascular during pancreatic phase. 12/16 of showed delayed peripheral pancreatic enhancement. Upstream MPD was dilated in 8/16 and normal in 12/16. The supra-pancreatic common bile duct was dilated in 12/16 and normal in 4/16. Following steroid therapy, the size of the pancreatic parenchyma was reduced in 10/14 and unchanged in 4/14. Pancreatic vascularization did not change in any of the Pts. Size of the MPD and of the common bile duct was reduced in 2/14 and in 12/14, respectively. **Conclusion** CT depicts AIP identifies its features at diagnosis and its response to steroid therapy during short follow-up.

Synchronous Multifocal IPMN and Colon Adenocarcinoma in an Elderly Patient: A Possible Strategy

De Raffele E, Buggi F, Lecce F, Mirarchi MT, Lombardi R, Dalla Via B, Cola B
Department of General Surgery and Organ Transplantation, 'Azienda Ospedaliero-Universitaria di Bologna', S. Orsola-Malpighi Hospital. Bologna, Italy

Context Intraductal papillary mucinous neoplasms (IPMNs) are a well-recognized pathologic entity of the pancreas that is being reported with increasing frequency and that mostly affect aged men. These tumours carry a relatively favourable prognosis and are frequently associated to extra-pancreatic

malignancies which may be more relevant than IPMN itself in determining the patient's survival. The matching of advanced age and co-existence of two neoplasms challenges the planning of the best treatment option. **Case report** a 78-year-old man without a history of alcohol abuse and cigarette smoking

presented with a rectal bleeding which led to the diagnosis of a stenosing adenocarcinoma of the sigmoid colon. No metastatic lesion was present but a 3-cm IPMN was detected in the uncinata process of the pancreas; small diffused dilations of the side branches were present in the body and tail of the gland. The CA 19.9 dosage inside the cyst was >10,000 U/mL and CEA concentration was 5,726 ng/mL. A two-stage procedure was planned: an R0 sigmoid resection was undertaken first with an uneventful post-operative course and the pathologic evaluation reported a stage III (pT3, N1, M0)-adenocarcinoma. Forty-five days after the first operation a duodeno-pancreatectomy was performed and the post-operative course was uneventful apart from a

delayed gastric emptying. The histology showed an IPMN (bilio-pancreatic and gastric histologic type) involving either the main duct and the side ones; most of the lesions were borderline according to WHO but foci of non-invasive carcinoma were present.

Conclusions The co-existence of a potentially malignant and potentially multifocal pancreatic tumour with an extra-pancreatic overt malignancy in elderly patients poses difficulties in the attempt to cure with minimal morbidity. In the present case we considered essential the characterization of the prognosis dictated by the colon cancer before planning a further duodeno-pancreatectomy in a 78-year-old man.

Case Report. Wirsung's Duct Dilatation without Pancreatic Focal Lesions at Imaging: Is It a Cancer of the Pancreatic Head?

Degrate L¹, Nobili C¹, Franciosi C¹, Caprotti R¹, Perego E¹, Leone BE², Uggeri Fr¹

Departments of ¹Surgery and ²Clinical Pathology, San Gerardo Hospital, University of 'Milano-Bicocca'. Monza (MI), Italy

Context Pancreatic adenocarcinomas histologically classified as T1 (i.e. tumours limited to pancreas, 2 cm or less in greatest dimension) correspond to 8% of all pancreatic cancers and show a constant rise of their incidence. Although their limited size, only 16-25% does not show metastasis in the locoregional lymph nodes (corresponding to stage T1N0). We report the case of a patient with Wirsung's duct dilatation without focal pancreatic lesions at imaging, and subsequent uncovering of stage T1N0M0 adenocarcinoma of the pancreatic head on the surgical specimen. **Case report** A 73-year-old man referred to our Department for anorexia, weight loss, back pain and recent discovery of diabetes mellitus. Blood exams were significant only for elevation of CA 19.9 (433 U/mL) and amylases (281 U/mL). The patient has been firstly investigated with abdominal US, EGD and colonoscopy, without evidence of abnormalities. Afterwards he has been investigated with

abdominal MR, abdominal CT, EUS and PET, revealing homogeneously dilated Wirsung's duct (10 mm), but no focal lesions in the pancreatic gland. After an attempt of ERCP, the patient underwent explorative laparotomy with evidence of a mass in the pancreatic head: therefore a pylorus-preserving pancreaticoduodenectomy was performed. The histopathologic analysis showed ductal adenocarcinoma with greatest dimension of 1.4 cm (T1N0G2) in the neck of the pancreas, and disease-free resection margins. At 1-year follow-up the patient shows local relapsing disease without response to radiotherapy. **Conclusion** Every effort is necessary to early diagnose pancreatic cancers, because stage I tumors show a good prognosis after surgical resection, with 5-year survival of 40-58%. Nevertheless, at the present time, imaging techniques (CT, MRI, EUS, PET) reveal low sensibility for small pancreatic tumors, hardly carrying out an early diagnosis. In this

context, an useful radiological diagnostic sign is the dilatation of Wirsung's duct that, even

in absence of focal lesions, is a high risk marker of early stage pancreatic cancer.

Preoperative Assessment of Pancreatic Tumors with Linear Endoscopic Ultrasonography and Multi-Detector CT

Di Matteo FM¹, Pandolfi M¹, Martino M¹, Shimpi L¹, Gabbrielli A¹, Costamagna G²

¹Digestive Endoscopy Unit, Department of Digestive Diseases, Campus Bio-Medico University of Rome; ²Surgical Endoscopy Unit, Catholic University. Rome, Italy

Context and Aims To prospectively assess the accuracy of linear endoscopic ultrasound (EUS) in the preoperative evaluation of pancreatic cancer in comparison with 16-row multi-detector computed tomography (MDCT). We considered the role of both techniques in the detection, localization and staging of pancreatic cancer. **Methods** Between September 2003 and February 2005, 56 patients suspected for pancreatic tumor were evaluated with MDCT and by EUS-FNA. 23/56 patients were considered in the study considering the results of the biopsies. All patients underwent surgical resection. A linear array echoendoscope (frequency 5/7.5/10 MHz) (EG3830UT, Pentax Europe GmbH) was used. MDCT (Somatom Sensation, Siemens Medical Systems, Erlangen, Germany) examinations were performed with triphasic technique (basal, arterial and portal phase), after the injection of contrast agent. The exclusion criteria were: neuroendocrine tumors (confirmed at EUS-FNA), ampullary tumors, a MDCT without pancreatic protocol, no cytologic or pathologic diagnosis. The preoperative EUS and MDCT staging was evaluated against the

pathology findings. **Results** EUS is more sensitive than MDCT in tumor detection and characterization, mostly in case of cystic neoplasm, and in evaluation of tumor size. MDCT has the highest accuracy in assessing extent of locoregional extension (MDCT 18/23 vs. EUS 15/23; 78% vs. 70%) and the presence of distant metastases (MDCT 5/6 vs. EUS 3/6; 83% vs. 52%). EUS has the highest accuracy in assessing tumor size (EUS 28/32 vs. MDCT 26/32; 87% vs. 83%), lymph node involvement EUS 9/14 vs. MDCT 8/14; 64% vs. 57%) and vascular invasion (EUS 10/12 vs. MDCT 9/12; 83% vs. 75%). **Conclusion** From these preliminary report the T stage accuracy in pancreatic cancer is substantially less than previously reported. The combination of superior detection, good staging, tissue diagnosis and potential therapy could make EUS(FNA) a cost effective modality. Further cost minimization analysis is needed to establish which strategy based on MDCT and EUS, performed either simultaneously or sequentially, increased the cost of tumor staging with respect to individual technique.

Contrast-Enhanced Ultrasonography (CEUS) of Pancreatic Adenocarcinoma

Faccioli N, D'Onofrio M, Malagò R, Martone E, Pozzi Mucelli R

Department of Radiology, University of Verona. Verona, Italy

Aim To correlate the enhancement patterns of pancreatic adenocarcinoma at contrast-enhanced ultrasonography (CEUS) with the

results of surgical resection of the tumor at pathology. **Methods** Between May 2002 and September 2005, 241 patients (range: 32-83

years, mean age: 62.5 years) affected by pancreatic ductal adenocarcinoma were studied with contrast-enhanced ultrasonography (CEUS) with second generation contrast medium. The enhancement pattern at CEUS was divided in low (hypoechoic lesions to the adjacent parenchyma) or high (isoechoic-hyperechoic lesions to the adjacent parenchyma). The resected tumors were evaluated at pathology for the presence of positive neoplastic (+) or negative neoplastic (-) resected margins (R). **Results** 67/241 (27.8%) tumors were resected. 35/67 (52.3%) resected tumors resulted R- (28.4 mm mean diameter, 25 head, 4 uncinata process, 5 body, 1 tail) at

pathology, while 32/67 (47.7%) showed R+ (31.6 mm mean diameter, 20 head, 3 uncinata process, 8 body, 1 tail). In the R- group 27/35 (77.1%) tumors showed low enhancement at CEUS. In the R+ group 16/32 (50.0%) lesions showed high enhancement at CEUS. The positive predictive value of the high enhancement of the tumor at CEUS in predicting the presence of positive neoplastic resected margins is 67% with a negative predictive value of 63%. **Conclusion** On the basis of our results the pattern of enhancement of pancreatic adenocarcinoma at CEUS should be purposed as complementary predictive factor for tumor resectability.

Quality of Life and Clinical Indicators for Chronic Pancreatitis Patients in a Two-Year Follow-up Study

Fantini L, Pezzilli R, Morselli Labate AM, Gullo L, Corinaldesi R

Department of Internal Medicine and Gastroenterology, Sant'Orsola-Malpighi Hospital, University of Bologna. Bologna, Italy

Context There are no data available which evaluate the possible modifications of the quality of life during the clinical course of chronic pancreatitis. **Aims** To evaluate the outcomes for chronic pancreatitis patients in a two-year follow-up study. **Patients** One-hundred and four patients with chronic pancreatitis were studied (91 M, 13 F, mean±SD age 57.0±11.1 years; mean age at the onset of the pancreatitis 39.3±13.7 years, mean time interval between diagnosis and admission to the study 219±137 months). The etiology was alcohol abuse (more than 80 g/day) in 90 patients (86.5%), due to other causes in 5 (4.8%) (hereditary pancreatitis in 4, autoimmune pancreatitis in 1), and unknown in the remaining 9 patients (8.7%). Sixty-eight patients (65.4%) had pancreatic calcifications, 43 (41.3%) had pseudocysts and 72 (69.2%) had a dilatation of the Wirsung duct compatible with chronic pancreatitis. Thirty-nine patients (37.5%) had pancreatic pain in the month prior to enrolment. Thirty-two patients (59.3%) had

pancreatic insufficiency and 60 (57.7%) had diabetes secondary to pancreatitis. Pancreatic surgery was carried out on 51 patients (49.0%) and 20 of them (39.2%) had experienced an episode of pain in the month before the interview. Four patients (3.8%) underwent endoscopic pancreatic sphincterotomy for their disease and one (25.0%) had pain in the month before the interview. Of the 104 patients, 58 (55.8%) underwent non-pancreatic surgery and 67 (64.4%) had one or more comorbidities. **Methods** The SF-12™ Health Survey Italian version questionnaire was used. The questionnaire generates two scores: the physical component summary (PCS-12) and the mental component summary (MCS-12). **Results** Eighty-three patients completed the study; the interval time between the first and the second evaluation was of 2.3±0.2 years (mean±SD). The 21 patients who did not complete the questionnaire had a PCS-12 (36.3±11.1) and an MCS-12 (38.3±13.9) significantly lower (P=0.003) than those of

the 83 patients who completed the questionnaire (PCS-12: 43.7±9.8, MCS-12: 44.3±11.4). During the follow-up there was a significant increase in the frequency of diabetes mellitus (P=0.008), non-pancreatic surgery (P=0.016), and comorbidities (P=0.004). The PCS-12 (44.7±10.7) and MCS-12 (44.1±13.3) were not significantly different in comparison to the baseline evaluation (PCS-12: 43.7±9.8, MCS-12: 44.3±11.4). Seventeen patients (20.5%) worsened their PCS-12 score, 44 (53.0%) had a stable PCS-12 score, and the remaining 22 (26.5%) improved their PCS-12 score. Regarding the mental score, 15 patients

(18.1%) worsened, 52 (62.7%) had a stable MCS-12 score, and the remaining 16 (19.3%) improved the MCS-12 score. Only age at diagnosis was significantly related to the change of the MCS-12 score (P=0.028, positive relationship). **Conclusions** The information given by quality of life assessment should be routinely included in the work-up of patients affected by chronic pancreatitis, even if the subjects who do not complete the questionnaire are those with severely impaired physical and mental scores and they need of an intensive program of medical and psychological follow-up.

The Transcription Factor Nkx6.1 in Human Pancreas and in Pancreatic Endocrine Tumors

Fedele G, Albarello L, Arrigoni GL, Piemonti L, Zerbi A, Di Carlo V, Doglioni C
Pancreas Unit, Scientific Institute Hospital San Raffaele, Milan, Italy

Context Nkx6.1 belongs to the family of Nkx family of homeobox containing transcription factors. Nkx6.1 is a bifunctional transcription factor that maintains expression of its own gene during beta-cell differentiation while simultaneously effecting repression of other genes, in particular suppressing glucagon expression. Its function is critical for the formation of the insulin-producing beta-cells in mouse: knockout Nkx6.1 mice dies soon after birth with severe diabetes. Nkx6.1 expression in normal and neoplastic human pancreas has not yet been evaluated. **Aim** To evaluate Nkx6.1 protein expression in developing and adult human pancreas and derived tumors. **Methods** Normal samples of fetal (12, 14, and 22 weeks), pediatric (1 and 4 years) and adult (25 and 55 years), formalin fixed-paraffin embedded pancreatic tissues were evaluated for Nkx6.1 expression with immunohistochemistry. A recently generated monoclonal antibody raised against Nkx6.1, clone F55A10, was utilized. Serial sections were immunostained for general neuro-endocrine markers (chromogranin and

synaptophysin). In order to evaluate coexpression, double immunostainings for insulin, glucagon, somatostatin, pancreatic polypeptide (PP) and Nkx6.1 were performed. A large series of previously characterized pancreatic endocrine tumors (PET), including benign (n=39), borderline (n=34), well differentiated (WDEC: n=41) and poorly differentiated carcinomas (PDC: n=2) and pancreatic ductal adenocarcinomas (n=40) were also immunostained with anti-Nkx6.1 antibody. **Results** Nkx6.1 was expressed in the nuclei of a fraction of pancreatic endocrine cells from the beginning of endocrine differentiation in the fetal pancreas till in the adult life. All insulin positive cells coexpressed Nkx6.1. Glucagon, somatostatin and PP positive cells were negative for Nkx6.1. Pancreatic centroacinar and ductal cells were weakly positive. Acinar cells were negative. No Nkx6.1 immunoreactivity was observed in the ductal adenocarcinoma cases. Nkx6.1 staining was present in 46 (63%) of benign and borderline PET cases and in only 7 (17%) of WDEC (P<0.001). PDC were

negative. Nkx6.1 expression was observed mainly in functioning tumors, with 74% of insulinoma cases strongly stained, whereas only 37% of non functioning PET were Nkx6.1 reactive ($P < 0.001$). **Conclusions** 1) Nkx6.1 is expressed in developing and adult human endocrine pancreas; it is present in insulin positive cells; glucagons, PP and

somatostatin producing cells are Nkx6.1 negative. 2) Nkx6.1 is expressed mostly in benign and borderline PET. 3) Most functioning tumors express Nkx6.1. 4) Most WDEC and PDC show absent or reduced expression of Nkx6.1. 5) Nkx6.1 expression in PET is associated with a benign behaviour.

Peripancreatic Vascular Anatomic Variations: Impact of Radiological Diagnosis with Multidetector Computed Tomography (MDCT) on Surgical Strategy

Fiscaletti M¹, Calculli L¹, Casadei R², Pezzilli R³, Brindisi C¹, Renzulli M¹, Gavelli G¹
Departments of ¹Radiology, ²Chirurgia, and ³Internal Medicine, S. Orsola-Malpighi Hospital, Bologna, Italy

Context The advent of multidetector computed tomography (MDCT), non invasive and extremely fast imaging technique, can be considered the diagnostic gold standard in study of abdominal vessels. **Aim** To evaluate the impact that the diagnosis of peripancreatic vascular anatomic variations (including arteries and veins) can cause on surgical approach of patients with pancreatic cancer. The MDCT technique, using dynamic protocols, can help to detect the best surgical strategy. **Methods** 60 consecutive patients affected by pancreatic cancer (38 male, 22 female, average 65 years; dimensions between 2 and 5 cm) were scanned with MDCT with particular regard to abdominal vessels. The MDCT scans were performed with the triphasic technique at 0.75 mm during the arterial phase and at 1.5 mm during the other ones. We analyzed arterial, venous and venous Hendle's trunk vascular anomalies. **Results** Arterial vascular district: 60 patients were examined: only 20 had vascular anomalies. In 2 patients the origin of common hepatic artery was aorta and in 4 was

superior mesenteric artery (AMS); in 7 cases the origin of right hepatic artery was AMS and in 2 the right and the left branch of hepatic artery originated from the celiac trunk but separately; in 2 studies the hepatic and the splenic artery had different beginning and in 2 the left branch of hepatic artery originated from the left gastric artery. One cases reported an aneurismatic dilatation of an anomalous gastro-hepatic vessel. Venous vascular district: in 25 cases the inferior mesenteric vein leaded the splenic vein, in 3 the spleno-mesenteric confluence and in 2 patients the superior mesenteric vein. Hendle's trunk: was longer than 1 cm in 40 studies, smaller than 1 cm in 2 and the including vessels always run separated. **Conclusions:** The most important vascular anomalies concern the origin of hepatic artery from AMS and the anomalous confluence of VMI in mesenteric-portal trunk. The identification and the extension of Hendle's trunk are very important regarding a correct surgical approach on mesenteric-portal vessels.

Is Triple Phase Multidetector Computed Tomography (MDCT) Useful in the Evaluation of Pancreatic Endocrine Tumours?

Gusmini S¹, Nicoletti R¹, Martinenghi C¹, Caborni C¹, Zerbi A², Del Maschio A¹

Departments of ¹Radiology, and ²Surgery, Vita-Salute University, San Raffaele Hospital. Milan, Italy

Aim To assess if triple-phase technique is the best choice in the evaluation of pancreatic endocrine lesions. **Materials and methods** Twenty-two proven pancreatic lesions were retrospectively evaluated. All the lesions were studied with MDCT triple-phase technique performed with 16-channel CT scanner and were submitted to surgical treatment (n=18) or endoscopic ultrasonography guided fine needle aspiration cytology (n=4). Images obtained during each phase were interpreted distinctly by two senior radiologists, experienced in pancreatic pathology, in blinded evaluation. The attenuation of the endocrine tumours and of normal pancreas and the mean absolute tumour-to-gland attenuation difference, in arterial, pancreatic and portal phases were measured. Furthermore, the detection of arterial variations and of hypervascular liver metastases was analysed. **Results** Mean tumour-to-gland attenuation difference was greater in images obtained in pancreatic phase

for both the observers (59±34 HU and 57±41 HU) *versus* those obtained in arterial (46±25 HU and 42±34 HU) and in portal phases (30±28 HU and 36±41 HU). The mean absolute tumour-to-gland attenuation difference in arterial/pancreatic phases resulted significant (P=0.007) for one radiologist, whereas it was not significant for the other (P=0.082). Arterial variations and hypervascular liver metastases were detected in the pancreatic phase as well as in the arterial phase. **Conclusions** In our experience, in the evaluation of endocrine pancreatic tumours, the data obtained in arterial and pancreatic phases were not significantly different, mean tumour-to-gland attenuation differences were greater in pancreatic phase. Therefore triple-phase technique can be assessed not to be the best choice and dual-phase technique should be performed because arterial phase can be considered not necessary.

The Dagradi-Serio-Iacono Procedure: Central Pancreatectomy. Personal Experience and Literature Review of 353 Cases

Iacono C, Ruzzenente A, Bortolasi L, Facci E, Frisini M, Pachera S, Guglielmi A

Department of Surgery and Gastroenterology, University of Verona. Verona, Italy

Contexts Central pancreatectomy was first performed by Dagradi and Serio in 1982 and was described by them in 1984 in Enciclopedia Medica Italiana. In the last two decades Serio and Iacono have spent their effort to spread central pancreatectomy with correct indications that must be benign or low grade malignant tumors located in the pancreatic isthmus. **Patients and methods** From January 1982 to December 2004 at the

Department of Surgery of the University of Verona 20 patients underwent central pancreatectomy. In the English literature (1988 to October 2005), 353 patients (350 laparotomic and 3 laparoscopic) have been reported. **Results** In our cases the diagnosis were: 8 endocrine tumors, 7 serous cystadenomas, 3 mucinous cystadenomas, 1 solid cystic papillary tumor and 1 metastasis from renal cancer. Mortality rate was 0% and

the incidence of pancreatic fistula was 25%, all of which were resolved by conservative management within one month. None of the patients underwent re-operation. Mean hospitalization time was 18 days. At follow-up time of months none of the patients has shown local recurrence. Tumour pathology is available in 333 out of 373: the main indication for CP is serous and mucinous cystadenoma (124 patients) followed by endocrine tumours (96 patients) and intraductal mucinous producing neoplasms (IMPN) in 44 cases. The most performed reconstruction has been pancreatico-jejunojejunostomy followed by pancreatico-gastrostomy. Considering all the cases (373)

morbidity and mortality rate is 35% and 0.2%, respectively, while re-operation rate is 6%. Recurrence rate is 2.3% due to incorrect indication (carcinoma and IMPN). Endocrine and exocrine insufficiency is 4% and 4.3%, respectively. **Conclusions** Central pancreatectomy has to be considered as one of the technical tools in the hands of a pancreatic surgeon for benign or low grade malignant tumors. Results of Dagradi-Serio-Iacono operation are good when correctly applied. However, seen the limited number of cases for a single Institution, we suggest for the future to collect all the new cases in a database to value more precisely the data.

Prognostic Factors in Advanced Pancreatic Adenocarcinoma: An Analysis of 211 Patients Submitted to Intra-Arterial Chemotherapy Mambrini A¹, Pacetti P¹, Iacono C², Fiorentini G³, Ballardini M⁴, Orlandi M¹, Sanguinetti F⁵, Cantore M¹

¹Department of Oncology. Massa-Carrara, Italy. ²First Department of General Surgery, University of Verona. Verona, Italy. ³Department of Oncology, Empoli, Italy. ⁴Istituto Oncologico Romagnolo⁷, Forlì, Italy. ⁵Department of Radiology. Massa-Carrara, Italy

Context Advanced pancreatic carcinoma (APC) is a rapidly fatal disease with an overall 5-year survival rate of less than 4%. Standard treatment remains systemic gemcitabine. Intra-arterial chemotherapy (IAC) has a deep rationale, is very well tolerated and seems to produce interesting response rate and survival. **Aim** To identify the prognostic factors of a large group of patients with pancreatic cancer, submitted to the same regimen of IAC. **Methods** 5-fluoruracil 1,000 mg/m², leucovorin 100 mg/m², epirubicin 60 mg/m² and carboplatin 300 mg/m² were administered every 3 weeks into celiac axis (FLEC regimen). Kaplan-Meier survival curve for univariate analysis and Cox regression model for multivariate one were used to determine factors predictive

of survival. **Results** Data of 211 patients with APC submitted to FLEC regimen were analysed. Eighty-nine had locally advanced disease and 112 had distant metastases. Median overall survival (OS) was 9.2 months. In both univariate and multivariate analysis, stage of disease (III vs. IV: OS 10.5 vs. 6.6 months), number of administered cycles (≤ 3 vs. >3 : OS 5.9 vs. 12.3 months) and pain reduction after treatment ($\leq 30\%$ of baseline level vs. $>30\%$: OS 7.6 vs. 11.5 months) were significant and independent predictors of survival. **Conclusions** Stage of disease, number of administered cycles and pain reduction are independent prognostic factors of OS in a multivariate analysis of patients with APC receiving FLEC regimen intra-arterially.

Early Bacterial Infection of the Pancreas and Course of Disease in Cerulein-Induced Acute Pancreatitis in Rats

Manes G, Greco S, Kahl S, Malfertheiner P, Bianchi Porro G

Department of Gastroenterology University Hospital 'L. Sacco'. Milan, Italy.
University of Magdeburg. Magdeburg, Germany

Context and aim Bacterial infection of the pancreas aggravates the course of necrotizing acute pancreatitis. Since bacterial translocation from the gut is likely to be an early event, in an animal model of edematous pancreatitis, we investigated the effect of early bacterial supra-infection of the pancreas on the course of the disease, i.e. evolution of an edematous in a necrotizing form. **Methods** 6 hours after the induction of acute pancreatitis in male Wistar rats (n=180) by supramaximal stimulation with cerulein (or placebo in a control group), the animals were operated and a suspension of *H. pylori*, *E. coli* or saline were introduced either in the pancreatic duct or interstitium (12 groups of 15 rats each); after 24 hours, animals were killed and the following parameters analyzed: macroscopic and histologic appearance of the

pancreas (score), wet-to-dry weight ratio, pancreas trypsinogen activation peptide level, serum amylase, interleukin-6 and phospholipase A2 activity. **Results** All parameters were increased in rats with cerulein-induced pancreatitis in comparison to placebo. Interstitial and intraductal application of bacteria increased the pancreatic damage. This effect was most evident with the application of *E. coli* in both cerulein and placebo groups. Application of *E. coli* but not of *H. pylori* determined pancreatic activation of trypsinogen, increased mortality and induced the production of interleukin-6. **Conclusion** Bacterial invasion of the pancreas worsens the histologic and clinical picture of disease and induces a systemic inflammatory response.

Expression and Function of CX3CR1 Receptor for CX3CL1/Fractalkine on Pancreatic Tumour Cells and Its Involvement in Tumour Dissemination

Marchesi F¹, Malosio ML², Monti P², Destro A³, Roncalli M³, Doglioni C⁴, Scaltrini F⁴, Di Carlo V⁴, Mantovani A^{1,5}, Piemonti L², Allavena P¹

Departments of ¹Immunology and ³Pathology, 'Istituto Clinico Humanitas'. Rozzano, Italy. ²JDRF Telethon Center for Beta Cell Replacement, and ⁴Department of Surgery, S. Raffaele Scientific Institute. Milan, Italy. ⁵Institute of Pathology, University of Milan. Milan, Italy

In this study we have analyzed the presence of the chemokine receptor CX3CR1 on 11 pancreatic tumor cell lines and tumor cells from surgical samples of patients with pancreatic adenocarcinoma. Six of eleven pancreatic tumor cell lines express significantly higher amounts of CX3CR1 transcripts, compared to a cell line derived from normal ductal epithelium used as reference. CX3CR1 is also expressed in 7/7

primary tumor cells isolated from surgical specimens (>95% cytokeratine-7 positive). Flow cytometric analysis with a specific mAb confirmed these results at the protein level. We also tested the functional activity of CX3CR1-positive tumor cells. AsPC1 and A8184 dose-dependently migrated in response to the specific ligand CX3CL1 (Fractalkine) in classical chemotaxis assays and this effect was blocked by specific anti-

CX3CR1 antibodies. CX3CL1 also functions as an adhesion molecule. CX3CR1-positive pancreatic tumor cells showed enhanced adhesion to CX3CL1-coated plastic as well as to neuroblastoma cells (SKN-BE) which produce and release CX3CL1 upon stimulation with TNFalpha/IFNgamma. Pancreatic tumor cell adhesion was specifically inhibited by antibodies anti-

CX3CL1. Transfection of CX3CR1 cDNA in a receptor-negative tumour cell line conferred the ability to respond to CX3CL1 in migration and adhesion assays. Overall these results demonstrate that functional Fractalkine receptor is expressed in pancreatic cancer cells and could be involved in tumor dissemination.

Same-Day ERCP Following Trans-Duodenal EUS-Guided Needle Aspiration. Need for a Cautious Approach?

Martino M¹, Di Matteo FM¹, Pandolfi M¹, Shimpi L¹, Costamagna G², Gabbrielli A¹

¹Digestive Endoscopy Unit, Department of Digestive Diseases, Campus Bio-Medico University of Rome. ²Surgical Endoscopy Unit, Catholic University. Rome, Italy

Context Patients undergoing EUS-guided fine needle aspiration (EUS-FNA) for suspected pancreatic tumours frequently undergo ERCP for palliation of symptoms. Performing EUS-FNA and ERCP in immediate sequence may be a cost-effective and convenient management protocol and may reduce total procedure time. However, the potential risks associated with this approach are not clearly defined. **Case report** We report two cases of patients who underwent same-day therapeutic ERCP following trans-duodenal EUS-FNA for a cystic pancreatic tumour and for a solid pancreatic mass. Endoscopic biliary manipulation during ERCP aggravated an inadvertent and sub-clinical needle puncture injury to the bile duct sustained during preceding EUS-FNA. This resulted in leakage of bile into the retroperitoneal space. Worsening clinical condition warranted subsequent laparotomy and surgical drainage in both patients. At our Centre, a review of medical records of all patients undergoing EUS-FNA of pancreatic lesions during a 30

month period (June 2003 - December 2005) revealed an overall procedure-related complication rate of 1.1% (n=1/86), which is equivalent to that reported in literature. This patient developed infection of pancreatic cystic lesions after undergoing EUS-FNA, but responded to antibiotic therapy. The two above reported cases are the only ones in which therapeutic ERCP was performed immediately within a few hours following trans-duodenal EUS-FNA of pancreatic head lesions and both developed a clinically significant biliary leak. **Conclusion** Evidence on the risks of performing these two procedures in this sequence is limited. Furthermore, the incidence of unrecognised bile duct injuries during trans-duodenal EUS-FNA of pancreatic lesions, especially in presence of a dilated bile duct, has not been studied. Additional clinical evidence is needed to clarify these issues and determine whether it would be prudent to perform therapeutic ERCP prior to diagnostic trans-duodenal EUS-FNA in case both procedures are planned in immediate sequence.

Acute Biliary Pancreatitis: Timing of the Endoscopic Sphincterotomy (ES) and of the Videolaparocholecystectomy (VLC)

Neri V, Ambrosi A, Fersini A, Tartaglia N, Valentino TP, Santacroce C

Division of General Surgery, Department of Surgical Sciences, University of Foggia, Foggia, Italy

Context There is not uniformity in the literature about the timing of execution of the endoscopic sphincterotomy (ES) and later the videolaparocholecystectomy (VLC) in course of acute biliary pancreatitis (ABP). **Aim** The aim of the study was to suggest the optimal timing of the ES and, so, the VLC. **Methods** In the period from September 1997 to November 2005, 87 patients were treated for ABP. 25 cases were severe ABP and 62 were mild ABP. In 70 patients an ES was executed within 48-72 hours; in 17 cases the ES was delayed of 10 days. After 8-10 days, 82 patients had a VLC; 5 patients had an open cholecystectomy. **Results** The choledochal stone was removed in 42 cases (48.2%); in the last 45 patients (51.7%) the biliary sand or sludge was removed. Immediate results: 1 case (1.1%) of post-ERCP pancreatitis, 6

cases (6.9%) of asymptomatic increase of the lipasemia and amylasemia, 2 (2.3%) duodenal perforations. The laparoscopic and open cholecystectomy, did not have relevant complications. Later in time we have registered the develop of 3 post-necrotic pancreatic pseudocysts, treated with surgical therapy. **Conclusion** The ES in course of severe and mild ABP has the double goal to clean the principal biliary duct by the stones, and moreover to remove the papilla's obstacle because of stenosis, biliary sand or sludge. In our experience, the golden therapeutic timing foresees the ES within 48-72 hours from the beginning of the symptomatology and the VLC within 8-10 days: this time is necessary to establish the absence the progression of the acute pancreatitis.

Association between Preoperative Platelets Count and Tumor Stage in Pancreatic Adenocarcinoma Patients. Results of an Observational Study

Nobili C¹, Degrate L¹, Franciosi C¹, Caprotti R¹, Leone BE², Trezzi R², Perego E¹, Uggeri Fa¹, Uggeri Fr¹

Departments of ¹Surgery and Clinical ²Pathology, San Gerardo Hospital, University of 'Milano-Bicocca'. Monza (MI), Italy

Context Platelets (PTL) and PTL-derived factors are thought to participate in tumor progression and metastasis; increased preoperative PTL count is associated with more invasive pancreatic adenocarcinomas. **Aim** To investigate the relationship between preoperative PTL count and tumor stage in pancreatic adenocarcinoma patients. **Methods** Between September 2002 and March 2006, 26 patients underwent complete surgical pancreatic resections. Patients were divided into 2 groups, basing on preoperative PTL level $\geq 300 \text{ mL}^{-1}$ (group A) or $< 300 \text{ mL}^{-1}$

(group B), that is the median level of the normal PTL range provided by our laboratory. Group A included 2 pancreaticoduodenectomies (PD), 2 splenopancreatectomies (SP) and 1 total pancreatectomy, while group B included 16 PD and 5 SP. The histopathologic analysis showed pancreatic adenocarcinoma in all surgical specimens. Tumor extension (T), nodal status (N), tumor differentiation (G), and perineural invasion were assessed for each specimen. **Results** The two patients groups showed the same tumor proportion concerning TN stage and perineural invasion:

the majority of the cancers was T3N1 and positive for perineural invasion. Nevertheless, the only difference was that in group A 80.0% of tumors was G3, while in group B this grading was present only for 38.1%. **Conclusion.** Our observational results suggest

that preoperative platelet count $\geq 300 \text{ mL}^{-1}$ may be associated with poorly differentiated pancreatic adenocarcinomas. These observations may be valuable in the setting of antiplatelet chemotherapeutic agents studies.

Jaundice and Immunity in Pancreatic Cancer Patients: Is There a Relationship?

Nobili C, Degrate L, Franciosi C, Caprotti R, Perego E, Uggeri Fa, Uggeri Fr

Department of Surgery, San Gerardo Hospital, University of 'Milano-Bicocca'. Monza (MI), Italy

Context Several studies have demonstrated that, in cancer patients, jaundice is related to an impaired immune function, particularly affecting T lymphocytes. **Aim** To show if there is a relationship between elevated bilirubin levels and immunity, evaluated by total lymphocytes and lymphocytes subpopulations count, in pancreatic cancer patients. **Methods** Between September 2002 and March 2006, 42 pancreatic adenocarcinoma patients (with different tumor stages and locations) were divided into 2 groups basing on a bilirubin level superior (group A) or inferior (group B) to 5 mg/dL. The amount of total lymphocytes, T (CD3), CD4 and CD8 lymphocytes were determined for both groups. Immune deficiency was defined as a lymphocytes count below the inferior limit of normality ranges provided by our laboratory (total lymphocytes

$< 1,500/\text{mm}^3$, CD3 $< 900/\text{mm}^3$, CD4 $< 500/\text{mm}^3$, CD8 $< 400/\text{mm}^3$). **Results** In group A all the lymphocytes subpopulations considered were lower than those ones in group B, although statistical significance was reached only for total lymphocytes count ($1,428 \pm 640$ vs. $1,876 \pm 591/\text{mm}^3$; $P=0.027$). Our data show a strong relationship between elevated bilirubin levels and CD3 count $< 900/\text{mm}^3$ (OR: 11.25; 95% CI: 1.07-21.43; $P=0.013$), CD4 $< 500/\text{mm}^3$ (OR: 11.25), CD8 $< 400/\text{mm}^3$ (OR: 30.00; 95% CI: 15.2-44.8; $P=0.0002$). **Conclusion** The results of this study show that elevated serum bilirubin levels are related to low levels of lymphocytes subpopulations. This may correlate with an impaired immune function and therefore with a worse prognosis of pancreatic cancer patients.

Use of Fibrin Glue Sealant and Collagen Fleece for the Prevention of Pancreatic Fistula following Distal Pancreatectomy

Ortolano E, Balzano G, Zerbi A, Milani F, Scaltrini F, Di Carlo V

Pancreas Unit, Department of Surgery, S. Raffaele Scientific Institute. Milan, Italy

Context The development of a pancreatic fistula after distal pancreatectomy is still a common occurrence related to post-operative morbidity. **Aim** To evaluate if fibrin glue sealant and collagen fleece has a role in the attempt to decrease the incidence of pancreatic fistula after distal pancreatectomy.

Methods Between March 2005 and May 2006, 21 patients prospectively underwent distal pancreatectomy (with or without splenectomy) and the pancreatic remnant was managed by hand-sewn suture combined with a fibrin glue sealant and collagen fleece (TissueFleece E[®], Baxter). Pancreatic fistulas

were classified according the international study group (ISGPF) definition [1]. Data were compared with the ones collected in our pancreatic surgery database, related to other techniques used in the management of pancreatic management. **Results** The two groups were homogeneous for demographic factors and indication for surgery. In the study group mortality was 0%, morbidity was 49%, and the pancreatic fistula rate was 36.7%; one was B (4.7%) and 7 A fistulas according the above mentioned definition. All fistulas healed spontaneously. Mean daily output at discharge was 26 mL (range 10-100 mL); mean fistula duration was 35 days. In our database (141 patients) that underwent left

pancreatectomy with standard management of pancreatic stump, mortality was 0%, morbidity 48.8%; pancreatic fistula rate 34.1% (B fistulas 21.2%; A fistulas 78.8%); mean fistula daily output 31 mL and mean duration 36 days. **Conclusions** There is no evidence that the use of fibrin glue sealant has a role in prevention of pancreatic fistula, neither affects duration of fistulas itself; whereas it seems to reduce, even not significantly, daily fistula output.

1. Bassi C, Dervenis C, Butturini G, Fingerhut A, Yeo C, Izbicki J, et al. Postoperative pancreatic fistula: an international study group (ISGPF) definition. *Surgery* 2005; 138:8-13. [PMID 16003309]

The Fate of Pancreatic Serous Cystadenomas

Pezzilli R¹, Casadei R², Calculli L³, Santini D⁴, Zanini N², Fantini L¹, Corinaldesi R¹, Minni F²

Departments of ¹Internal Medicine, ²General Surgery, ³Radiology and ⁴Pathology, Sant'Orsola-Malpighi Hospital, University of Bologna. Bologna, Italy

Context Pancreatic serous cystadenomas have a low malignancy rate and they can be clinically managed in asymptomatic patients.

Aim To evaluate the general characteristics, presentation symptoms, diagnostic work-up and therapeutic options of patients with pancreatic cystic cystadenomas followed in our Pancreas Unit. **Methods** All subjects with a diagnosis of cystadenoma were included in this study; all of them underwent a complete imaging and biochemical work-up study at basal time as well as during the follow-up period. **Results** Twenty-four patients were enrolled from January 1990 to January 2006. They were 17 females and seven males (F:M rate: 2.4:1), the mean age at diagnosis was 64.0±14.3 years (mean±SD) (range 30-85 years). The symptoms of presentation were abdominal pain in 11 patients (45.8%), jaundice in six (25.0%), and palpable abdominal mass in two (8.3%); in five patients (20.8%) the presence of serous cystadenoma was an incidental finding. The localization of the tumor was in the head of the pancreas in 11 patients (45.8%), in the

body in six (25.0%), in the body and tail in five (20.8%) and in the tail in two (8.3%). The size of the tumor was of 7.3±5.9 cm (mean±SD) with a range of 1-27 cm. Abdominal ultrasonography was the first imaging technique carried out in all patients, the second was the computed tomography and the third imaging technique was magnetic resonance in seven patients and endoscopic ultrasonography in six. Eighteen patients (75.0%) underwent surgery for their disease: eight patients (44.4%) had a distal pancreatectomy, five (27.8%) enucleation, four (22.2%) pancreaticoduodenectomy, and the remaining one (5.6%) had an intermediate resection. In all operated patients the pathological diagnosis was compatible with cystadenoma. The morbidity was 17.7% (post-operative fistula in two and pseudocyst in one) and mortality was 5.5%. Six patients (25.0%) were not operated. The overall follow-up period was 70.7±67.4 months (mean±SD) (range 6-228 months) and one patient died from an acute myocardial infarction eight month after operation; the

remaining 22 patients are currently alive. In the six patients who were not operated, the median follow-up period was 11.3±12.1 months (mean±SD) (range 6-36 months) and the size of the tumor was unchanged at imaging techniques. **Conclusions** Until the

introduction in routine clinical practice of sophisticated technologies, the current diagnostic work-up does not result in increased preoperative diagnosis of serous-cystic tumors of the pancreas.

Contrast-Enhanced Ultrasound in the Differential Diagnosis between Exocrine and Endocrine Solid Tumors of the Pancreas

Piscitelli L¹, Serra C¹, Tomassetti P¹, Casadei R², Pezzilli R¹, Campana D¹, Mazzotta E¹, Zanini N², Ricci C², Calculli L³, Minni F²

¹Department of Internal Medicine and Gastroenterology, ²Department of Surgery, ³Department of Radiology, University of Bologna, Sant'Orsola-Malpighi Hospital. Bologna, Italy

Context Contrast-enhanced ultrasonography (CEUS) is a new recently introduced imaging technique, able to identify the vascularization of solid tumors in several organs. CEUS can also contribute to the diagnosis of both solid and cystic pancreatic tumors. **Aims** The aim of this study was to evaluate the ability of CEUS to identify the vascularization of solid pancreatic tumors and to differentiate exocrine neoplasms from endocrine tumors. **Methods** Twenty patients (10 males, 10 females, mean age 68 years, range 45-85 years) with solid pancreatic tumors underwent CEUS prior to surgical resection or percutaneous biopsy. The pulse inversion technique (with intravenous injection of 2.4 mL of SonoVue as contrast medium) was used for the CEUS. **Results** The final diagnosis based on histological findings after resection or biopsy, was exocrine pancreatic tumors in 12 patients (nine ductal adenocarcinomas, one cystic adenocarcinoma, one micropapillary cystic mucinous

adenocarcinoma, one microcystic serous cystoadenoma), endocrine pancreatic tumors in eight patients (six nonfunctioning neuroendocrine tumors, one insulinoma and one gastrinoma). All the 12 exocrine pancreatic tumors were hypoechoic at gray scale ultrasonography (US) and hypovascular at CEUS. The eight endocrine tumors were hypoechoic at US in three cases and hyperechoic in four cases. In six cases CEUS showed a hypervascular pattern (only slightly in two patients) while only one endocrine tumor was hypovascular. **Conclusion** CEUS is a promising diagnostic tool for the identification of the vascularization of solid pancreatic tumors. Exocrine and endocrine pancreatic tumors have a different vascularization at CEUS: in fact, one hundred per cent of exocrine tumors are hypovascular, while 86% of the endocrine tumors are hypervascular; these characteristics are useful for their differential diagnosis and may address in evaluating the histological type.

Suspected Tuberculosis of the Pancreas Mimicking Pancreatic Cancer. A Case Report

Polese M¹, Zerbi A¹, Fumagalli L², Balzano G¹, Frasson M¹, Albarello L³, Di Carlo V¹
Pancreas Unit, Departments of ¹Surgery, ²Infectious Disease, and ³Pathology,
S. Raffaele Scientific Institute. Milan, Italy

Case report A 45-year-old Italian female without history of previous illness presented at our Institute with recently developed jaundice, associated with fever, weight loss

and abdominal pain during the last month. The patient underwent ultrasound, CT scan and EUS, showing a 4.5 cm mass in the pancreatic head, not associated with Wirsung

duct dilatation, with suspected portal vein invasion, with peripancreatic, perihepatic, perigastric lymph node involvement. Tumor markers were negative. She underwent surgical intervention because of the malignant suspicion: a 5 cm mass was found in the pancreatic head, adherent to the portal vein without invasion, with an apparent pylorus invasion, associated with extensive lymphadenopathy. A Whipple pancreaticoduodenectomy with lymphadenectomy was performed. Pathological examination of the specimen showed the presence of an extensive necrotizing granulomatous inflammation, with involvement of the wall of the stomach. The peripancreatic lymph nodes also showed epithelioid giant cell granulomas. These findings suggested the diagnosis of suspected pancreatic tuberculosis, even if the acid bacilli stain was negative and in the suspicion of cancer no cultures for mycobacterial infection were done; PCR for

BK is ongoing. In any case we performed enzyme-linked immunospot (ELISPOT) that resulted positive. Also the tuberculin cutaneous test (Mantoux) resulted reactive (10 mm). An antituberculosis therapy was prescribed (isoniazid, rifampin, ethambutol, pyrazinamide). **Discussion** Isolated pancreatic tuberculosis is an extremely rare occurrence in the setting of extrapulmonary tuberculosis, especially in immunocompetent patients. A preoperative diagnosis of pancreatic tuberculosis contraindicates pancreatic resection, but in this case, the absence of extrapancreatic disease, of risk factors and the clinical presentation mimicking pancreatic malignancy, confounded the preoperative diagnosis. **Conclusions** Pancreatic tuberculosis should be considered in the differential diagnosis with pancreatic cancer, even in immunocompetent patients. In these cases a pre-operative biopsy could be helpful to avoid surgery.

Laparoscopic versus Open Distal Pancreatectomy: A Retrospective Case-Control Study

Ricci C, Marrano N, Casadei R, Zanini N, Grottola T, Pagogna S, Antonacci N, Minni F
Department of Surgical and Anesthesiological Sciences, Alma Mater Studiorum - University of Bologna, S.Orsola-Malpighi Hospital. Bologna, Italy

Context Laparoscopic distal pancreatectomy has become an increasingly used technique in the surgical treatment of several pancreatic diseases such as benign or indeterminate cystic neoplasms and neuroendocrine tumours. **Aim** To determine advantage and disadvantage of laparoscopic pancreatectomy. **Methods** Data from 8 consecutive patients who performed laparoscopic distal pancreatectomy with or without splenectomy were entered a prospective database. The 8 laparoscopic patients were compared to a retrospective control group consisting of 8 patients underwent an open distal pancreatectomy matched for age, gender, ASA class, pancreatic pathology and surgical procedure (with or without splenectomy). Operative time, time to adequate oral intake,

pancreatic leak, overall complication rate, length of hospital stay were compared. Data were evaluated using appropriate statistical tests. **Results** The matching was successful for demographic, clinical (ASA class, comorbidities), surgical and pathologic data. The median operative time was 228 min (range 330-165 min) in the laparoscopic group and 140 min (range 90-210 min) in the open group ($P=0.015$). The time to adequate oral intake was 3 days (range 2-5 days) in the laparoscopic group and 4 days (range 3-5 days) in the open group (P NS). The length of hospital stay in the laparoscopic group was 7 days (range 6-10 days), compared with 11 days (range 9-13 days) in the matched controls ($P=0.023$). Two (25%) of 8 laparoscopic patients developed pancreatic

leaks compared with 1 of the 8 (12.5%) matched controls (P NS). Complications occurred in 1 (12.5%) laparoscopic patient (pneumonia) and in 2 (25%) patients of the open group control (pleural effusion) (P NS). **Conclusions** Despite the limitations of this study, laparoscopic distal pancreatectomy yields equivalent surgical results, with shorter

hospitalization than open pancreatectomy. Pancreatic leak rate and overall complication rate appear similar. Laparoscopic pancreatectomy is associated to longer operative time than open pancreatectomy; anyway it is possible to obtain a reduction of operative time with advancing in learning curve.

Does Prophylactic Pancreatic Stent Placement Reduce the Risk of Post-ERCP Acute Pancreatitis? Personal Experience

Sciumè C, Geraci G, Pisello F, Facella T, Tinaglia D, Modica G

Section of 'Chirurgia Generale ad Indirizzo Toracico', AOUP 'Paolo Giaccone' Hospital.
Palermo, Italy

Context Impaired drainage of pancreatic juice after ERCP is the most important cause of acute pancreatitis after ERCP. To reduce the incidence of acute pancreatitis ERCP-related, we performed the temporary stenting of Wirsung in high risk patients (SOD, difficult cannulation, reiterate Wirsung cannulation). **Materials and methods** In the Service of Digestive Endoscopy of Section of General and Thoracic Surgery in Policlinico University of Palermo, from 2003 to 2006, 97 patients (14.1% of all 686 ERCPs performed) were randomized into one group with pre-cut papillotomy 'free-hand' (Group A, 56 patients) and a second group with pre-cut papillotomy with pancreatic stent (Group B, 41 patients). The results were prospectively reviewed. Stents were adapted on morphology and dimension of Wirsung, according to

length, diameter, flaps and pigtail. Stents were removed after 7-10 days. **Results** Incidence variability of acute pancreatitis post-ERCP in literature (1-40%) depends on definition of acute pancreatitis post-ERCP, on patients-related and procedure-related factors, that may be also synergistic. In our study, the difference between incidence of acute pancreatitis post-ERCP in the group with 'free-hand' pre-cut (17.8%) and pre-cut with stent (2.5%) was statistically significant (P<0.05). **Conclusions** From our experience, temporary and prophylactic pancreatic stent is able to reduce incidence of acute pancreatitis post-ERCP after pancreatic sphincterotomy, before the pre-cut, during difficult biliary cannulation and reiterate Wirsung cannulation and after sphincterotomy in SOD.

Isolation and Characterization of Mesenchymal Stem Cells from Pancreas to Be Used for Cotransplantation with Islets

Sordi V¹, Formicola R¹, Mercalli A¹, Melzi R¹, Balzano G², Zerbi A², Di Carlo V², Piemonti L¹

¹JDRF Telethon Center for Beta Cell Replacement, and ² Department of Surgery, S. Raffaele Scientific Institute. Milan, Italy

Context Mesenchymal stem cells (MSC) could represent a renewable source of cells that facilitate beta cell expansion or

regeneration either indirectly by promoting beta cell replication/survival or directly by differentiation into beta cells. Moreover MSC

were shown to play a role in immunomodulation. **Aim** The objective of the study is to isolate and characterize mesenchymal stem cells from pancreas to be used for cotransplantation with islets. **Methods** The discard material of both human and mouse pancreas digestion after islet isolation was used to isolate pancreatic mesenchymal stem cells. Pancreatic mesenchymal stem cells were characterized in terms of phenotype, differentiation, angiogenic factors release, expression of genes involved in pancreas development (Pdx1, Hnf6, Ptf1a, Ngn3, Pax6, Pax4, NeuroD, Nkx2.2, Nkx6.1, Krt19, insulin, GAD). **Results** Highly enriched primary cultures of pancreatic mesenchymal stem cells were obtained after seven days culture in appropriate conditions both from human (hPMSC: CD117^{+/+}, CD73⁺, CD105⁺, CD133^{+/+}, CD166⁺ and CD34⁻, CD45⁻, CD31⁻) and mouse pancreas (mPMSC: Sca-1⁺, CD90.2⁺, CD117^{+/+}, CD44⁺ and CD45⁻, CD31⁻, CD34⁻). Quantitatively, starting from 100 microliters of human digested tissue we were able to obtain after seven days 5x10⁵ PMSC (about 10⁸ PMSC from one digested pancreas). Both hPMSC and mPMSC grew in

culture, maintained MSC characteristics after several passages (up to 13), after cloning and after freezing and thawing. hPMSC and mPMSC were also able to differentiate in adipocytes and osteoblasts under appropriate stimuli. In basal conditions, by real-time PCR analysis, hPMSC did not express genes involved in pancreas development with the exception of low level of Isl1, differentiating from bone marrow MSC which were positive for Pdx1, insulin, Nkx2.2, Nkx6.1, Pax6 and Isl1. Finally hPMSC secreted pro-angiogenic factors like Angiopoietin-2, PDGF, VEGF, EGF, IL8 but not FGF. **Conclusions** This study characterizes a population of mesenchymal stem cells derived from pancreas which can be a source of cells to be employed to promote islet survival and function. Experiments of cotransplantation with islets in mouse models are ongoing. Finally, we are testing the possibility that pancreatic mesenchymal stem cell can be the cell responsible for the intense stromal reaction which characterizes pancreatic cancer. (Supported by EFSD/JDRF/Novo Nordisk Type 1 Diabetes Research Programme 2005)

Pancreatic Remnant Treatment after Pancreaticoduodenectomy: Pancreaticojejunostomy in a Separate Jejunal Loop

Zanini N, Casadei R, Ricci C, Minni F

First Surgical Clinic, Alma Mater Studiorum - University of Bologna, S.Orsola-Malpighi Hospital.
Bologna, Italy

Context A pancreatic fistula, resulting from pancreatic remnant treatment, can be the source of considerable morbidity and can contribute to mortality after pancreaticoduodenectomy (PD) for malignant or benign pancreatic diseases. **Aim** To evaluate the hypothesis that pancreaticojejunostomy in a separate jejunal loop is safer than pancreatic remnant occlusion and suture or pancreaticojejunostomy in a single jejunal loop. **Methods** From January to May 2006, data from 15 consecutive patients who had

PD with pancreaticojejunostomy in a separate jejunal loop, were entered into a prospective database (group 1). These patients were compared, regarding postoperative mortality and morbidity, length of hospital stay, operative time, blood loss and blood transfusion, to other two groups in which the treatment of the pancreatic remnant was: suture previous injection of a sclerosing substance in the Wirsung duct (group 2); pancreaticojejunostomy in the same jejunal loop of the biliary and gastric anastomosis

(group 3). **Results** Group 1: 9 male, 6 female, median age 63 years (range 50-79 years), 7 pancreatic cancer, 4 ampullary cancer, 2 cystic pancreatic tumors, 1 neuroendocrine tumor and 1 chronic pancreatitis. 3 PD with distal gastrectomy, 12 pylorus-preserving PD. Mean operative time 301 min (range 240-510 min), blood loss 850 mL (range 500-1,500 mL), blood replacement in 5 patients. Length of hospital stay: 15 days (range 10-28 days). No postoperative death and 2 pancreatic fistulas. Group 2: 8 male, 7 female, median age 66 years (range 52-88 years), 10 pancreatic cancer, 2 ampullary cancer, 2 neuroendocrine tumor and 1 chronic pancreatitis. 3 PD with distal gastrectomy, 12 pylorus-preserving PD. Mean operative time 338 min (range 230-595 min), blood loss 800 mL (range 300-1,300 mL), blood replacement

in 7 patients. Length of hospital stay: 19 days (range 10-55 days). Two postoperative death and 6 pancreatic fistulas. Group 3: 8 male, 7 female, median age 59 years (range 49-72 years), 6 pancreatic cancer, 5 ampullary cancer, 2 neuroendocrine tumor and 2 chronic pancreatitis. 2 PD with distal gastrectomy, 13 pylorus-preserving PD. Mean operative time 345 min (range 255-500 min), blood loss 800 mL (range 400-1,500 mL), blood replacement in 6 patients. Length of hospital stay: 21 days (range 13-31 days). One postoperative death and 5 pancreatic fistulas. **Conclusions** Pancreaticojejunostomy in a separate jejunal loop after PD is simple and safe. Operative time, blood loss, blood replacement and length of hospital stay are not increased. Finally it could reduce the incidence of pancreatic fistulas.

Co-Morbidities and Pancreatic Stump Treatment after Pancreaticoduodenectomy: Are They Linked to Postoperative Morbidity?

Zanini N¹, Casadei R¹, Pezzilli R², Calculli L³, Ricci C¹, Grottola T¹, Pagogna S¹, Antonacci F¹, Minni F¹

Departments of ¹Surgical and Anesthesiological Sciences, ²Internal Medicine, ³Radiological and Histocytopathological Sciences, Alma Mater Studiorum - University of Bologna, S.Orsola-Malpighi Hospital. Bologna, Italy

Context Pancreaticoduodenectomy has become a safe and a appropriate operation in which mortality rate is less than 5% in experienced centre. The incidence of postoperative morbidity is still high. **Aim** Is it possible to predict post-operative morbidity and mortality before take the patient to the operation theatre? Is morbidity linked to the technique to manage the pancreatic stump? Is there still a role for the suture of the pancreatic stump instead of pancreaticojejunostomy? **Methods** We retrospectively reviewed data of 110 consecutives patients who underwent pancreaticoduodenectomy (PD) in our Institute since 1990. Post-operative mortality and morbidity were evaluated according to some prognostic factors (age, ASA score, hypertension, congestive heart failure,

coronary artery disease, cerebrovascular disease, diabetes mellitus, COPD) and to pancreatic stump treatment after PD (suture vs. pancreaticojejunostomy). Data were evaluated using the Fisher's exact test. **Results** There was no significance different in morbidity and mortality for each prognostic factor analyzed. There was a significant difference (P=0.007) in post-operative morbidity between patients in whom a pancreaticojejunostomy was performed (53 patients, morbidity: 28.3%) and those ones in whom the pancreatic stump was sutured (57 patients, morbidity: 54.4%). **Conclusions** If an accurate selection of patients is done, morbidity and mortality are not linked to co-morbidities. Pancreaticojejunostomy is safer than stump closure in order to reduce morbidity.