

## Post Traumatic Cerebral Infarction: A Case Report and Review of the Literature

Rupesh Raut, Sushil Rijal, Shahzad Shams, Ammar Bin Ahsan, Muddassar Rasheed, Azam Niaz, Waqas Mehdi, Farah Javaid and Asim Andrabi

King Edward Medical University, Pakistan

### Abstract

Post Traumatic Cerebral Infarction (PTCI) is one of the rare but severe forms of secondary brain injury with a very high rate of morbidity and mortality. There is a paucity of literature on PTCI in pediatric patients and there is a lack of proper guidelines to investigate and treat this condition. Patients when present with focal neurological deficits only may recover within weeks to months with anticoagulants. We report a case of an eleven months old baby girl who sustained a mild traumatic brain injury due to a fall from the height. She developed right-sided hemiplegia on her third post-admission day and fresh Computed Tomography (CT) of the head revealed a new infarct in the territory of the left Middle Cerebral Artery (MCA). Anticoagulant was started and she had a gradual but complete recovery over the next several days.

**Care Report:** An eleven months old baby girl born of nonconsanguineous marriage with normal developmental history and no known medical problems was brought to our accident and emergency room with a history of fall from a height of one foot. She had a history of crying for a brief period, vomited once, but there was no loss of consciousness or convulsions. Upon examination, her Glasgow Coma Scale (GCS) was 14/15, pupils were bilaterally equal and reactive, moving all four limbs but was irritable and crying frequently. She was admitted and managed medically. A non-enhanced CT scan of the brain was obtained, which showed left parietal linear fracture and underlying contusion (Figure 1 A, B). He was admitted and non-surgical management was started. On the third post-admission day, she developed complete paralysis in the right half of the body with right-sided Upper Motor Neuron (UMN) type of facial palsy and a positive Babinski sign. She had no signs of raised intracranial pressure or meningeal irritation. There was no past medical history of any form of infection and no family history of thromboembolic disorders. A non-enhanced CT scan of the brain was repeated which now revealed infarction in the left Middle Cerebral Artery (MCA) territory (Figure 2A, B). The patient was not able to afford relevant investigations like protein C and S, antithrombin III, and antiphospholipid antibody. Medical management was continued and Low molecular heparin was started subcutaneously which led to her limb power improvement

within the next four days. Her GCS improved as well to 15/15 by this time. The anticoagulant was stopped, the patient was discharged. On her first follow up (11th post-trauma day), her right-sided weakness and facial weakness had completely recovered.

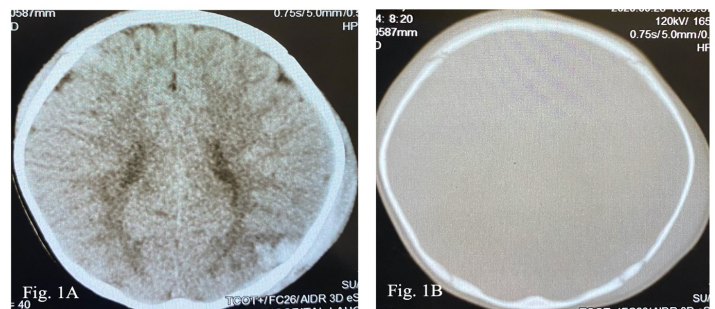


Figure 1A) Computerized tomography (CT), axial section showing a contusion over the left parietal area and subgaleal hematoma. B) Axial section at the same level showing a linear fracture of the parietal bone.

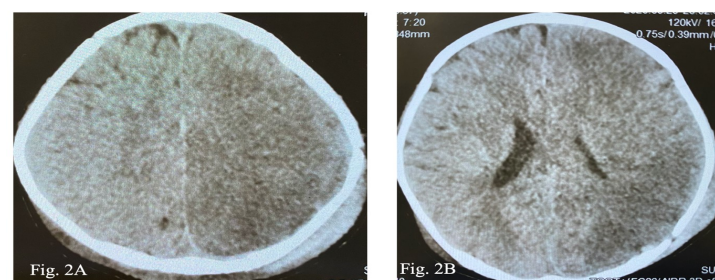


Figure 2 A and B) Computerized tomography (CT), axial section showing an infarction in the Middle Cerebral Artery territory on the third day.

**Discussions:** Post Traumatic Cerebral Infarctions (PTCI) is one of the most severe forms of secondary brain injuries following Traumatic Brain Injury (TBI). It is associated with severe morbidity and mortality ranging from 1.9% to 10.4%.<sup>1</sup> It is an exceedingly rare sequela observed in the pediatric population

after TBI, the pathology of which is believed to be vascular injury or any clotting disorders. Hemiplegia is the most common focal neurological deficits observed, occurring in up to 94% of the cases of acute ischemic strokes after minor head trauma. The arterial territories affected are the territory of Posterior Cerebral Artery (PCA), the most common, Middle Cerebral Artery (MCA), Lenticulostriate Arteries, and Anterior Cerebral Artery (ACA). Cerebral infarction in the MCA territory is generally termed as malignant PTCI due to its nature of severity and impending cerebral herniation. Though the exact pathology is not well understood, various mechanisms have been suspected, including cerebral vasospasm, direct vascular injury and subsequent thrombosis, embolization, and systemic hypoperfusion. Gross mass effect and herniation can produce additional stretching and attenuation of small perforating arteries, such as lenticulostriate and thalamoperforators. Intracranial arterial vasospasm in association with T-SAH leading to hypoperfusion is another proposed mechanism of PTCI.

Patients present with mild head trauma signs and symptoms like loss of consciousness, post-traumatic amnesia, headache, nausea, or vomiting. Among those who deteriorate, most develop neurological signs and symptoms within 72 hours which includes hemiparesis, facial paresis, and convulsions. Therefore, patients should undergo hourly monitoring of vitals, GCS, and status of the pupil to monitor any impending signs of deterioration. The radiological diagnosis is made with a non-enhanced CT Scan of the brain based on a well-demarcated region of low attenuation following specific vascular territory with normal initial CT Scan.

The overall death rate among patients with PTCI is as high as 43.8%.<sup>6</sup> Pediatric patients who sustained focal neurological deficits tend to improve (specially hemiparesis) within several months.<sup>8</sup> Usually, mild pediatric stroke cases will have a good prognosis and complete recovery by proper management. Aggressive management is required in patients with refractory elevated ICP and huge infarctions including surgical procedures, anticoagulants, and calcium channel blockers.<sup>1</sup> Use of anticoagulant therapy alone have shown a good clinical recovery in patients with less severe forms of infarctions. For patients with malignant cerebral edema due to MCA infarct, decompressive hemicraniectomy has been shown to improve survival rates and functional outcomes.

Conclusion: PTCI is one of the severe complications after TBI with high morbidity and mortality. Recognizing PTCI early in the course is challenging and thus requires close monitoring of patients for any fall in consciousness level and focal neurological deficits. Risk factors include intracranial injuries

and hemocoagulative disorders. Early recognition and prompt intervention might be beneficial to prevent PTCI after TBI.

#### *Biography:*

Rupesh Raut, MD is the Chief Resident in Department of Neurosurgery, King Edward Medical University, Mayo Hospital, Lahore Pakistan. He has published multiple valuable papers in various national and international journals. He has also authored several chapters in various international neurosurgery books.

[6<sup>th</sup> World Congress on Pediatric Disease, Care & Management](#); November 23-24, 2020.

#### Abstract Citation:

Rupesh Raut, Post Traumatic Cerebral Infarction: A Case Report and Review of the Literature, Pediatric Disease 2020, 6<sup>th</sup> International World Congress on Pediatric Disease, Care & Management ; November 23-24, 2020.