

## CASE REPORT

---

# Pancreatic Pseudocyst Causing Celiac Artery Trunk Thrombosis

Christopher Challand<sup>1</sup>, Daniel Titcomb<sup>2</sup>, Christopher P Armstrong<sup>2</sup>

<sup>1</sup>Gastroenterology Directorate, Derriford Hospital, Plymouth Hospitals NHS Trust. Plymouth, United Kingdom. <sup>2</sup>Department of Surgery, Frenchay Hospital, North Bristol NHS Trust. Bristol, United Kingdom

### ABSTRACT

**Context** Vascular complications of pancreatitis are more common in alcohol- rather than gallstone-induced pancreatitis. Such complications are an important cause of mortality and morbidity, although peripancreatic vessel obstruction is a rare consequence. Patients with peripancreatic arterial obstruction can present with sudden and unexplained clinical deterioration requiring prompt diagnosis and intervention.

**Case report** A 42-year-old woman with a proven pancreatic pseudocyst presented with acute abdominal pain. Initial investigations were non-diagnostic. A gastroscopy revealed patchy necrosis of the proximal stomach. Following sudden clinical deterioration, a contrast-enhanced CT scan was performed. The CT scan demonstrated a thickened gastric wall with intramural gas. The decision was taken to proceed to laparotomy, which revealed both gastric and splenic infarction. A total gastrectomy with Roux-en-Y reconstruction and splenectomy was performed. She made a successful recovery.

**Conclusion** Arterial thrombosis should be considered in any patient with chronic pancreatitis who presents with an acute clinical deterioration. Successful outcomes can be achieved with prompt diagnosis using contrast-enhanced CT scanning and early surgical intervention.

### INTRODUCTION

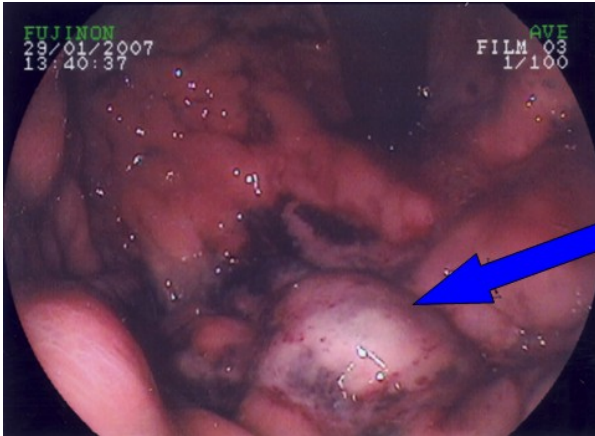
Vascular complications of pancreatitis are a well-recognised cause of morbidity and mortality being more frequently observed in alcohol-induced rather than gallstone pancreatitis [1]. Portal vein thrombosis, haemorrhage from arterial erosion or rupture of pseudoaneurysms, visceral ischaemia and haemorrhage into pseudocysts have been described [2].

Arterial thrombosis has been reported affecting various important major vessels in close proximity to the pancreas [3, 4, 5, 6, 7]. Peripancreatic arterial occlusions may lead to infarction and necrosis of the organs supplied by them. A single case of celiac artery trunk thrombosis has been previously reported as a consequence of acute pancreatitis following pancreatic necrosectomy requiring total gastrectomy [4].

We report a case of celiac artery trunk thrombosis causing gastric and splenic infarction in a patient with alcohol-induced chronic pancreatitis with an associated pseudocyst, where alimentary continuity was established at the primary operation.

### CASE REPORT

A 42-year-old active alcoholic woman with a ten-year history of alcohol-induced chronic pancreatitis and proven pancreatic pseudocyst (recent CT scan within six months) was admitted with acute abdominal pain. Examination revealed localized left upper



**Figure 1.** Gastroscopy demonstrating patchy necrosis of the proximal stomach (arrowed) with associated mucosal ulceration.

quadrant tenderness. She was afebrile and haemodynamically-stable. Plain radiographs were non-diagnostic. Initial laboratory investigations, including liver function tests, demonstrated a normal white cell count of  $10.3 \times 10^9/L$  (reference range: 3.5 to  $10.5 \times 10^9/L$ ) with an elevated lipase of 78 U/L (reference range: 22 to 51 U/L), but were otherwise unremarkable. Arterial blood gases revealed a compensated metabolic acidosis: pH 7.43 (reference range: 7.35 to 7.45),  $\text{PaCO}_2$  3.0 kPa (reference range: 4.7 to 6.0 kPa),  $\text{HCO}_3^-$  14.9 mmol/L (reference range: 22 to 26 mmol/L), base excess -7.5 mmol/L (reference range: -2 to +2 mmol/L), and lactate 3.9 mmol/L (reference range: 0.5 to 2.0 mmol/L).

The following day, a gastroscopy was arranged and showed patchy necrosis of the proximal stomach (Figure 1). Subsequently, she became tachycardic (heart rate 115 beats/minute) with localised peritonism in the left upper quadrant and a leucocytosis of  $15.4 \times 10^9/L$  and elevated C-reactive protein of 302 mg/L (reference range: 0 to 7.5 mg/L). An urgent CT scan was performed and revealed a 10 cm pancreatic pseudocyst in the lesser sac and a thickened gastric wall containing intramural gas particularly affecting the fundus without evidence of perforation (Figure 2).

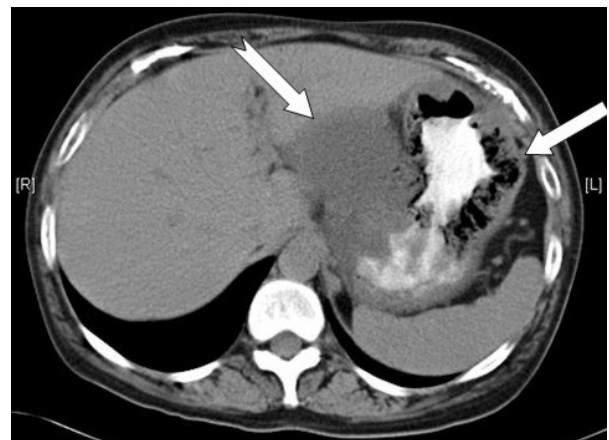Decision was taken to proceed to laparotomy, which revealed an oedematous, and ischaemic stomach. Thrombosed vessels were adherent

to both the left lobe of the liver and the pancreatic pseudocyst. Splenic infarction was noted. Visible thrombosis was seen upon vessel transection. Total gastrectomy with Roux-en-Y reconstruction and splenectomy was performed with concurrent external drainage of pancreatic pseudocyst, adhesiolysis and insertion of a feeding jejunostomy. Histology confirmed full thickness mucosal gastric infarction with pyloric sparing and extensive splenic infarction.

Feeding was commenced day 1 post-operatively via the jejunostomy. A water-soluble contrast swallow was performed on day 5 which demonstrated no anastomotic leak and oral fluids were commenced. She made a slow post-operative recovery and was discharged without further complication.

## DISCUSSION

Arterial complications of pancreatitis usually present as haemorrhage into the abdominal cavity or gastrointestinal tract due to vascular erosion or pseudoaneurysm rupture, although cases of arterial thrombosis, and subsequent occlusion, are well-documented [1, 2, 3, 4]. Patients with peripancreatic arterial obstruction as a consequence of pancreatitis can present with sudden and unexplained clinical deterioration and hence prompt diagnosis and timely surgical intervention is required.



**Figure 2.** A contrast-enhanced CT scan demonstrating thickened gastric wall containing intra-mural gas (straight arrow) with associated pancreatic pseudocyst (notched arrow).

Previous studies concluded that vascular complications are significantly more common in alcohol rather than gallstone-induced pancreatitis [1], and the incidence of vascular complications are three times higher in chronic pancreatitis [3]. The pathophysiology of vascular complications in pancreatitis is not fully understood. In acute pancreatitis, both microvascular changes induced by pancreatic ischaemia-reperfusion injury, and macrovascular mechanisms due to exposure of vessels to inflammatory mediators and proteolytic enzymes, may have important roles in the development of arterial thrombosis [2, 4]. The sequence of events in chronic pancreatitis is less well known. Further microcirculatory disturbance may occur due to acinar cell dysfunction with associated activation of digestive enzymes [8], or episodes of recurrent pancreatitis may cause a similar mechanism to that described in acute pancreatitis [2]. It is possible that pseudocysts cause a direct pressure effect on surrounding vasculature leading to arterial occlusion. However, this is unproven. The consequences of celiac artery trunk thrombosis are variable. Perigastric arterial thrombosis leads to gastric infarction requiring urgent surgical intervention. Splenic infarction can be managed conservatively [5]. Dual blood supply and superior collateral flow ensures that the liver is resilient to the effects of thrombosis [4]. A Roux-en-Y reconstruction allowed immediate restoration of alimentary continuity. Such procedures may be less advisable in the presence of gastric perforation and sepsis.

## CONCLUSION

The possibility of arterial thrombosis should be considered in any patient with chronic pancreatitis who presents with an acute clinical deterioration. Prompt diagnosis with contrast-enhanced CT scanning allowed successful and early operative management of a potentially life-threatening event. Patients with alcohol-induced chronic pancreatitis are more susceptible to developing vascular complications and may warrant specific screening allowing early detection.

---

Received February 4<sup>th</sup>, 2008 - Accepted May 12<sup>th</sup>, 2008

**Keywords** Celiac Artery; Pancreatic Pseudocyst; Thrombosis

**Conflict of interest** The authors have no potential conflicts of interest

## Correspondence

Christopher Challand  
Gastroenterology Directorate  
Derriford Hospital, Plymouth Hospitals NHS Trust  
Plymouth, PL6 8DH  
United Kingdom  
Phone: +44-1752.517.911  
Fax: +44-1752.768.976  
E-mail: chrischalland@hotmail.com

Document URL: <http://www.joplink.net/prev/200807/14.html>

---

## References

1. Dörffel T, Wruck T, Rückert RI, Romaniuk P, Dörffel Q, Wermke W. Vascular complications in acute pancreatitis assessed by colour duplex ultrasonography. *Pancreas* 2000; 21:126-33. [PMID 10975705]
  2. Mendelson RM, Anderson J, Marshall M, Ramsay D. Vascular complications of pancreatitis. *ANZ J Surg* 2005; 75:1073-9. [PMID 16398814]
  3. Nordback I, Sisto T. Peripancreatic vascular occlusions as a complication of pancreatitis. *Int Surg* 1989; 74:36-9. [PMID 2707996]
  4. Kumaran C, Chung AF, Ooi LP, Chow PH, Wong WK. Coeliac artery trunk thrombosis in acute pancreatitis causing total gastric necrosis. *ANZ J Surg* 2006; 76:273-4. [PMID 16681549]
  5. Rice PF, Khan MS, Mackle EJ. Total splenic infarction in acute pancreatitis. *J R Coll Surg Edinb* 1996; 41:54-5. [PMID 8930045]
  6. Scholefield JH, Goodman AJ, Morgan WP. Abdominal wall and gastric infarction in acute pancreatitis. *Pancreas* 1988; 3:494-6. [PMID 2971970]
  7. Kukora JS. Extensive colonic necrosis complicating acute pancreatitis. *Surgery* 1985; 97:290-3. [PMID 3975849]
  8. Freedman SD. New concepts in understanding the pathophysiology of chronic pancreatitis. *Int J Pancreatol* 1998; 24:1-8. [PMID 9746883]
-