

CASE REPORT

Pancreatic Mucinous Cyst Adenocarcinoma Producing CA 19-9. A Case Report

Sumiya Ishigami, Kenji Baba, Yuko Mataka, Hidetoshi Noma, Kosei Maemura,
Hiroyuki Shinchi, Sonshin Takao, Shoji Natsugoe, Takashi Aikou

Gastrointestinal Surgery, Surgical Oncology, Kagoshima University School of Medicine.
Kagoshima, Japan

ABSTRACT

Context We herein present a rare case of a mucinous cystic neoplasm of the pancreas producing CA 19-9 and the clinical implications are discussed.

Case report A 35-year-old woman with no history of abdominal surgery presented at Saisei Kai Sendai Hospital with an upper abdominal distention. Abdominal CT showed a large lobulated cystic tumor at the pancreatic tail. No distant metastases were identified. The preoperative serum CA 19-9 level was 6,200 U/mL (reference range: 0-37 U/mL). A mucinous cystic neoplasm of the pancreas was diagnosed and elective surgery was performed. On laparotomy, a round tumor 15 cm in diameter was encountered in the upper left abdomen. No invasion of neighboring organs or the portal vein was apparent. The entire tumor was curatively resected with a distal pancreatectomy. The final histopathological analysis revealed mucinous cystadenocarcinoma with no invasive component. Immunohistochemical staining disclosed CA 19-9 expression within the tumor cells. The CA 19-9 level normalized rapidly postoperatively and, although a minor pancreatic fistula occurred, this was resolved conservatively. She was discharged on the 45th postoperative day with no sign of tumor relapse; her CA 19-9 level was within the normal range 20 months postoperatively.

Conclusion We present this rare case of a mucinous cystic neoplasm producing CA 19-9 and discuss the relevant literature. The CA 19-9 production in this tumor does not appear to be directly correlated to aggressive clinical behavior.

INTRODUCTION

Mucinous cyst adenocarcinoma of the pancreas is a rare neoplastic disease. The tumor can be classified as a mucinous cystic neoplasm, a group which accounts for less than 1% of all malignant tumors of the pancreas [1]. Mucinous cystic neoplasms tend to be slow growing and frequently reach a considerable size before becoming symptomatic. In treating this class of tumor, differentiation between a pseudocyst and a neoplasm is clinically important; preoperative diagnostic tools such as computed tomography and magnetic resonance imaging (MRI) are very useful in reaching the correct diagnosis. Once a mucinous cystic neoplasm is diagnosed, extirpation is undertaken principally because of the tumor's malignant potential. Carbohydrate antigen (CA) 19-9 is identified in the normal pancreatic duct, bile duct, stomach, colon, and prostate. Although more than 90% of pancreatic ductal carcinomas are positive for CA 19-9 [2], little clinical information exists regarding CA 19-9

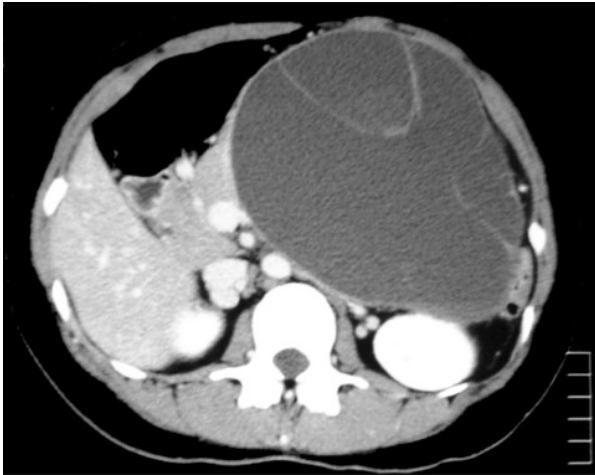


Figure 1. An abdominal CT showing a large (15 cm diameter) cystic tumor of the pancreatic cyst consistent with mucinous cyst adenocarcinoma.

expression in mucinous cystic neoplasms. We herein present a case of mucinous cyst adenocarcinoma of the pancreas producing CA 19-9 and the clinical implications of CA 19-9 positivity in mucinous cystic neoplasms are discussed.

CASE REPORT

A 35-year-old woman presented at Saisei Kai Sendai Hospital complaining of upper abdominal distention. An abdominal CT showed a large multilobular cystic tumor with a fluid component at the pancreatic tail (Figure 1). No apparent distant lesion was evident. The cystic tumor was hypointense on

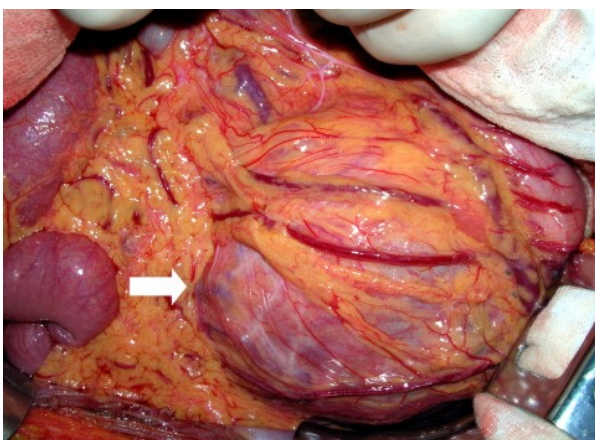


Figure 2. Intraoperative abdominal findings. A round cystic tumor, 15 cm in diameter, was identified in the upper left abdomen.

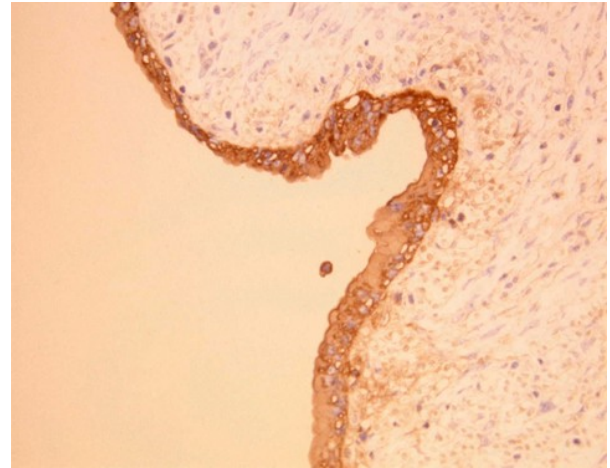


Figure 3. Immunohistochemical staining for CA 19-9. CA 19-9 positivity was homogenously identified in the tumor cells.

T2-weighted MRI, suggesting that the cyst content was mucinous fluid. Preoperatively, the serum CA 19-9 level was 6,200 U/mL (reference range: 0-37 U/mL). A distal pancreatectomy with lymph node dissection was planned electively. On laparotomy, a round tumor measuring 15 cm in diameter was encountered in the upper left abdomen (Figure 2). The entire tumor was resected with a distal pancreatectomy. Since an intraoperative histopathological analysis suggested adenoma, lymph node dissection was not performed. Tumor invasion of the portal vein, superior mesenteric artery and portal system was suspected preoperatively; however, all these structures could be dissected easily. The serum CA 19-9 level normalized early in the postoperative course. The final histopathological report confirmed that the pancreatic tumor had a large adenomatous component, associated with a non-invasive mucinous cyst adenocarcinoma. Immunohistochemical staining with CA 19-9 revealed the tumor cells to be diffusely positive for CA 19-9 (Figure 3). The CA 19-9 level in the cystic fluid was up to 60,000 U/mL. Although a minor pancreatic fistula occurred postoperatively, this was resolved conservatively. She was discharged on the 45th postoperative day with no sign of tumor relapse; her CA 19-9 level was within the normal range and continued to be so 30 months postoperatively.

DISCUSSION

A mucinous cystic neoplasm is a rare neoplastic disorder primarily affecting middle-aged women, with lesions occurring predominantly in the body and tail of the pancreas, in accordance with the clinical and demographic features seen in the present case. Eloubeidi and Hawes have reported that the 5-year survival rate was almost 100% in non-invasive mucinous cystic neoplasms treated surgically [1]. However, they suggested that mucinous cystic neoplasms should be regarded as a malignant or premalignant condition, and recommended surgical resection. Once curative surgery is performed, the surgical outcome of a mucinous cystic neoplasm is far better than that of a pancreatic ductal carcinoma. However, due to its rarity, the malignant potential of mucinous cystic neoplasm has not been adequately evaluated. More than 70% of pancreatic ductal cancers exhibit CA 19-9 positivity, which is therefore useful in the detection and diagnosis of pancreatic neoplasms [2]. The elevation of serum CA 19-9 is also often found in pancreatic non-cancerous disease [3], Cwik *et al.* analyzed the serum level of CA 19-9 in 110 patients with pancreatic mass lesions [4], and four out of 37 benign pancreatic tumor patients were CA 19-9 positive. The ratio of CA 19-9 in these cases was less than 500 U/mL. In this context, the current case showed more than 6,000 U/mL of CA 19-9. We immunohistochemically confirmed that the tumor cells expressed CA 19-9, and reflected the high levels of CA 19-9 in the cystic fluid (60,000 U/mL). The mechanism of the serum elevation of CA 19-9 is believed to occur because the CA 19-9 flowed into the bloodstream as a result of the elevation of the inner pressure of the giant cyst. Since little little information exists on the relationship between the CA 19-9 level and the malignant potential of mucinous cystic neoplasms, the clinical implications of CA 19-9 positivity were equivocal in the mucinous cystic neoplasm. Sperti *et al.* documented that CA 19-9 was positive in the cystic fluid of three of seven mucinous cystic neoplasm patients,

and that this indicated malignant potential [5]. On the basis of this finding, they suggested that CA 19-9 elevation not only in the serum but also in the cystic fluid was useful in differentiating between a pseudocyst and a mucinous cystic neoplasm. On the other hand, Yasue *et al.* reported that, unlike what has been found in gastric and colon cancer, CA 19-9 positivity did not affect survival in pancreatic ductal cancer [6], suggesting that that CA 19-9 expression does not directly reflect the malignant behavior of the tumor. In conclusion, extremely elevated levels of CA 19-9 may reflect the presence of a CA 19-9-producing tumor but not necessarily the malignant potential of a mucinous cystic neoplasm. When the tumor cells have a strong CA 19-9 positivity as in the current report, a postoperative follow-up of serum CA 19-9 levels may be useful in detecting a recurrence of this disease.

Received December 18th, 2006 - Accepted January 29th, 2007

Keywords CA-19-9 Antigen; Cystadenoma, Mucinous

Correspondence

Sumiya Ishigami
8-35-1 Sakuragaoka
Kagoshima 890-8520
Japan
Phone: +81-99.275.5361
Fax: +81-99.265.7426
E-mail: ishiga@m.kufm.kagoshima-u.ac.jp

Document URL: <http://www.joplink.net/prev/200703/12.html>

References

1. Eloubeidi MA, Hawes RH. Mucinous tumors of the exocrine pancreas. *Cancer Control* 2000; 7:445-51. [PMID 11000614]
2. Satake K, Kanazawa G, Kho I, Chung Y, Umeyama K. Evaluation of serum pancreatic enzymes, carbohydrate antigen 19-9, and carcinoembryonic antigen in various pancreatic diseases. *Am J Gastroenterol* 1985; 80:630-6. [PMID 2411125]
3. Tsuchiya Y, Suzuki S, Sakaguchi T, Kojima Y, Okamoto K, Kurachi K, et al. Lymphoepithelial cyst of

the pancreas: report of a case. *Surg Today* 2000; 30:856-60. [PMID 11039720]

4. Cwik G, Wallner G, Skoczylas T, Ciechanski A, Zinkiewicz K. Cancer antigens 19-9 and 125 in the differential diagnosis of pancreatic mass lesions. *Arch Surg* 2006; 141(10):968-73. [PMID 17043274]

5. Sperti C, Pasquali C, Perasole A, Liessi G, Pedrazzoli S. Macrocystic serous cystadenoma of the

pancreas: clinicopathologic features in seven cases. *Int J Pancreatol* 2000; 28:1-7. [PMID 11185705]

6. Yasue M, Sakamoto J, Teramukai S, Morimoto T, Yasui K, Kuno N, et al. Prognostic values of preoperative and postoperative CEA and CA19.9 levels in pancreatic cancer. *Pancreas* 1994; 9:735-40. [PMID 7846017]
